

# A painful neck in a young well looking man presenting to A&E

C Izzi-Engbeaya<sup>1</sup>, S Zac-Varghese<sup>1</sup>, F Palazzo<sup>2</sup>, K Meeran<sup>1</sup>, W Dhillon<sup>1</sup>

<sup>1</sup>Department of Endocrinology, <sup>2</sup>Department of Endocrine Surgery, Imperial College Healthcare NHS Trust

A 38-year-old man presented on the acute medical take with a week's history of sore throat, dysphagia, neck swelling, and fever. One month prior he had suffered a respiratory tract infection, which resolved without antibiotics. He had no notable past medical and family history. He was a non-smoker and drank 15 units of alcohol per week. On examination he was afebrile, sweaty and flushed; chest was clear, heart sounds were normal, regular pulse (110bpm) and BP 148/88mmHg. His anterior neck was erythematous, his right thyroid lobe was smoothly enlarged with no bruits heard over his thyroid. There was no palpable cervical lymphadenopathy and no evidence of tonsillitis. An initial clinical diagnosis of de Quervain's thyroiditis was made. Blood tests revealed WCC 20, CRP 515 and normal thyroid function. Due to the neck erythema and high CRP an ultrasound was requested.

Ultrasound revealed a very large complex pus collection extending to the right sternocleidomastoid muscle. Samples were obtained but percutaneous drainage was not possible. CT scan was performed (Figure 1), which confirmed the ultrasound findings and demonstrated that the collection measured 11.5 cm in its longest diameter. HIV test was negative, and further blood tests excluded immunoglobulin deficiency and diabetes. Group A beta haemolytic streptococcus was cultured from the pus but blood cultures were sterile. Empirical intravenous co-amoxiclav was changed to intravenous ceftriaxone and oral clindamycin. He was discharged after 5 days and continued outpatient treatment. After 10 days of ceftriaxone, 20 days of clindamycin and 2 weeks of co-amoxiclav with additional amoxicillin, there was complete radiological resolution of the abscess (Figure 2). Video fluoroscopy and direct pharyngoscopy excluded a piriform sinus fistula (which can be associated with thyroid abscess).<sup>1</sup> All blood tests normalised and no mycobacteria were cultured from extended culture of the abscess fluid.

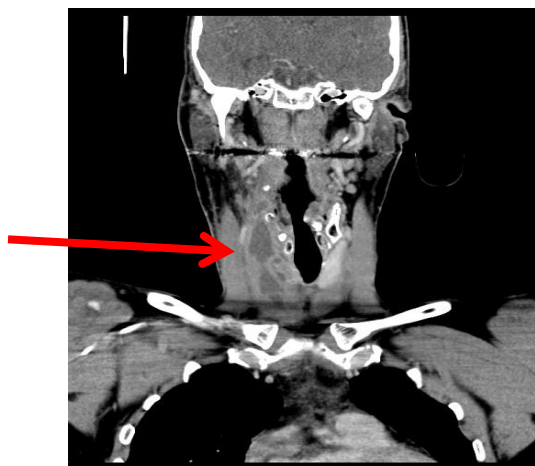


Figure 1 – CT scan demonstrating the large thyroid abscess (red arrow)

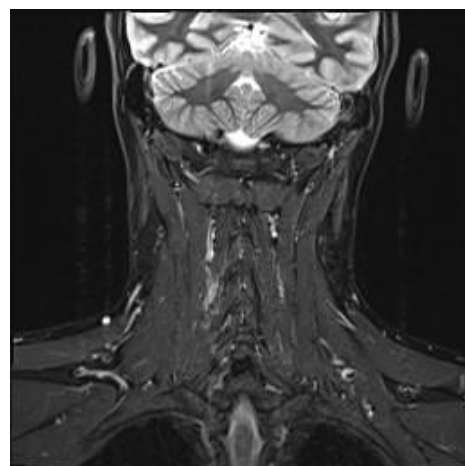


Figure 2 – MRI scan showing complete resolution of the abscess

Viral thyroiditis remains the most likely diagnosis in a patient with a painful thyroid, but bacterial thyroiditis must be considered as although it is rare, its management is different from viral thyroiditis and it is associated with a mortality of up to 12%.

<sup>1</sup>Masuoka H, et al. (2011) Imaging studies in sixty patients with acute suppurative thyroiditis. *Thyroid* 21:1075-1080  
<sup>2</sup>Berger SA, et al. (1983) Infectious Disease of the Thyroid Gland. *Rev Infect Dis* 5:108-122