

# AN EXTENSIVE PRECIPITATION OF CALCIUM IN SUBCUTANEOUS TISSUE IN PATIENT WITH JUVENILE DERMATOMYOSITIS

Boskovic Olivera<sup>1</sup>, Borozan Sanja<sup>1 2</sup>, Vujosevic Snezana<sup>1 2</sup>, Kavarić Sreten<sup>1</sup>, Djogo Aleksandar<sup>1</sup>, Kazic Koviljka<sup>1</sup>, Medenica Sanja<sup>1 2</sup>

<sup>1</sup> Internal medicine Clinic, Clinical Center of Montenegro, Podgorica, Montenegro

<sup>2</sup> Faculty of Medicine, University of Montenegro

Correspondence to [olivbos@t-com.me](mailto:olivbos@t-com.me); [sanja\\_radoman@yahoo.com](mailto:sanja_radoman@yahoo.com)

## INTRODUCTION

Calcinosis cutis refers to a group of disorders in which calcium deposits are being formed in the skin. Depending on the pathophysiologic mechanisms, calcinosis cutis has been classified as metastatic, dystrophic, idiopathic, or iatrogenic (1). In connective tissue diseases, calcinosis is mostly of the dystrophic type and it seems to be a localized process rather than an imbalance of calcium homeostasis (2).

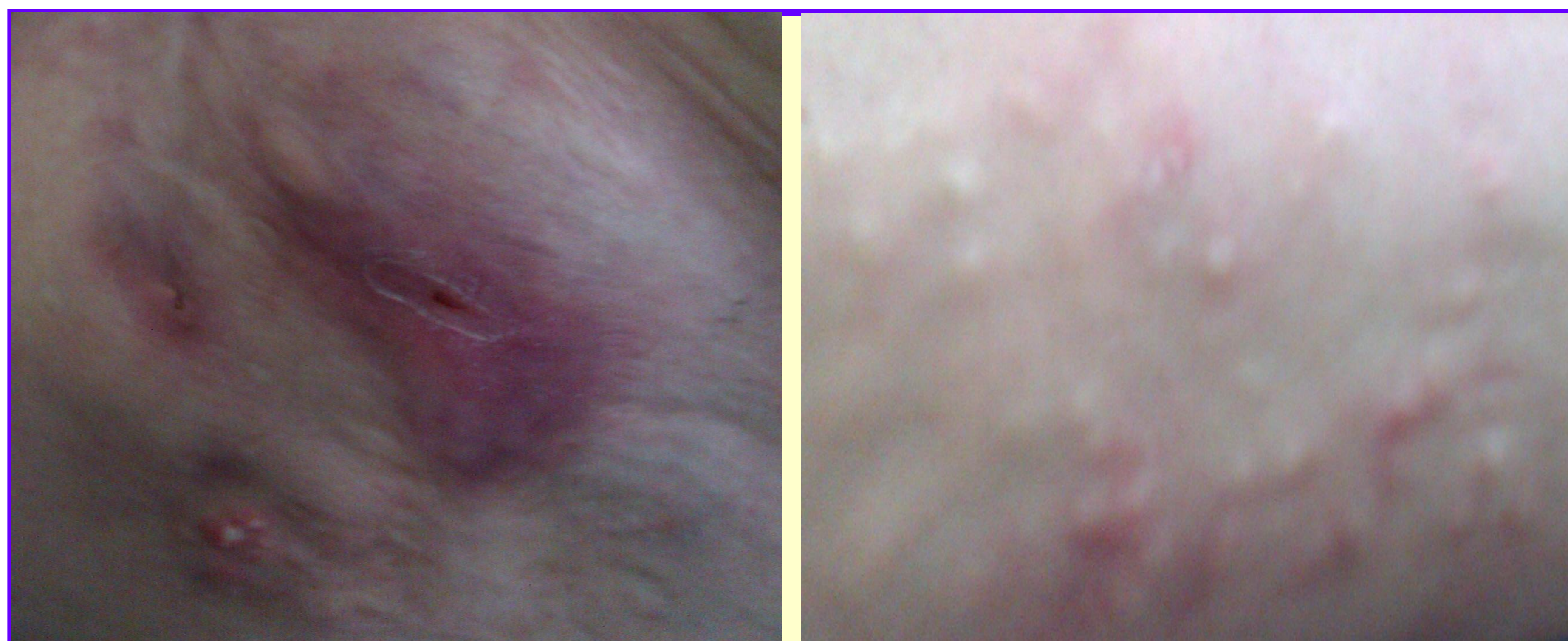Juvenile dermatomyositis (JDM) is a systemic, autoimmune inflammatory muscle disorder and a small vessel vasculopathy that affects children younger than 18 years, primarily the skin and the skeletal muscles (3). Calcinosis cutis occurs in 20-40% of patients with JDM (4). Some severe cases may be associated with advanced calcinosis but the exact mechanism that leads to their development and spreading remains unclear.

## CASE REPORT

A female patient firstly admitted to the hospital at the age of 17 for skin rash, malaise and pain in peripheral joints and muscles. After evaluation a syndrome overlap with dominant atypical dermatomyositis (without muscle enzymes elevated) and systemic lupus erythematosus was suspected and treatment with prednisolone and chloroquine initiated.

After six months subcutaneous calcium deposits in form of multiple firm nodules appeared, firstly in gluteal region, then polytopically. The nodules were gradually enlarging, causing pain and exudation of chalky white material without a previous traumatic event. No metabolic disorders were observed; levels of PTH, phosphorus and calcium have always been in reference range; ANA and anti-dsDNA occasionally elevated.

During the last 12 years, systemic corticosteroids and other different immunosuppressive and immunomodulatory agents (methotrexate, cyclophosphamide, azathioprin, mycophenolat, colchicine), intravenous bisphosphonates, immunoglobulins and calcium antagonists were given in attempt to establish a better disease control, stop spreading and reduce a calcinosis along with tissue damage but without any significant improvement.



Picture 1: Calcinosis over a right hip and proximal part of the right arm

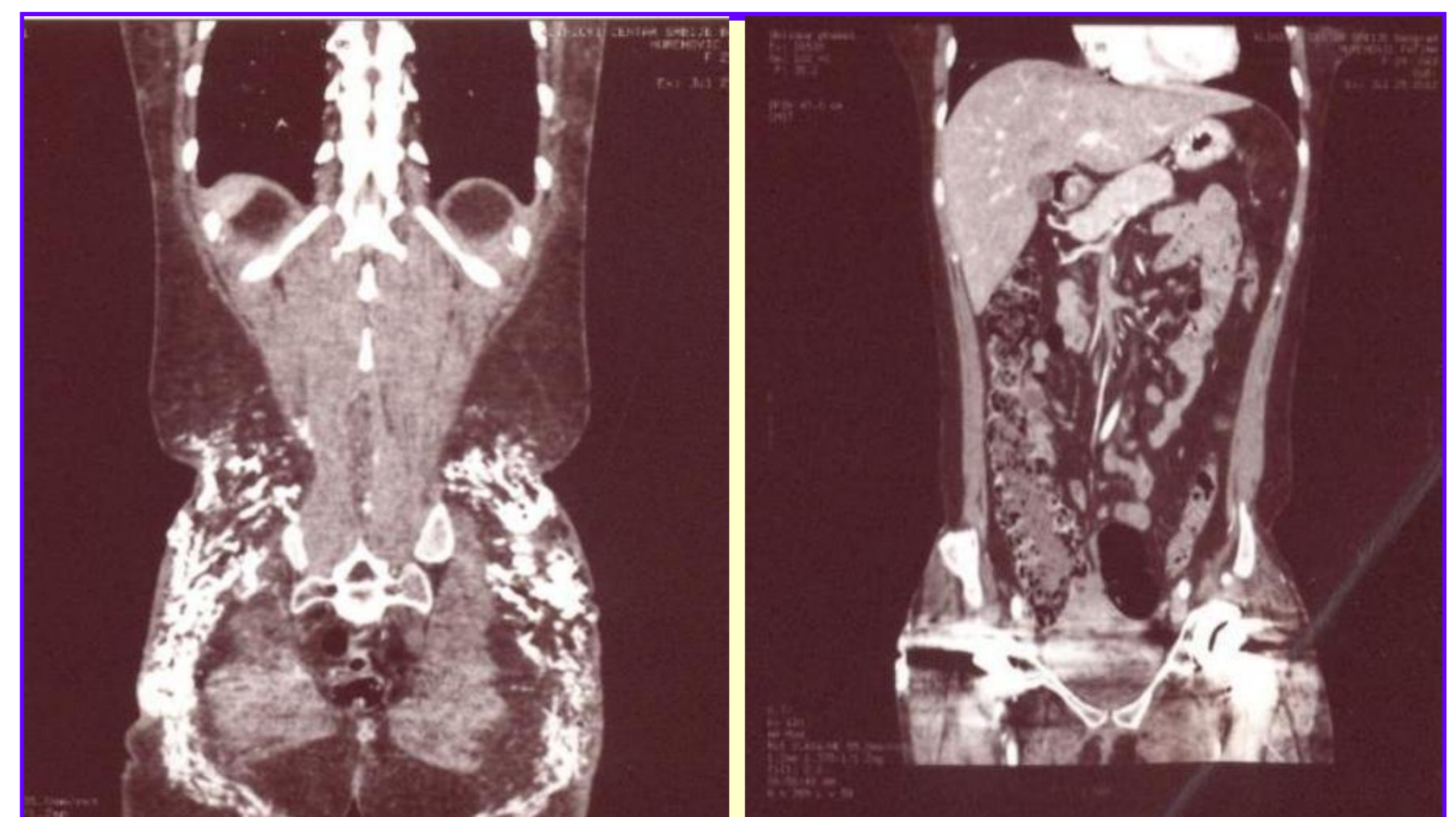


Image 1: MR: an extensive subcutaneous calcinosis

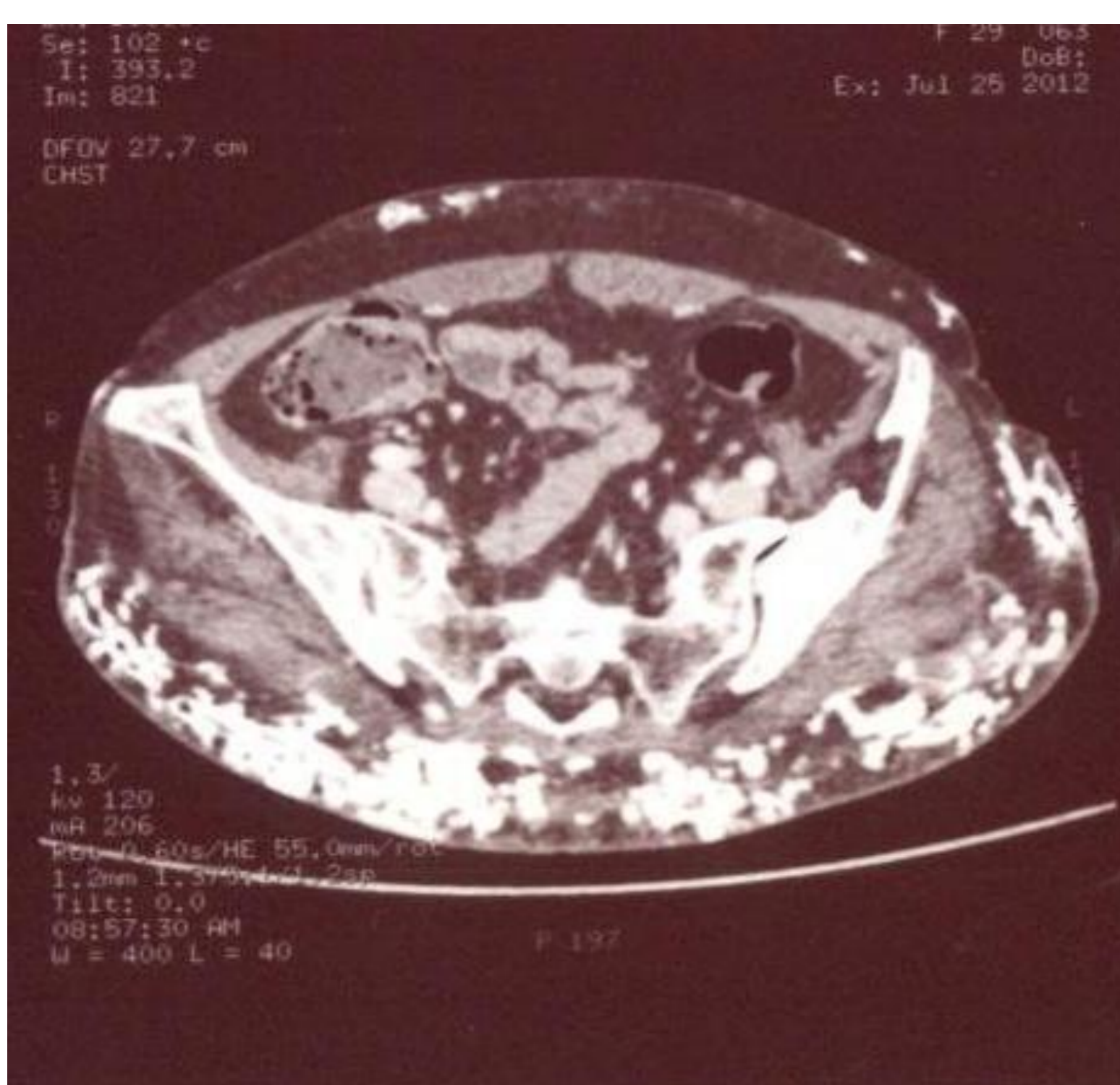

Image 2: MR axial image of calcium deposits in pelvic area

Presently, patient has a Gottron's papules on the dorsal side of MCP and PIP joints of both hands. A very prominent extensive subcutaneous calcinosis (Image 1, 2) with a few skin ulcers (from which calcium is leaking) is over thorax, abdomen, proximal parts of both hands, legs and pelvis, emphasised in lateral part of a right hip (Picture 1). The hands, distal parts of both legs and feet are spared. Some of the nodules are frequently complicated by repeated bacterial infections.

The muscles are atrophic and thin. Functional Index of Myositis (FI) confirmed reduction of muscle endurance in some proximal muscles including neck flexors and shoulder muscles.

A third muscle biopsy showed no calcifications but a discrete findings agreeable with previously assumed diagnosis (increased number of macrophages in the perimysium, a few CD3 T-cells in the endomysial areas).

According to the clinical presentation and findings, early onset and a widespread calcinosis, a diagnosis of JDM is established.

Sedimentation rate remains elevated which, with a current health condition, despite the prolonged treatment, indicates that disease is in active phase. Also, the signs of incipient interstitial lung disease are notable.

Lastly, a treatment with abatacept, alternatively rituximab was recommended.

## CONCLUSION

Although a number of drugs are often given for the treatment of calcinosis, the approach to management is still not established due to inconsistent responses. Revealing a pathogenesis of calcium deposits would certainly bring a new insight to this and similar cases.

## References

1. Julia R Nunley, MD; Chief Editor: Dirk M Elston. Calcinosis Cutis. Available online at: <http://emedicine.medscape.com/article/1103137-overview>
2. Inês Machado Moreira Lobo, Susana Machado, Marta Teixeira, Manuela Selores. Calcinosis cutis: A rare feature of adult dermatomyositis. *Dermatology Online Journal* 14 (1): 10
3. Ann M Reed, Floranne Clayton Ernste. Juvenile Dermatomyositis. Available online at: <http://emedicine.medscape.com/article/1417215-overview>
4. Rider LG. Calcinosis in juvenile dermatomyositis: pathogenesis and current therapies. *Pediatric Rheumatology Online Journal [serial online]*. 2003;1(2):Accessed April 12, 2008.