



S. Kirana<sup>1</sup>, B. Eggert<sup>1</sup>, K. Oberwelland<sup>2</sup>, G. Schürmann<sup>2</sup>, J. Feldkamp<sup>1</sup>

<sup>1</sup> Department of Internal Medicine, Endocrinology and Diabetology, Klinikum Bielefeld Mitte, Germany

<sup>2</sup> Department of General and Visceral Surgery, Klinikum Bielefeld Mitte, Germany

## High rate of malignant disorders in patients with primary hyperparathyroidism

### Introduction

Some new data suggest a coincidence of differentiated thyroid carcinoma (DTH) in patients with primary hyperparathyroidism (pHPT). Rates of co-existing pHPT and thyroid pathology range from 20-67%, with synchronous thyroid cancer occurring in 2 to 24%<sup>1-3</sup>. Aim of the study is to evaluate the coincidence of thyroid cancer and concomitant diseases in our outpatients with pHPT.

### Methods & Design

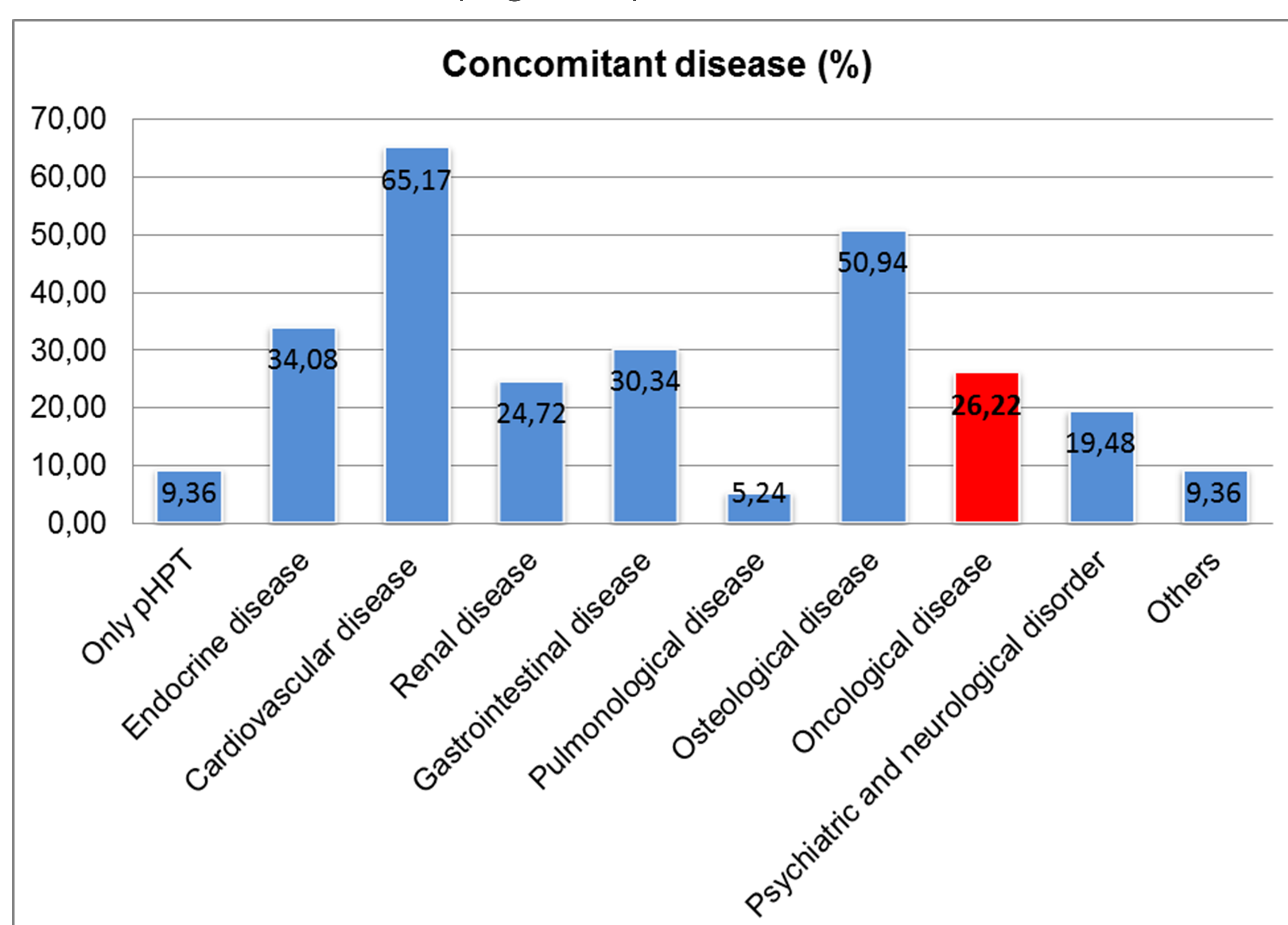
Retrospective analysis of our patients (n = 267) with primary hyperparathyroidism from 2007 until 2011.

### Results

**Table 1. Demographic**

<b>Gender:</b> Female	210 (78.85%)
Male	57 (21.35%)
<b>Treatment:</b>	
Parathyroidectomy	223 (83.5%)
Conservative	44 (16.5%)
<b>Age at parathyroidectomy:</b>	
Female (mean in yrs)	61
Male (mean in yrs)	55
<b>Clinical symptoms related to pHPT (n = 267)</b>	
Musculoskeletal pain	34.22%
Gastrointestinal discomfort	28.84%
Nephrolithiasis	21.13%
Pathological fracture	10.27%

We found 26.2 % of patients had oncological disease, mostly DTH in 17 patients (7.62%) and 34 % suffered from endocrine disease (Figure 1).

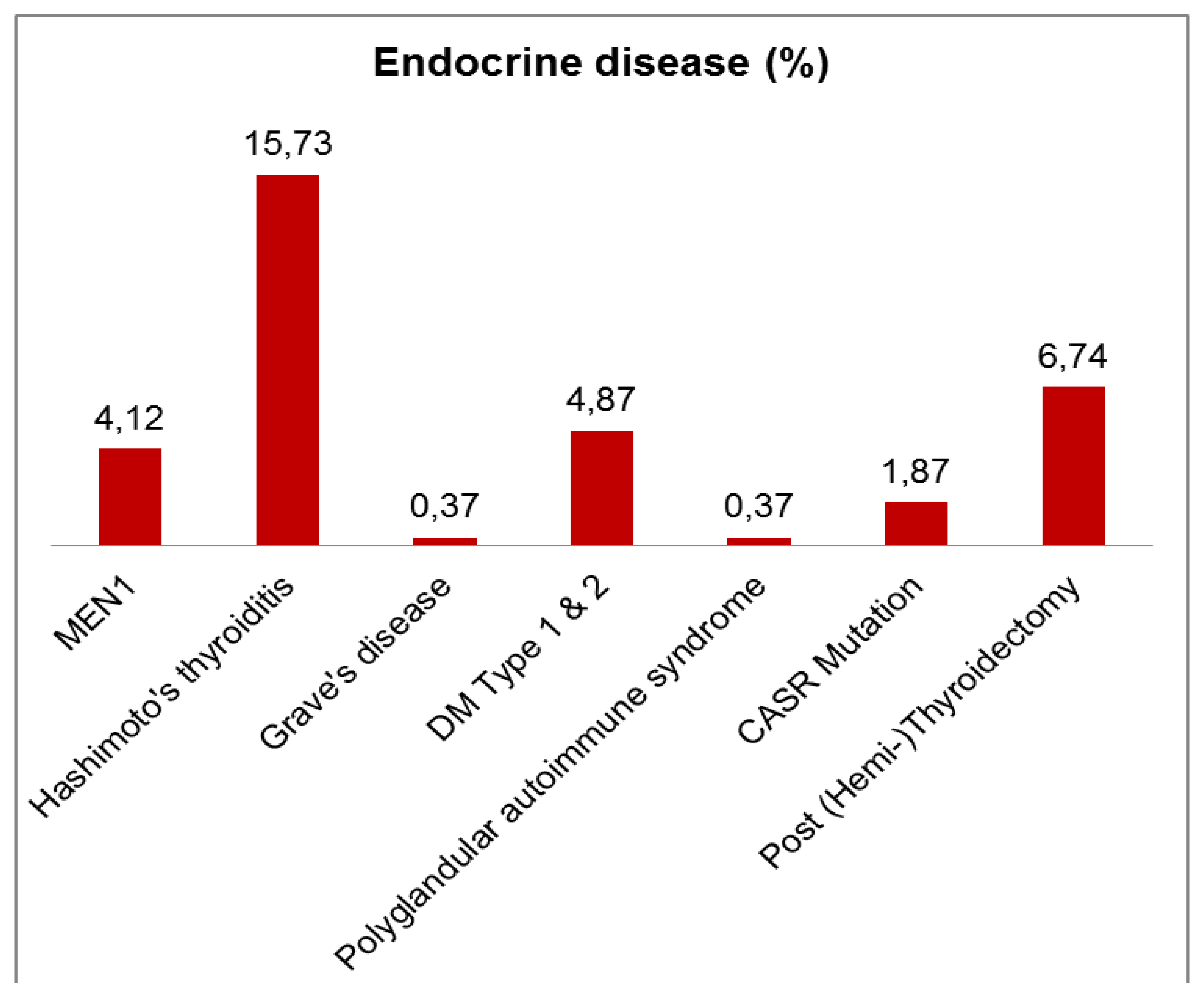


In 257 patients Ultrasound examination showed uninodular goiter in 38 patients (14.8%) and multinodular goiter was found in 117 patients (45.5%).

**Table 2. Histopathological findings of thyroid gland**

Follicular thyroid cancer	2 (0.9%)
Papillary thyroid cancer	14 (6.27%)
Medullary thyroid cancer	1 (0.45%)
C-Cell Hyperplasia	8 (3.58%)

Endocrine disease was found in 91 patients. Most of them suffered from Hashimoto's thyroiditis (Figure 2).



### Conclusion

Thyroid cancer is not rare in patients with pHPT. Many of the patients have a history of other malignant diseases. Hashimoto's thyroiditis is a frequent thyroid disease in this group of patients. It still has to be investigated if there is a causal relationship between malignancy and hyperparathyroidism.

### References

1. Arciero CA, Shiue ZS, Gates JD et al. Preoperative thyroid ultrasound is indicated in patients undergoing parathyroidectomy for primary hyperparathyroidism. J Cancer 2012; 3:1-6
2. Morita SY, Somervell H, Umbricht CB et al. Evaluation for concomitant thyroid nodules and primary hyperparathyroidism in patients undergoing parathyroidectomy or thyroidectomy. Surgery 2008; 144 (6): 862-866
3. Krause UC, Friedrich JH, Olbricht T, Metz K. Association of primary hyperparathyroidism and non-medullary thyroid cancer. Eur J Surg 1996; 162 (9): 685-689