

Effects of the tamoxifen on calcitonin producing thyroid C cells and bone in rat model of male osteoporosis



Branko Filipović, Jasmina Pantelić, Milica Manojlović-Stojanowski, Svetlana Trifunović, Nataša Nestorović, Florina Perčinić-Popovska, Branka Šošić-Jurjević

Institute for Biological Research, University of Belgrade, Belgrade, Serbia, brankof@ibiss.bg.ac.rs

Introduction

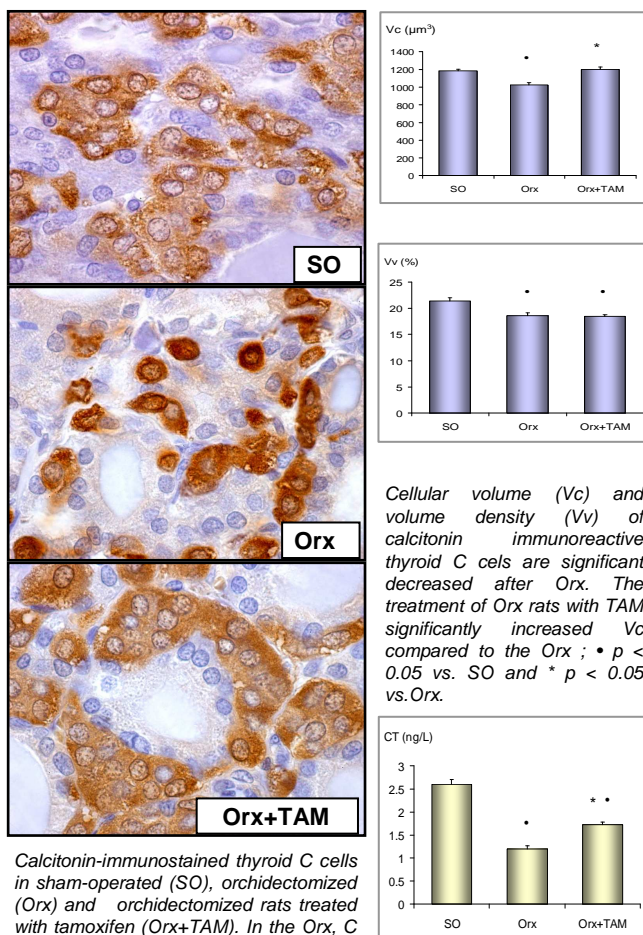
Sex steroids are important for the maintenance of the female and male skeletons. Androgen deficiency is one of the major factor leading to the development of osteoporosis in men. Another important hormone involved in bone metabolism is calcitonin (CT). This potent hypocalcemic peptide, produced by thyroid C cells, contributes to calcium (Ca) homeostasis by direct inhibition of osteoclast-mediated bone resorption and output of Ca from skeletal tissues. Since CT is a potent antiresorptive agent In this study we investigated the effects of tamoxifen (TAM), as a selective estrogen receptor modulator on CT-producing thyroid C cells, skeletal and hormonal changes in middle-aged orchidectomized (Orx) rats as an animal model of male osteoporosis.

Materials and methods

Fifteen-month-old male Wistar rats were divided into Orx and a sham-operated (SO) groups. Two weeks after gonadectomy, one Orx group was injected subcutaneously (s.c.) with tamoxifen citrate (Orx+TAM; 0.03 mg/kg b.w.) for three weeks. The SO and second Orx group were treated s.c. with vehicle alone. A peroxidase-antiperoxidase (PAP) method was applied for localization of CT in the C cells. The volumes of C cells (Vc) and their volume densities (Vv) were determined using the multipurpose M42 test system. An ImageJ public domain image processing program was used to measure bone histomorphometric parameters of the proximal tibial specimens. Blood serum samples were analyzed for CT and osteocalcin (OC), and urine samples for Ca concentration.

Results

Effects of Orx and tamoxifen treatment on thyroid C cell

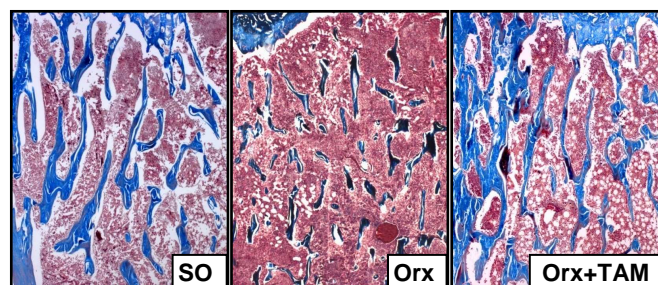


Cellular volume (Vc) and volume density (Vv) of calcitonin immunoreactive thyroid C cells are significant decreased after Orx. The treatment of Orx rats with TAM significantly increased Vc compared to the Orx ; * p < 0.05 vs. SO and * p < 0.05 vs. Orx.

Calcitonin-immunostained thyroid C cells in sham-operated (SO), orchidectomized (Orx) and orchidectomized rats treated with tamoxifen (Orx+TAM). In the Orx, C cells were more individual, smaller and of darker intensity for the CT compared with SO. After TAM treatment, C cells were similar to the SO, with a lighter granular cytoplasm compared with Orx.

The serum calcitonin (CT) concentration; * p < 0.05 vs. SO and * p < 0.05 vs. Orx.

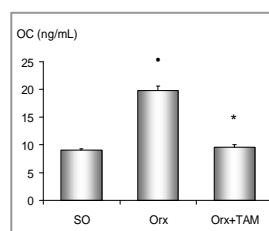
Effects of Orx and tamoxifen treatment on trabecular bone structure



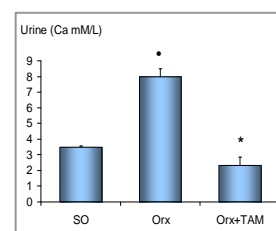
Trabecular bone of the proximal tibia in sham-operated (SO), orchidectomized (Orx) and orchidectomized rats treated with tamoxifen (Orx+TAM). Note reduced mass of blue-stained trabecular bone in Orx rats. TAM treatment prevented loss of trabecular bone; Azam method stain.

Trabecular bone histomorphometry

	B.Ar (%)	Tb.Th (µm)	Tb.N (mm)	Tb.Sp (µm)
SO	12.95±0.74	35.80±0.10	3.62±0.21	242±18.50
Orx	6.25±0.25 *	28.69±1.26 *	2.94±0.04 *	308±10.25 *
Orx+TAM	13.33±0.78 *	37.05 ±1.95 *	3.70±0.10 *	233±10.00 *



The serum osteocalcin (OC) concentration; * p < 0.05 vs. SO and * p < 0.05 vs. Orx.



The urine calcium (Ca) concentration; * p < 0.05 vs. SO and * p < 0.05 vs. Orx.

Conclusion Androgen deficiency after Orx of male middle-aged rats affected thyroid C cell and reduced the synthesis and release of calcitonin. This was accompanied by a striking decrease in bone mass. Subsequent tamoxifen treatment in this rat model of male osteoporosis stimulated calcitonin secreting C cell activity. Additionally, this selective estrogen receptor modulator increased tibial trabecular bone mass and decreased bone turnover.