

- Case report -

“Clinical Case reports - pituitary/adrenal” EP-1205

DS Tesic¹, M Mitrovic¹, J Vlaski², S Damjanovic³, V Popovic³

¹Clinic for Endocrinology, Diabetes and Metabolic Disturbances, KC of Vojvodina in Novi Sad

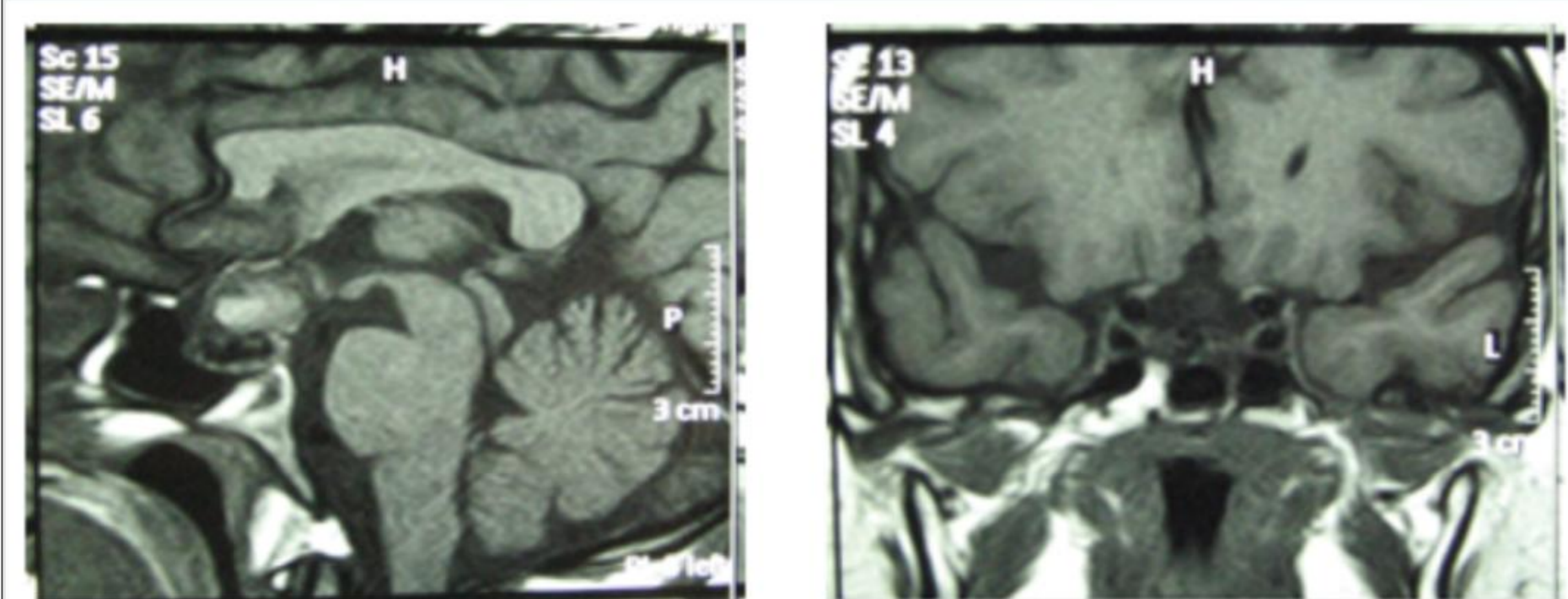
²Department of Pediatrics, KC of Vojvodina in Novi Sad ³Institute for Endocrinology, Diabetes and Metabolic Diseases, KC of Serbia, Belgrade

Introduction: Growth without growth hormone is seen also in patient with craniopharingeoma. We just speculate what anabolic factors might be involved in this process. However, estrogen thru it's receptors lead to epiphyseal fusion. In this case report we would like to present the patient with bilateral slipped femoral epiphysis (SFE) and interventions made at

Then patient was moved on endocrinology department. Clinically, according to sex characteristics, patient was Tanner I stage, without measurable values of growth hormone, insulin like growth factor I, gonadotropins and estrogens, insulinemia 17,3 mU/L, blood glucose 4,5 mmol/l.

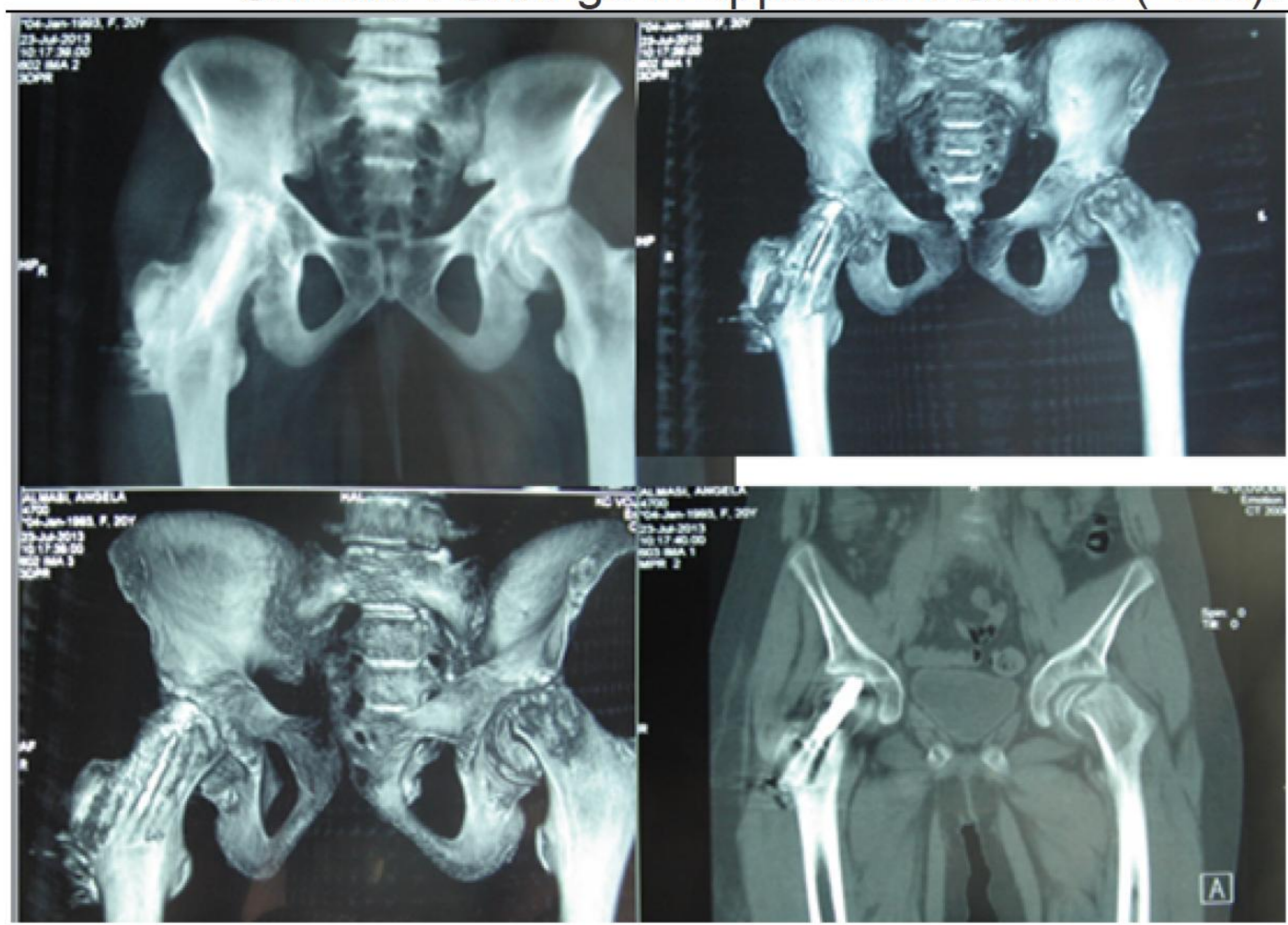
Case report: female, born: 4th-jan-1993, operated on 22nd-nov-2002) from craniopharingeoma diagnosed on MRI.

Picture 1: MRI of hypophysis on 12th-nov-2012.

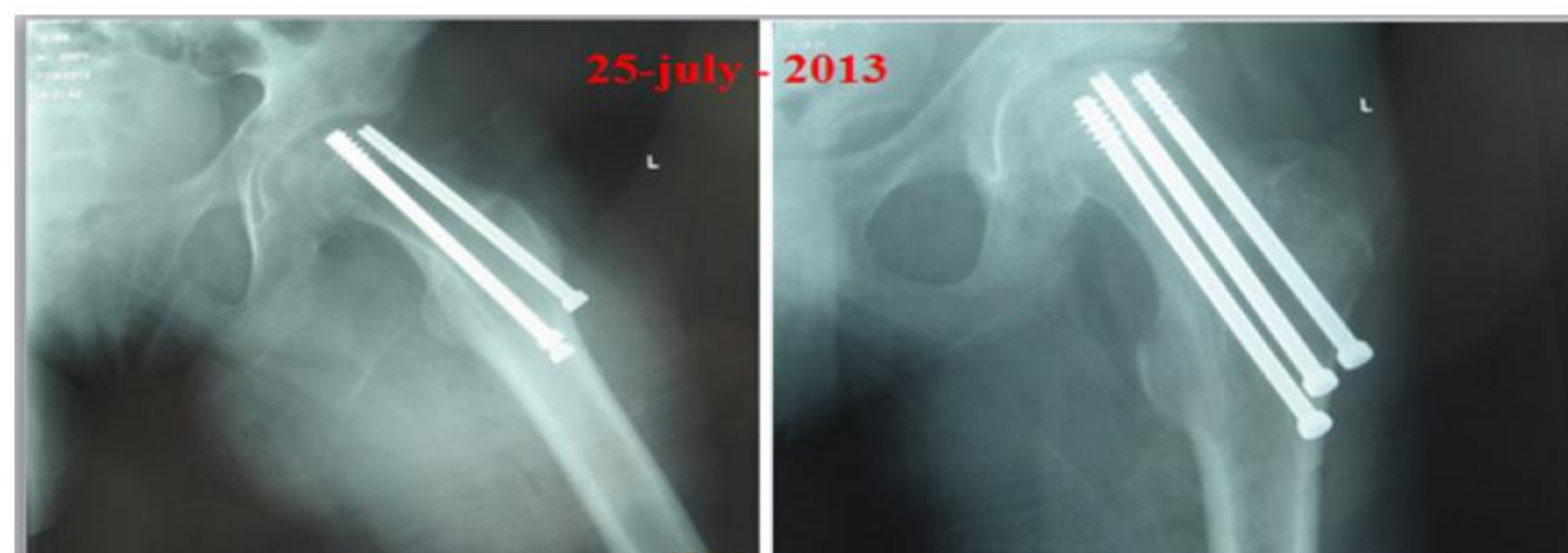

Body height 167cm, body weight 71.8 kg, not regularly on levothyroxine 50µgr, in **December 2013** presented as pain in right hip, on X ray SFE, and osteosynthesis was performed.

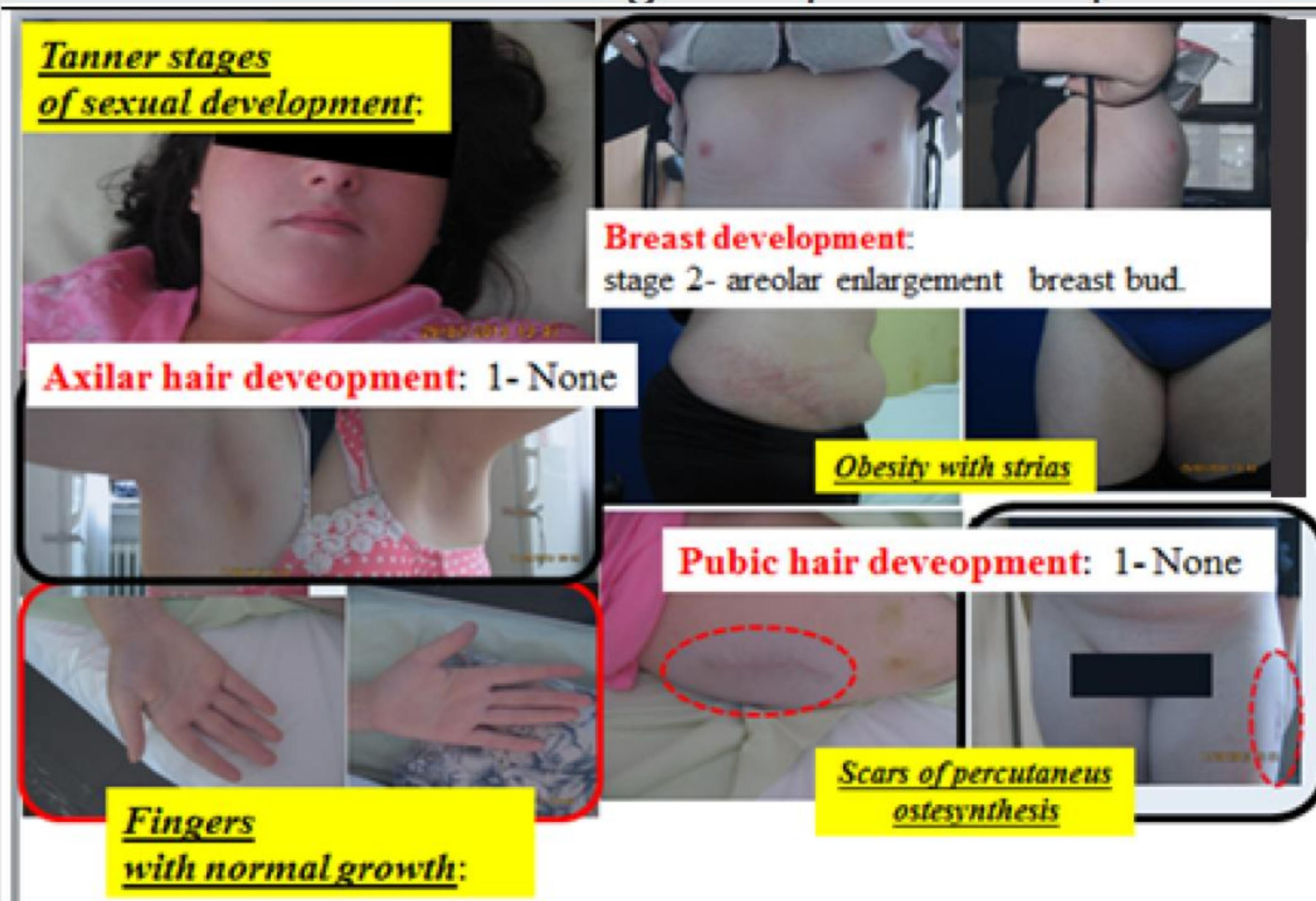
Picture 2: Slipped left capital femoral epiphysis ("Acute-on-Chronic". Change in apposition: Severe (>2/3).



In July 2013 similar clinical picture but on left side. Patient was sented at tertiary level. After multislice CT scanning same surgical procedure performed on left femur with 3 screws.

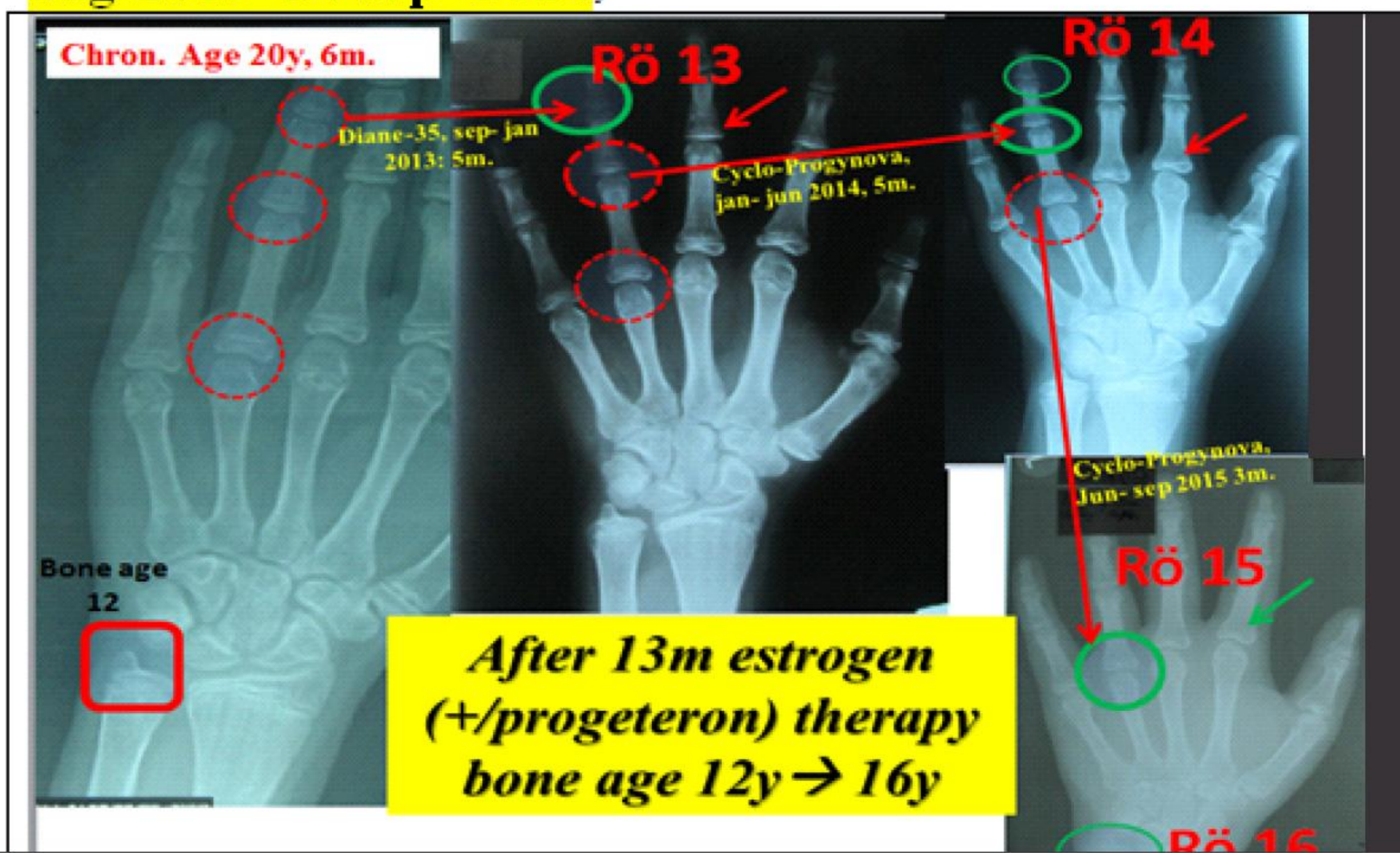


Picture 3: Tanner stages in presented patient. :



On X ray of the left hand skeletal age was 12y. Estrogen therapy started with 0,035 mg etinil estradiol and after 5 months increased on 2mg estradiol, 21day and 7 day pause. Skeletal age at 5m, 10m and 13 were 13y6m, 14y, 15-16y, respectively.

aug-2013- 24-sep- 2014.



Conclusions: After the operation of craniopharingeoma and growth without growth hormone we have to follow skeletal growth and on time introduce sex hormones. Later, in young adults we have to consider a small dosages of growth hormone to improve their's body composition.

References: 1. Open reduction of slipped capital femoral epiphysis; NICE Interventional Procedure Guidance, January 2015. 2. Sasigarn A. International Journal of Pediatric Endocrinology, Vol 2009, Article ID 609131, 3 pages