



HYPONATREMIA IN SECONDARY ADRENAL INSUFFICIENCY AFTER TRANSSPHEOIDAL SURGERY OF PITUITARY ADENOMA - CASE REPORT



G.Pemovska 1, T.Bajrktarova Proseva 2, S.Jovanovska Mishevska 1

University Clinic of Endocrinology, Diabetes and Metabolic Disorders, Skopje 1, Clinical Hospital Shtip 2; Macedonia

Introduction

Secondary adrenal insufficiency after Transsphenoidal pituitary surgery can lead to the development of severe hyponatremia with potentially fatal consequences.

Severe hyponatremia, defined as a serum sodium below 120 mmol/l, especially if is acute, can cause seizures, cerebral edema, coma, respiratory arrest and death.

Case report

A 34 year old patient was admitted as an urgent case at the Clinic of Endocrinology, with symptoms and signs of Addisonian crisis (dizziness, headaches, nausea, vomiting, hypotension), with muscular weakness and muscle aches, tingling hands and confusion,

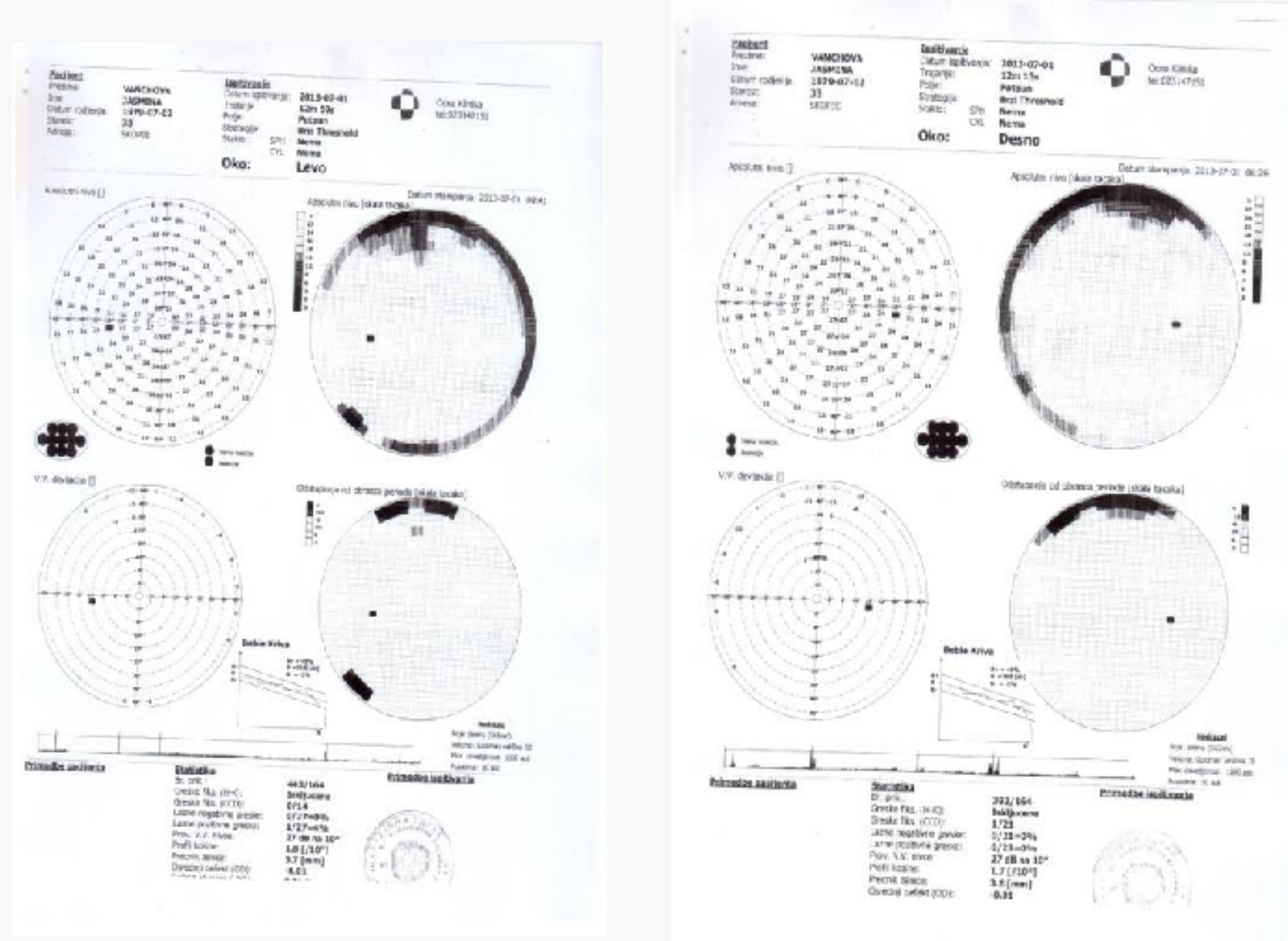
It was a patient diagnosed with acromegaly due to STH secreting macroadenoma, with onset of symptoms 10 days after transphenoid pituitary surgery for macroadenoma.

The first symptoms appeared 7-8 years ago, when she noticed that her voice becomes rough, she found changes in the face (elongation of the face, the protrusion of the supraorbital arcs, swelling around the eyes, extending and increasing the nose), expanding feet – she had boosted the shoes one number more, prominence of the clavícula and bone pain at rest.

In June 2013 she was checked up by an internist because of missed menstrual cycles for 3 months and a pain in the area of the ovaries, who forwarded her to the Endocrinologist with the suspicion of acromegaly.

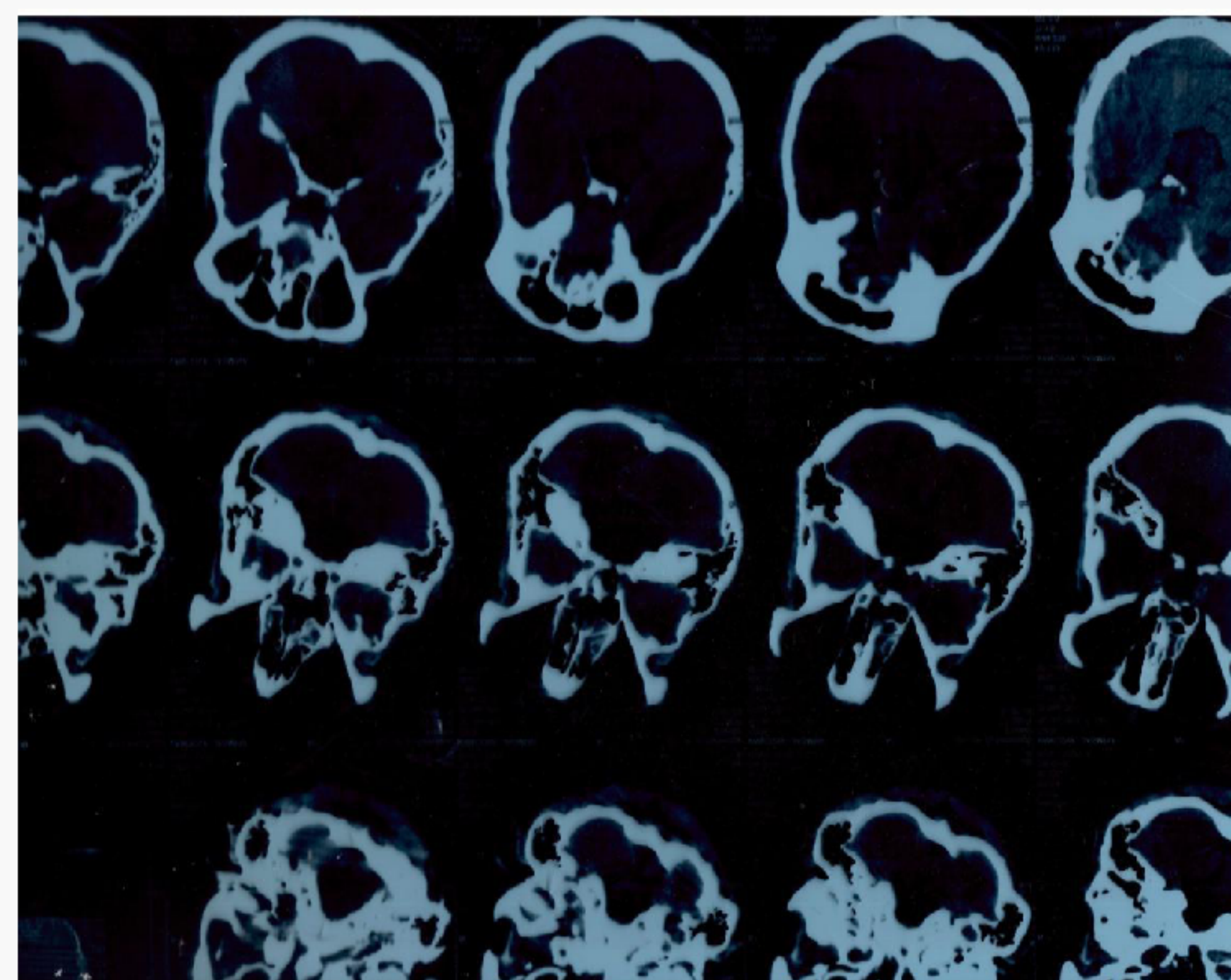
Methods

Pituitary MRI was performed in July 2013 and was found 16x14 mm solid substrate in the adenohypophysis, which performs remodeling at the bottom of the sella. The basal value STH was 17,1 ng/ml, and during the OGTT STH suppression was absent, with no one STH value under 1 ng/ml at any point during the test. Echocardiography was with normal findings and EF-62%. Visual field was with discrete peripheral outburst in both eyes.



Surgery was performed on September 19, 2013 in Zagreb. Ten days after, the patient began to feel marked fatigue, nausea, vomiting, became confused and hypotensive. She was hospitalized under the suspicion of secondary acute adrenal insufficiency

Brain KT



Results

The biochemical analyses showed severe hyponatremia (Na = 116,118,122,135,136 mmol/L). There were no hormonal dysfunctions detected in the pituitary-thyroid and pituitary-gonadal axis, values of STH were 1,6 ng/ml.

Because of expressed slow mental process, disorientation and somnolence, brain KT was made, showing reduction in the ventricular system, flattened gyri and loss of sulci, suggesting cerebral edema. The condition of the patient was improved after the correction of hyponatremia with hydrocortisone in a dose of 300 mg daily.

Conclusion

Postoperative hyponatremia after transsphenoidal surgery is more common than previously reported and may lead to fatal complications. Therefore, all patients should undergo serum electrolyte level monitoring regularly for at least 1 or 2 weeks after transsphenoidal surgery. Severe hyponatremia is associated with increased morbidity and mortality. During the evaluation of hyponatremia, evaluation of endocrine dysfunction (hypothyroidism, hypocortisolemia) should be evaluated as a possible cause. Prompt diagnosis and adequate hormonal replacement therapy are essential to block an otherwise unfavorable course of the disease.

References:

1. Severe hyponatremia caused by hypothalamic adrenal insufficiency. *Shibata T, Oeda T, Saito Y. Intern Med. 1999 May; 38(5):426-32.*
2. Hyponatremia after trans-sphenoidal surgery. *Janneck M, Burkhardt T, Rotermund R, Sauer N, Flitsch J, Aberle J. Minerva Endocrinol. 2014 Mar; 39(1):27-31.*
3. Delayed hyponatremia after transsphenoidal surgery for pituitary adenoma. Report of nine cases. *Kelly DF, Laws ER Jr, Fossett D.J Neurosurg. 1995 Aug; 83(2):363-7.*

