

ECTOPIC ACTH SYNDROME DUE TO PANCREATIC NEUROENDOCRINE TUMOR. A CASE REPORT.

J MARTI, E ZUBILLAGA, Y BOCANGEL , A YOLDI (2).

DEPARTMENTS OF INTERNAL MEDICINE HOSPITAL ZUMARRAGA AND ENDOCRINOLOGY(2)
H U DONOSTIA. GUIPUZCOA. SPAIN.

The ectopic secretion of corticotropin from non-pituitary tumours causes approximately 10-20% of cases of Cushing's syndrome. Enteropancreatic neuroendocrine carcinoma represents a rare cause of ectopic ACTH syndrome. Neuroendocrine tumours (NETs) of the gastro-entero-pancreatic system are rare, with an incidence of 1~2/100,000 individuals per year and are equally distributed between the sexes. Among the pancreatic NETs (p-NETs), insulinoma (31.7%) and gastrinoma (8.6%) are the common islet cell tumours. There are also non-functioning islet neoplasms (47.7%) and other ectopic hormone (such as ACTH)-producing tumours (1.2%)

Case.

A 51 years-old woman without past medical history was admitted by gain weight, facial oedema 4 months previous. Physical examination: BP 167/124, cardiac rate 49 bpm, facial oedema, truncular obesity. No other abnormalities. Laboratory test. Blood count cells, normal. Biochemistry. Glucose 148 mg/dL. kaliemia 2,8 mEq/L. Endocrine tests. Cortisol 102 ug/dL. Nocturnal cortisol 132 ug/dL, urinary free cortisol 4,000 mcg/24h. ACTH: 427 pg/ml. Lack of circadian rhythm and non-suppressibility by low-dose and high dose (8mgr) dexamethasone administration. Chromogranin A 526 ng/mL. CT scan revealed a pancreatic mass of 30 x 20 mm and enlargement of adrenal glands (fig 1). PET scan displayed abnormal accumulations of fluorodeoxyglucose in pancreatic area, distribution at multiple sites in the liver and enlargement of both adrenal glands (fig 2). Surgical procedure was carried out and large pancreatic tumour with multiple hepatic metastasis were observed. Pancreatectomy and splenectomy were carried out. Histopathological study showed pancreatic neuroendocrine tumour, positive to chromogranin, synaptophysin and CKAE1-AE3, Ki 67 up 50%, with lymph nodes and liver metastasis of neuroendocrine tumour. Surgical treatment of adrenal gland was discarded. Treatment with ketoconazole and metyrapone was initiated without improvement and Mifepristone was added, lowering cortisol levels, however, outcome was unfavourable and patient died 3 months after diagnosis by respiratory distress and complications of Cushing syndrome.

Fig. 1

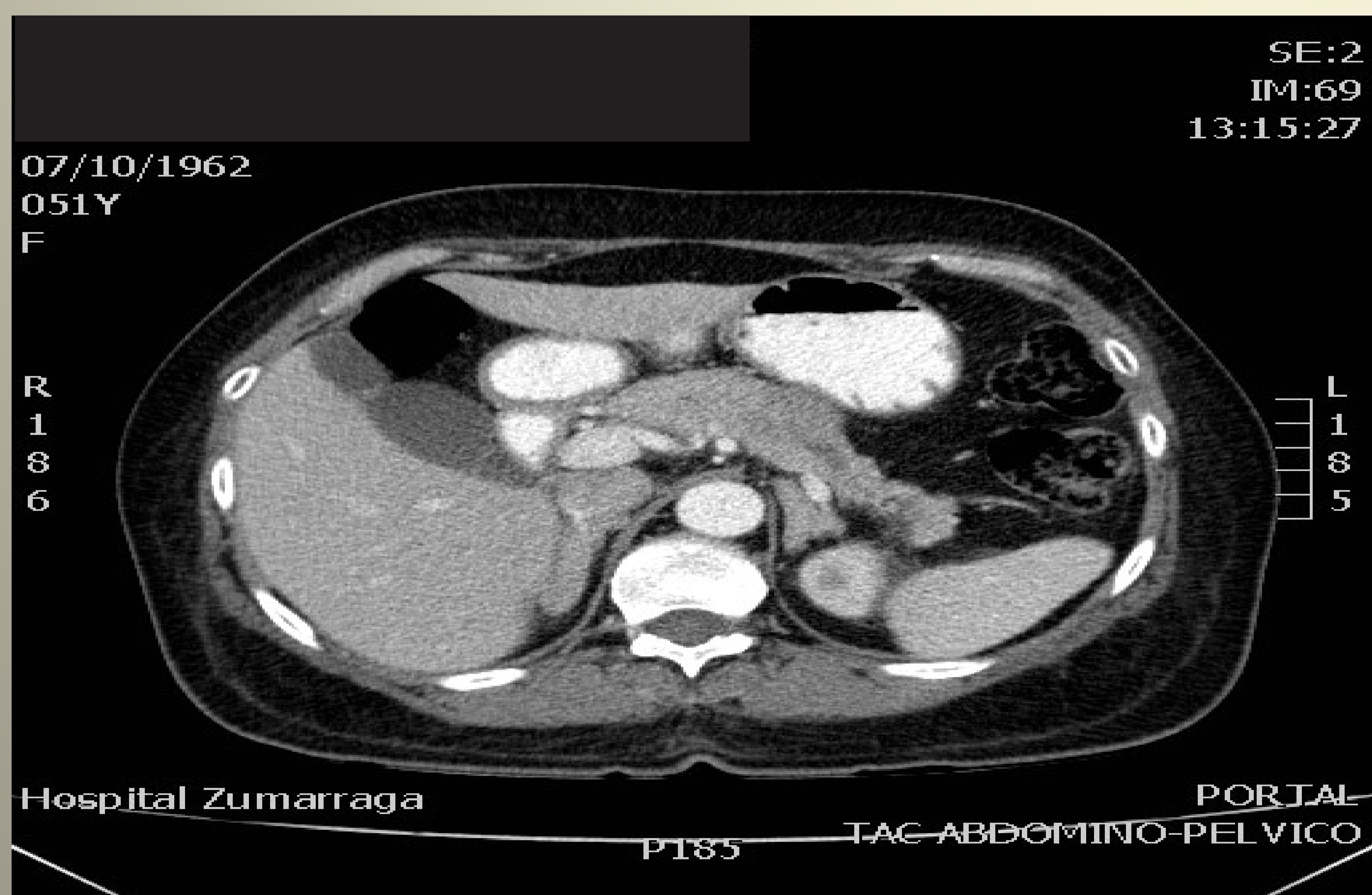
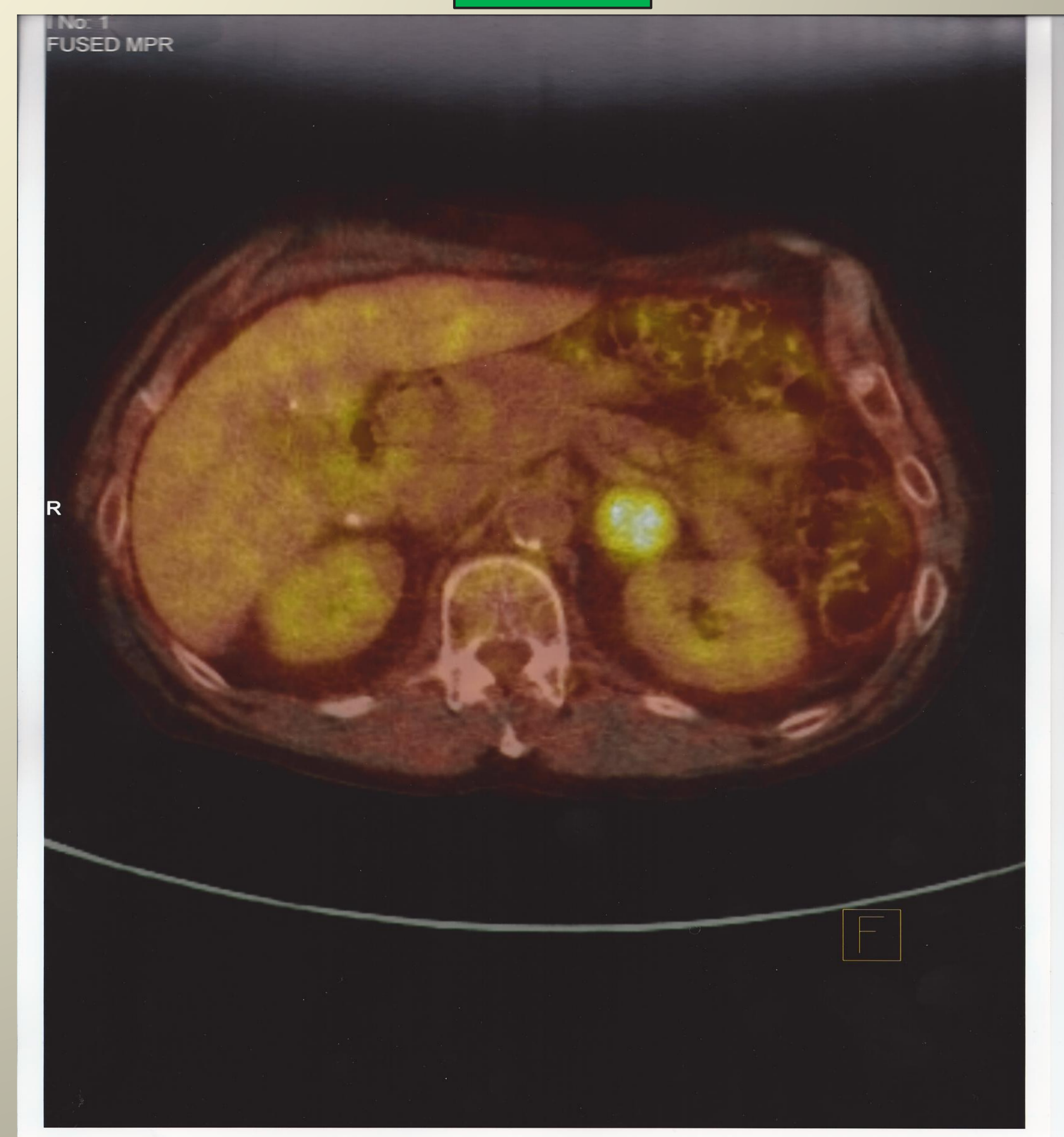


Fig.2



Discussion

Patients with pancreatic neuroendocrine carcinoma represent a rare cause of ectopic ACTH syndrome. A typical Cushingoid appearance is less frequent in ectopic ACTH syndrome. Treatment of ectopic ACTH syndrome is excision of the primary tumour. However, curative surgery is successful in only 30% to 47%. If the tumour cannot be resected, bilateral adrenalectomy offers effective permanent treatment. Medical cortisol inhibitors include ketoconazole, metyrapone

