


Hypercoagulable state: An evidence of linkage with hyperthyroidism

Sherpa K, Maskey R, Karki P, Bhatta N, Mishra D.R., Peeyush D, Pandey N
Correspondence address: Dr. Kunjang Sherpa, Sherpakunjang@hotmail.com



Department of Internal Medicine, B.P. Koirala Institute Of Health Science, Dharan, Nepal

Introduction

- Hyperthyroidism is not a widely recognized association with Venous thromboembolism(VTE).
- However, Several previous studies suggest that hyperthyroidism represent a potential hypercoagulable and hypofibrinolytic state, which may contribute to the increased risk of thromboembolism.

Case report

A 39-year-old lady presented with Swelling over bilateral lower limbs for 1 month, Palpitation for 1 month. She had history of swelling over neck for last 13 yrs and protrusion of bilateral eye for 13 years, history of increased sweating, anxiety, and weight loss of about 10 kg in last 6 months.

On examination : patient had staring appearance, atrial fibrillation, She also had pallor, bilateral exophthalmos ("NO SPECS"-2), Diffuse goiter, bilateral non pitting pedal edema with hyperpigmented plaques over dorsum of leg and foot .

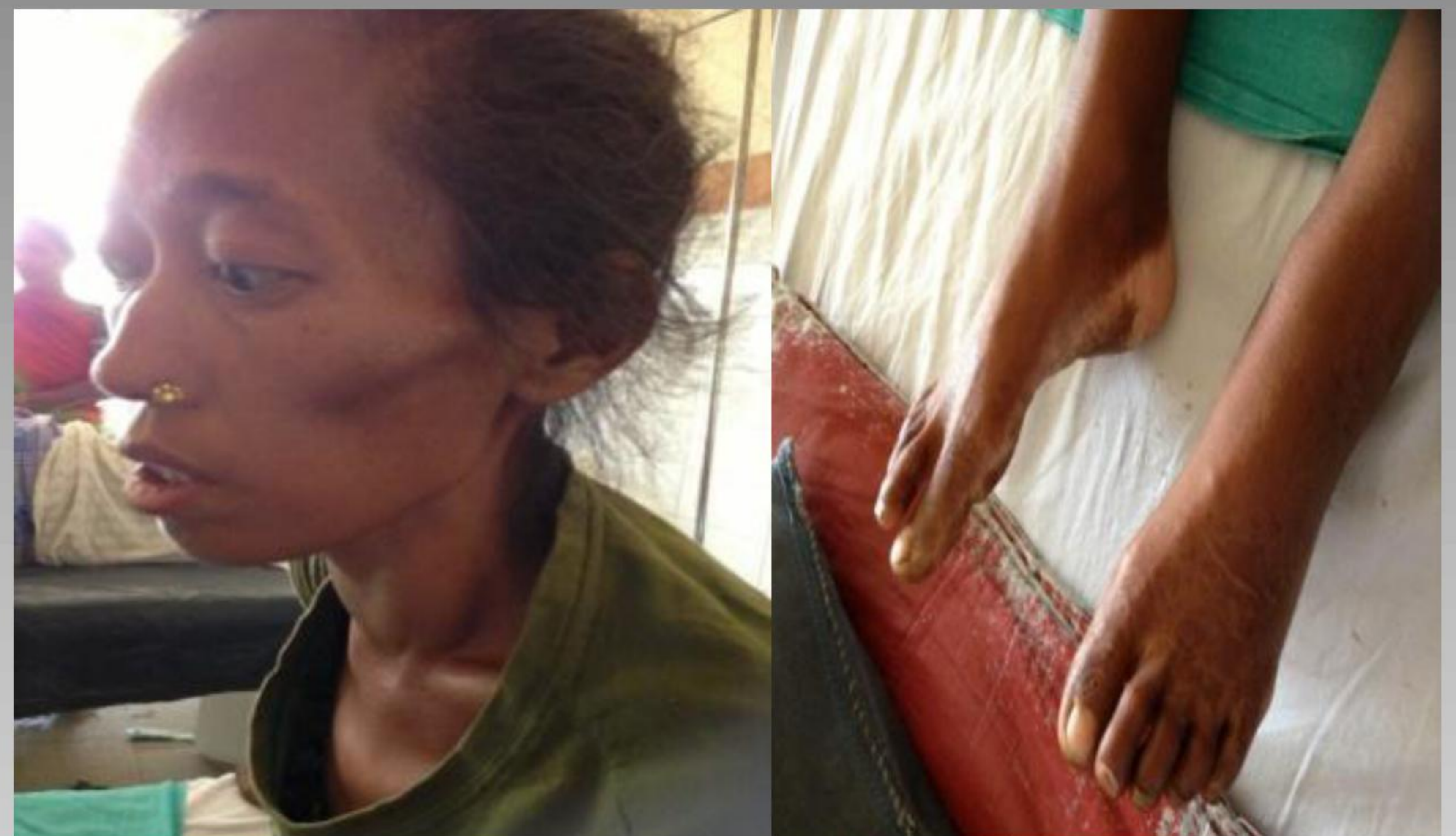Investigation

Thyroid Function test- TSH = <0.05 mIU/L, fT3 = 29.8 pmol/L, fT4 = >100 pmol/L

Venous Doppler ultrasound (USG) : Presence of an echogenic thrombus in bilateral lower limb extending into femoral vein in right side and up to popliteal vein in left side and

USG neck: diffusely enlarged thyroid gland with heterogenous echotexture with increased vascularity.

The patient was treated with antithyroid drugs, anticoagulants, and betablockers. The patient improved clinically with normalization of thyroid function



Taken with permission

Discussion

- Procoagulant state occurs in overt hyperthyroid patients.
- Potential hypercoagulable and hypofibrinolytic state in hyperthyroidism contribute to the increased risk of thromboembolism.
- In a recent systematic analysis, Franchini *et al.* documented 34 cases of venous thrombosis occurring in patients with overt hyperthyroidism.
- Risk of venous thrombosis rises with increasing free thyroxine level.

CONCLUSION

- Our case report reinforces the available evidence on the possible role of overt hyperthyroidism as VTE risk factor.
- It seems worthwhile to measure thyroid hormones in patients with unprovoked venous thromboembolic event and in contrarily the diagnosis of venous thromboembolism should be considered in patients with hyperthyroidism, particularly if additional prothrombotic risk factors are present and should be treated to prevent grave complication.

REFERENCES:

- Squizzato A, Romualdi E, Buller HR, Gerdes VE. Clinical review: Thyroid dysfunction and effects on coagulation and fibrinolysis: A systematic review. *J Clin Endocrinol Metab.* 2007;92:2415–20
- Lodha A, Haran M, Frankel R, Shani J. Thyrotoxicosis causing arterial and venous thrombosis. *Am J Med Sci.* 2009;338(5):428.
- Bregje van zanne. Increasing level of free thyroxine as a risk factor of first venous thrombosis: a case control study *Blood* 2010;115;4344-49
- Erem C. Thyroid disorders and hypercoagulability. *Semin Thromb Hemost* 2011;37:17-26.
- Franchini M, Lippi G, Targher G. Hyperthyroidism and venous thrombosis: A casual or causal association? A systematic literature review. *Clin Appl Thromb Hemost* 2011;17:387-92

