

QUICK INTRAOPERATIVE PTH FROM THE INTERNAL JUGULAR VEIN AND BEFORE WOUND SUTURE IMPROVES CURE RATE OF MINIMALLY INVASIVE SURGERY IN PATIENTS WITH PRIMARY HYPERPARATHYROIDISM

Cristian velicescu, Radu Dănilă, Alexandru Grigorovici, Alina Gațu, Cristina Preda, Voichița Mogoș, Dumitru D. Brănișteanu
University of Medicine and Pharmacy "Gr.T.Popa" Iași, Romania



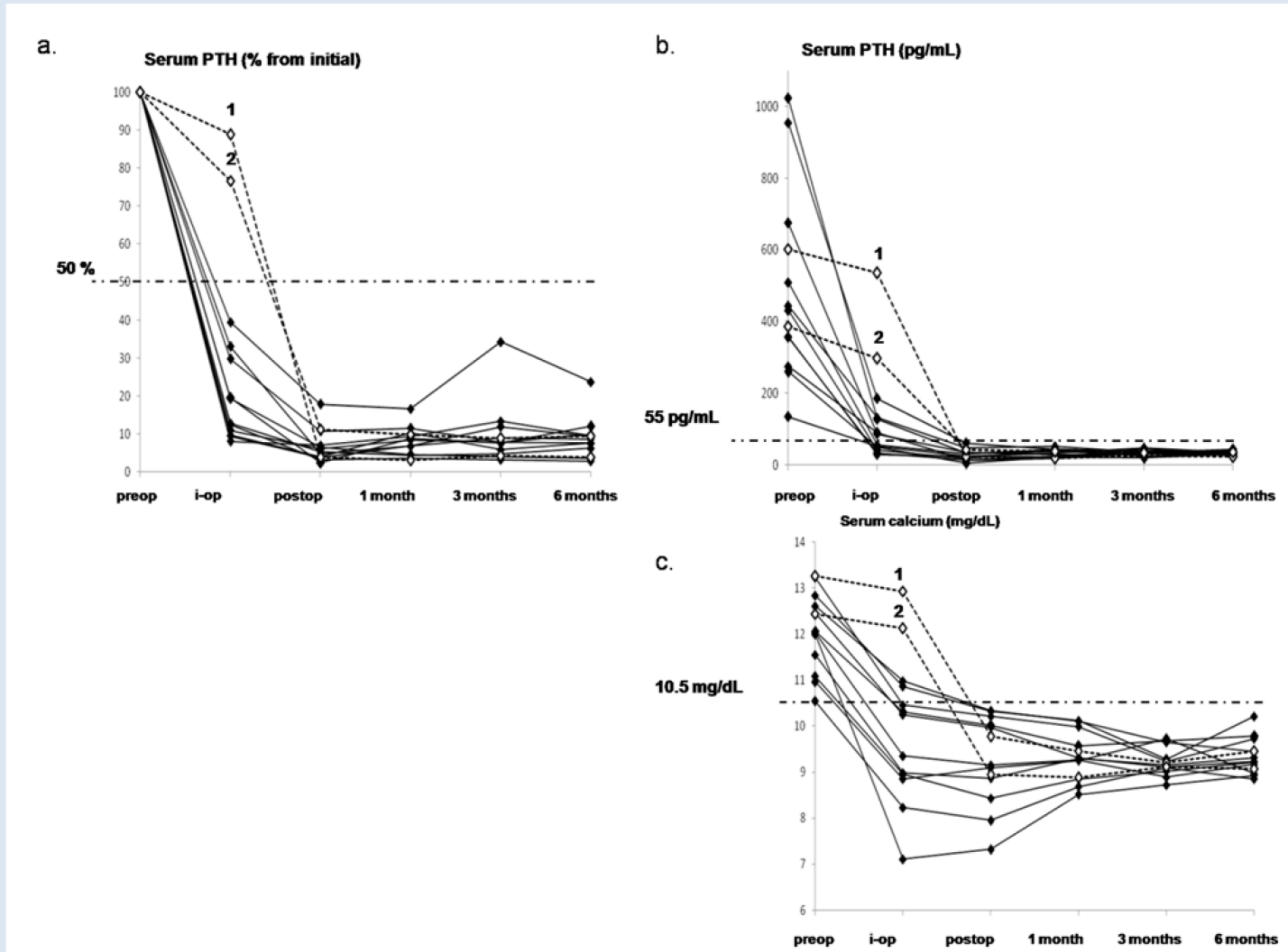
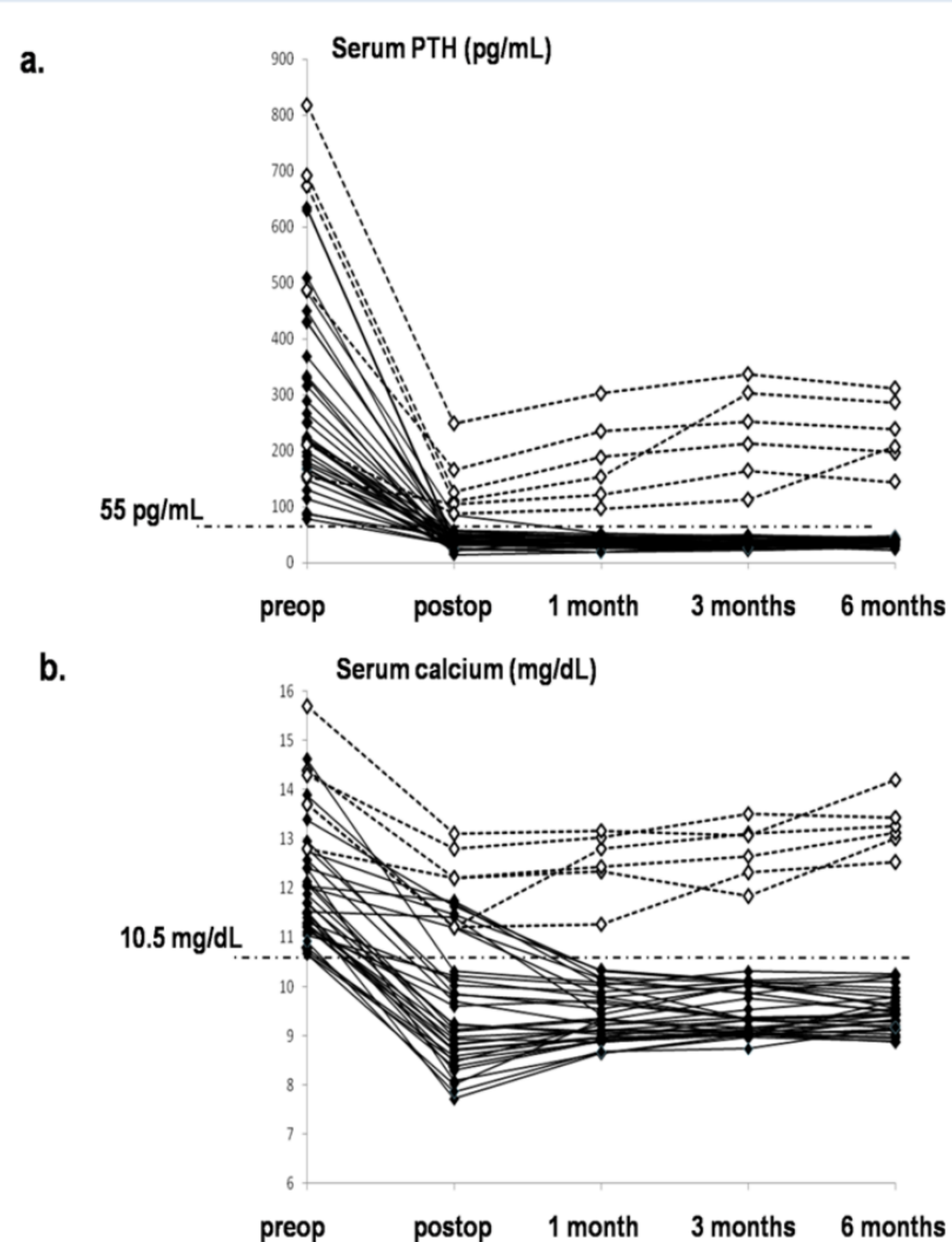
Purpose

to evaluate the importance of parathyroid adenoma preoperative localization and the advantage of intraoperative quick PTH evaluation for optimizing surgical cure rate in patients with sporadic primary hyperparathyroidism.

Materials Methods

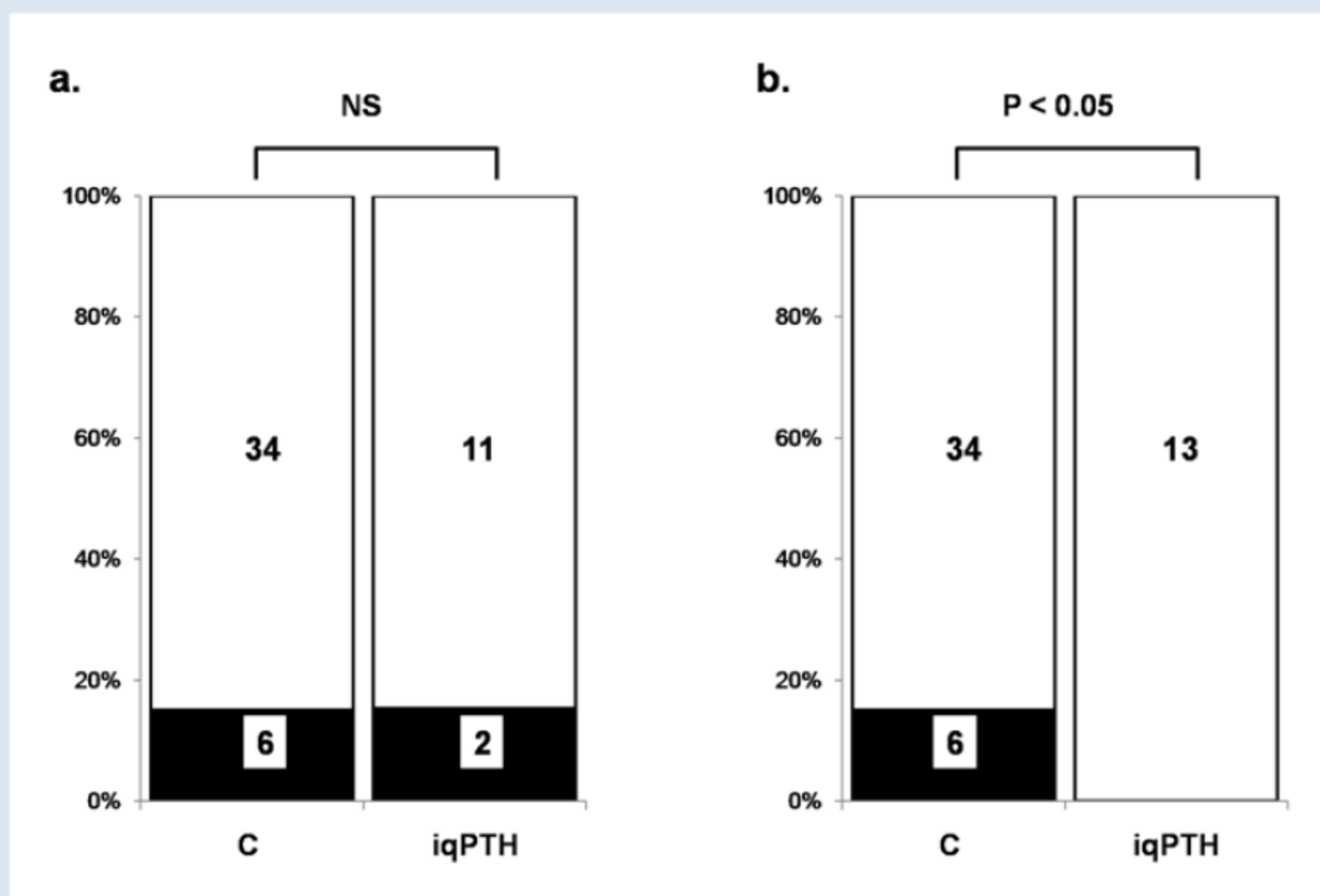
- retrospective review of a prospective surgery database of 53 patients with primary hyperparathyroidism
- preoperative image of solitary parathyroid adenoma obtained on 99mTc-SestaMIBI and overlapped on ultrasound image
- excision of the parathyroid adenoma - confirmed by frozen section analysis performed during surgery
- Groups:
 - group C (fourty patients) were operated without evaluation of intraoperative quick PTH.
 - group iqPTH (thirteen patients) where intraoperative PTH and calcium were evaluated from the ipsilateral jugular vein immediately after adenoma excision. When PTH did not decrease below 50% of the maximal preoperative levels, minimal invasive parathyroidectomy was converted to open neck surgery.
- Patients were followed up by PTH and calcium measurement first day after surgery and at 1, 3 and 6 months after surgery.

Results



The evolution of PTH (a) and calcium (b) levels at 40 patients operated by minimally invasive surgery for preoperative localized solitary parathyroid adenoma before (preop), the next day (postop), at 1, 3 and 6 months after surgery. Long term normalization of PTH (< 55 pg/mL) and calcium (< 10.5 mg/dL) levels was achieved in 34 out of 40 patients, who were considered cured (black diamonds, continuous lines). Six patients persisted having high PTH and calcium levels, and second intervention was considered after 6 months (white diamonds, dotted lines).

The evolution of PTH (% from preoperative levels, a, or absolute values, b) and calcium (c) during minimal invasive parathyroidectomy at 13 patients where intraoperative (i-op) quick PTH and calcium were also measured from the ipsilateral internal jugular vein immediately after excision of the preoperative localized parathyroid adenoma. PTH and calcium were also measured in the peripheral blood the next day (postop), at 1, 3 and 6 months after surgery. Cure was considered when PTH dropped under 55 pg/mL and calcium decreased under 10.5 mg/dL. Quick PTH dropped with more than 50% from preoperative levels (preop) in 11 patients (black diamonds, continuous lines) and serum calcium decreased correspondingly. Long term PTH and calcium remained within the normal range 6 months after surgery and all 11 patients were considered cured. Quick intraoperative PTH did not drop in two patients (1 and 2, white diamonds and dotted lines). Minimal intervention was switched to open surgery, a second parathyroid adenoma being found and excised, accompanied by long term normalization of serum calcium and PTH in both cases and increasing success rate to 100%.



a - the distribution of cured patients (white bars) and patients with persisting high PTH levels after surgery or immediately after the excision of the parathyroid adenoma (groups C and iqPTH, respectively, black bars). No difference in the incidence of cure failure between the two groups at the intrasurgical time point was observed (non-significant chi-square test). b - the distribution of cured patients (white bars) and patients with persisting high PTH levels after surgery in both groups. Conversion to open neck surgery increased success rate to 100% in the iqPTH group (p < 0.05 when compared to the incidence of cure failure in the C group by the chi-square test).

Conclusions

- Preoperative localization of a solitary parathyroid adenoma has limited sensitivity, supplementary diseased parathyroid tissue being underdiagnosed
- Quick assessment of intraoperative PTH from the internal jugular vein is a reliable and fast method to attest or rule out cure. Assessment should be performed before wound suture.
- Persistence of high PTH after adenoma removal suggests multiple gland disease and indicates conversion to bilateral neck exploration, increasing cure rate.

Acknowledgements

This work was performed under the frame of European Social Fund, Human Resources Development Operational Programme 2007-2013, project no. POSDRU/159/1.5/S/136893