

PRIMARY ADRENAL LYMPHOMA: CASE REPORT

Márquez-Pardo R, Baena-Nieto MG, Cayón-Blanco M, García-García-Doncel L, López-Velasco R, Torres-Barea IM.

Departments of Endocrinology. Hospital de Jerez (Spain)

Introduction

Malignancy is an uncommon cause of adrenal incidentaloma in patients without a known diagnosis of cancer. The actual frequency of primary adrenal carcinoma in patients with adrenal incidentaloma is approximately 2 to 5 percent; another 0.7 to 2.5 percent have nonadrenal metastases to the adrenal gland. The presence of a nonadrenal primary tumor is exceptional and has been scarcely reported in medical literature.

Case report

We present a case of 71-year-old male who presented with fatigue, anorexia, weigh loss and hypotension. Initial laboratory evaluation didn't reveal any anormal result. Computed tomography (CT) scans of the abdomen and pelvis demonstrated large bilateral adrenal masses (the right adrenal gland measured 15x8.6x7 cm and the left adrenal gland measured 11.6x6.5x6 cm). The masses were nonfunctional according to hormone test results (cortisol of 270 mmol/l, ACTH level of 92.18 pmol/l, 24 h urinary level of normetanephrine 425 mcgr/day, metanephrine 148 mcrg/day). The laboratory test showed adrenal insufficiency (plasma cortisol of 267.62 nmol/l; cortisol failed to increase during the ACTH stimulation test (267.62 to 226.23 nmol/l) and ACTH was elevated (79.03 pmol/l). A CT-guided core needle biopsy of the left adrenal mass was performed and revealed diffuse large B-cell lymphoma. Bone marrow biopsy was negative for lymphomatous involvement. An F-18 fluorodeoxyglucose (FDG) positron emission tomography (PET) scan showed intense FDG accumulation in both adrenal glands (SUV 24.6), there was no abnormal FDG uptake in the rest of the body.

Figure 1

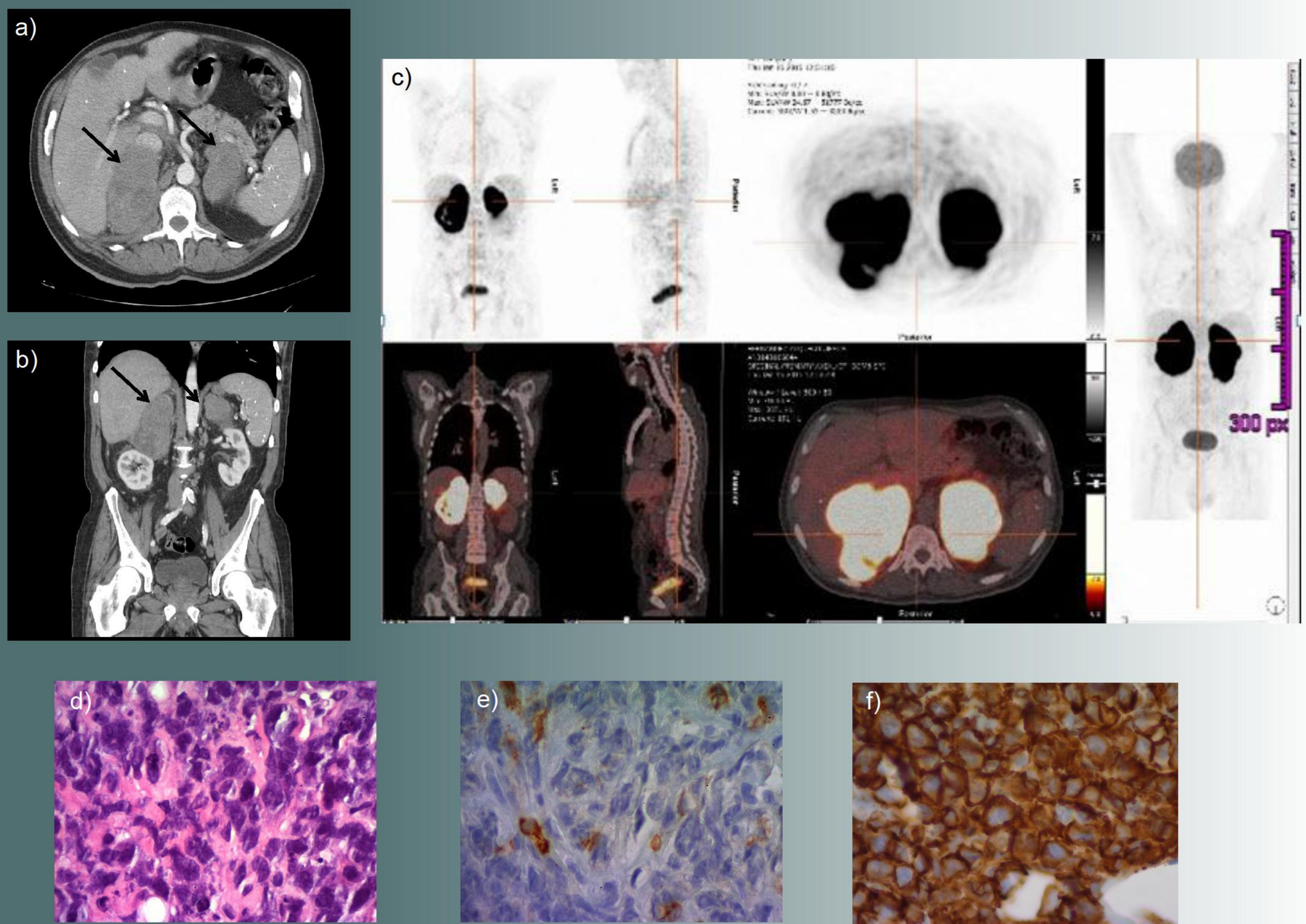


Figure 1. a), b) computed tomographic scan of abdomen showing bilateral adrenal gland masses. c) F-18 fluorodeoxyglucose (FDG) positron emission tomography (PET) scan showed intense FDG accumulation in both adrenal glands d), e), f), pathologic findings of adrenal biopsy. Lymphoid cells were diffusely CD20-positive.

Conclusions

Primary adrenal lymphoma is a very rare extranodal lymphoma, generally occurring among patients of advanced age (mean: 68 years) and dominantly in males. The most frequently histological type is diffuse large B-cell B lymphoma and is usually bilateral. Prognosis is poor. Treatment consist in chemotherapy regimens (the most common regimen is CHOP (rituximab, cyclophosphamide, doxorubicin, vincristine, and prednisone) and in some cases treatment with surgery and radiotherapy is necessary .

References:

- Vehbi, E, et al. Bilateral primary adrenal non-Hodgkin lymphoma. Turk J hematol 2014; 31:205-206.
- Wang J, Sun NC, Renslo R, Chuang C, Tabbarh HJ. Clinically silent primary adrenal lymphoma: a case report and review of the literature. Am J Hematol 1998;58:130-136.
- Rashidi A, Lo CY. Primary adrenal lymphoma: a systemic review. Ann Hematol 2013;92: 1583-93

