



# Clinical Utility of Adrenal Vein Sampling (AVS) in Primary Hyperaldosteronism (PHA) at a tertiary centre

D Lee<sup>1</sup>, U Pua<sup>2</sup>, D Wong<sup>2</sup>, L Quek<sup>2</sup>, S.A.K.K. Abdul Shakoor<sup>1</sup>

Department of Endocrinology<sup>1</sup>, Department of Diagnostic Radiology<sup>2</sup>, Tan Tock Seng Hospital, Singapore

## Objectives:

To identify the clinical usefulness of adrenal vein sampling (AVS) in lateralising adrenal pathology in patients with primary hyperaldosteronism (PHA)

## Methods:

Patients with PHA were identified from a list of patients who underwent AVS at our centre from April 2004 to October 2014. The diagnosis of PHA was established by biochemical criteria: Aldosterone renin ratio (ARR) >15 and/or positive normal saline suppression test. Biochemical criteria for successful cannulation on AVS was defined as ratio of peripheral over adrenal vein aldosterone-cortisol ratio >5. Images of the procedure were reviewed retrospectively by 2 independent radiologists who were blinded to patient's clinical presentation and findings on computed tomography (CT) of adrenal glands. Criteria for successful cannulation of the adrenal veins was based on angiographic evidence of adrenal tissue

Figure 1. Success of Cannulation Based on Radiological Criteria

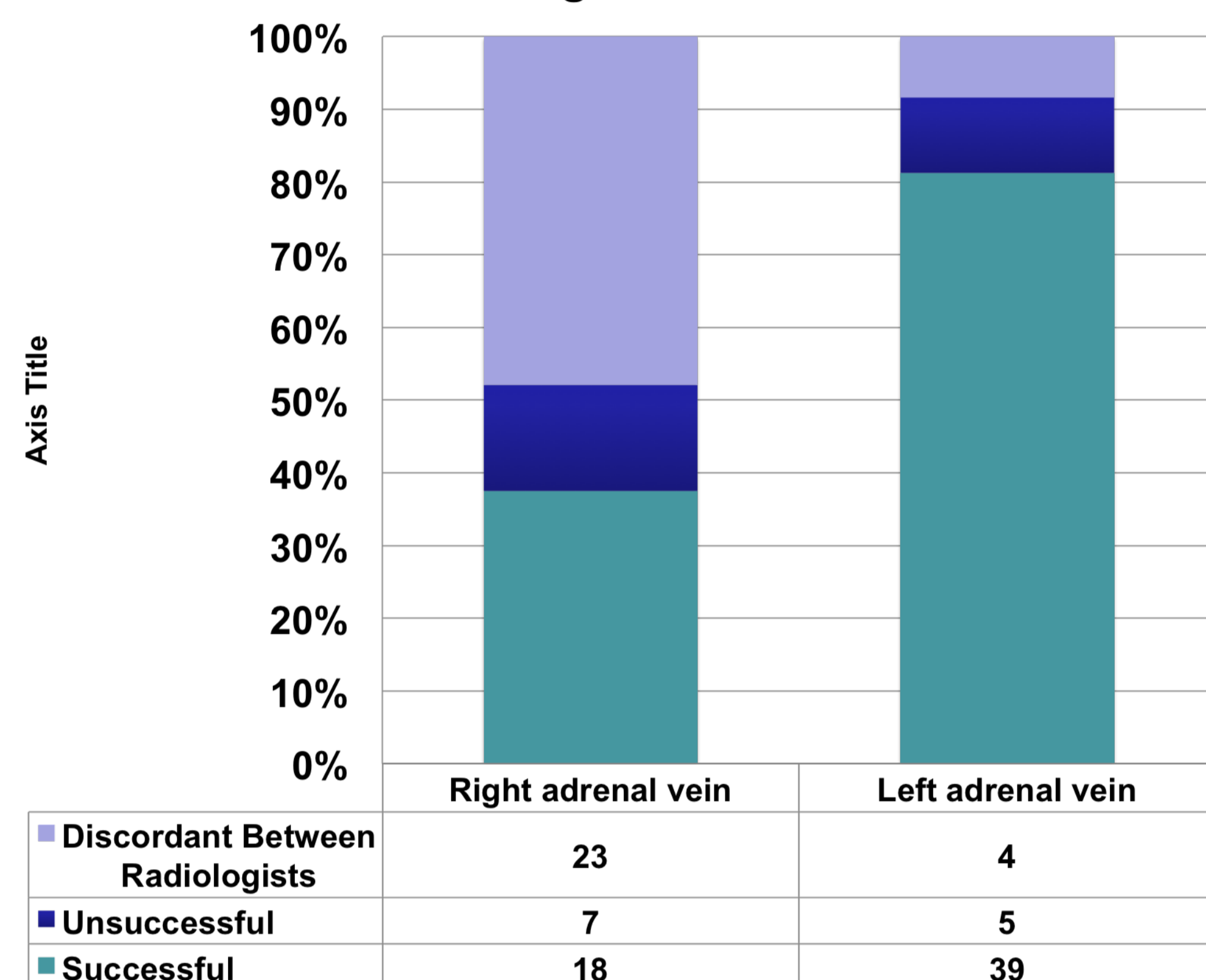


Figure 2. Physician's conclusion after AVS

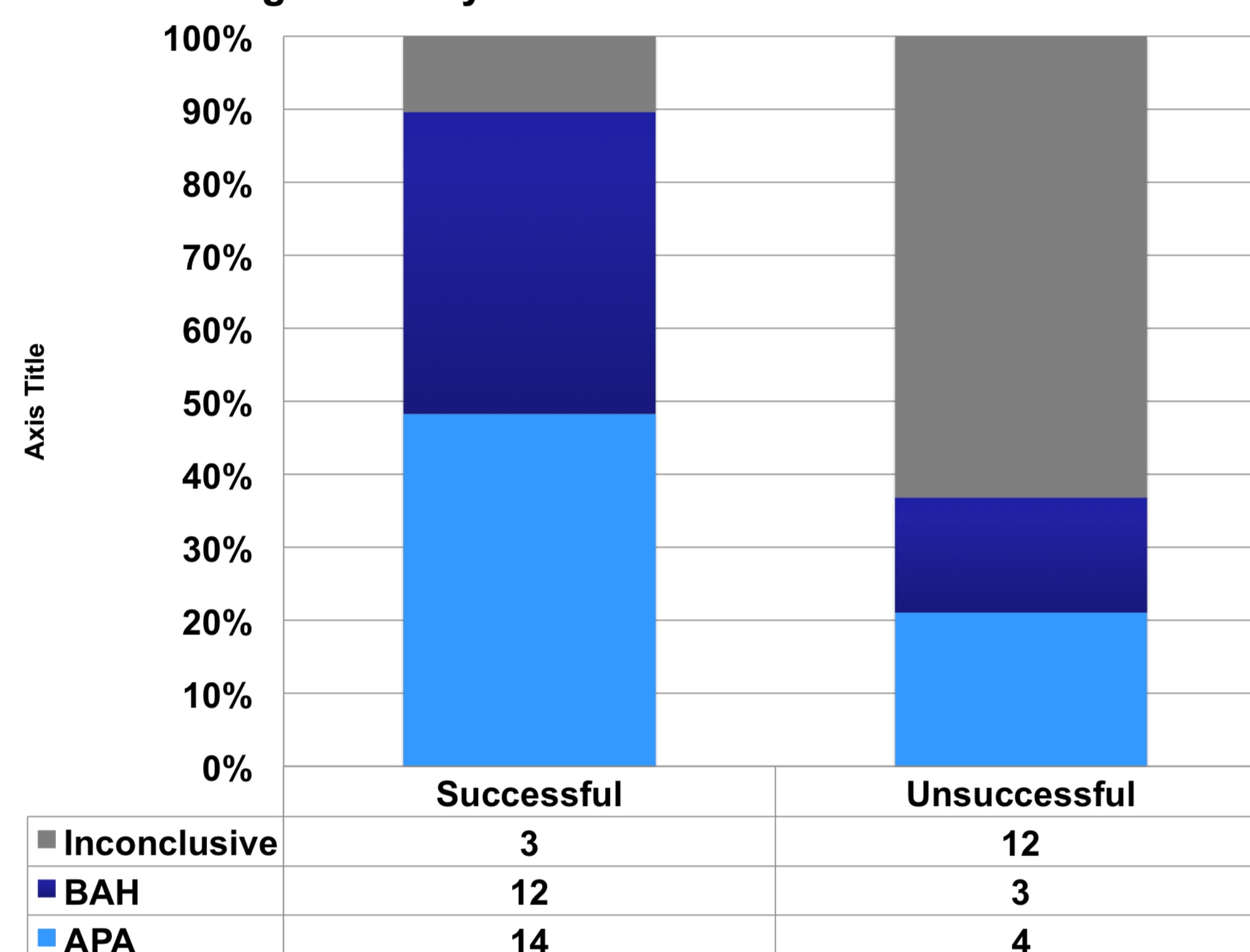
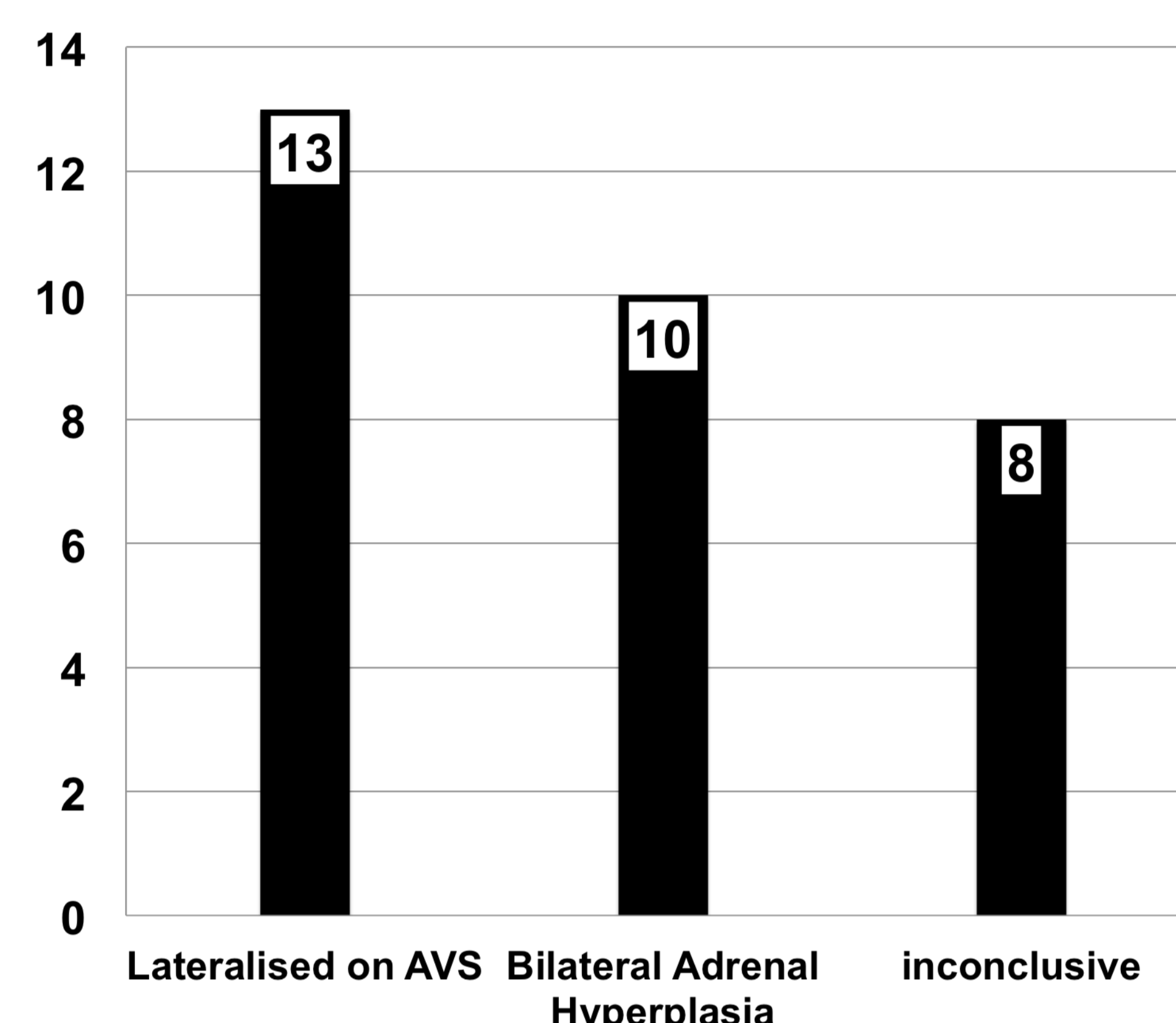


Figure 3. AVS Outcome of Patients with Unilateral Adrenal Nodule on CT



## Results:

- 45 PHA patients were identified over a 10-year period; 32 were male and 13 were female (mean age 50.3, SD 10.3 years). 33 patients were older than 45 years, 12 were aged 45 years or less.
- Adrenal CT findings were as follows: 31/45 (68.9%) unilateral nodule, 5/45 (11.1%) bilateral nodules, 7/45 (15.6%) no nodules, 1/45 (2.2%) bilateral bulky adrenals and 1/45 (2.2%) left adrenal limb thickening.
- 3 patients had repeat procedures as the first was inconclusive. All were given synacthen infusion during AVS.
- Based on retrospective radiological review, 29% (14/48) of cases were successfully cannulated bilaterally, 37.5% (18/48) were successful on the right and 81.3% (39/48) were successful on the left (see Figure 1). However there was substantial discordance in opinion regarding successful cannulation between radiologists, particularly for the right side; 48% (23/48) of cases vs. 8.3% (4/48) on left side (see Figure 1). There were 7/48 cases where both radiologists agreed was unsuccessful on the right side and 5/48 were unsuccessful on the left side (see Figure 1).
- Based on biochemical criteria, 59% (29/48) of cases were successfully cannulated bilaterally. Most of these were due to failed cannulation of the right adrenal vein (11/48 (22.9%)). 4/48 (8.3%) were due to failure on the left side and 4/48 were due to failure of cannulation on both sides. There was better agreement between radiology and biochemical criteria for the left compared to right; 77% (37/48) vs 37.5% (18/48).
- Out of 29 successful cases, 3/29 were inconclusive. 14/29 were aldosterone producing adenoma (APA) and 12/29 were bilateral adrenal hyperplasia (BAH). Of the 19 unsuccessful cases, 12/19 were deemed inconclusive by referring physician, 4/19 were concluded to be aldosterone producing adenoma (APA) based on secondary outcome and 3/19 were concluded to be bilateral adrenal hyperplasia (BAH), see Figure 2. A
- Among patients with unilateral adrenal nodule on CT, 9/31 (29%) lateralised on AVS to the same side as CT (see Figure 3). After employing secondary outcome criteria (assuming theoretically that aldosterone secretion should be suppressed on the side contralateral to an APA, plasma aldosterone cortisol ratio of the non dominant adrenal vein should be less than the peripheral vein), 4/31 (12.9%) lateralised on AVS to the same side as CT (see Figure 3). None of the patients lateralised to the opposite side. 10/31 (32.2%) patients with unilateral nodules on CT were found to have BAH after AVS (see Figure 3) and were successfully treated medically.
- Mean nodule size of unilateral nodules that lateralized on AVS was 1.42 cm, SD 0.44 cm while mean nodule size of unilateral nodules that did not lateralize on AVS was 1.07 cm, SD 0.25 cm, however the difference was not statistically significant. Nodules  $\geq 1.5$  cm predicted lateralisation to the same side in AVS with a positive predictive value of 70% compared to nodules  $\leq 1.5$  cm on CT. 4 patients with bilateral nodules and 1 patient with no nodules lateralised on AVS to one side and underwent successful adrenalectomy.

## Conclusions:

AVS provides more valuable information over CT in the management of PHA. In our series, AVS helped to save 10 patients (22.2%) from unnecessary surgery and directed 5 patients (11.1%) who would otherwise have been treated medically, for curative surgery; which appears to be comparable to published literature<sup>1</sup>. The rate for successful cannulation was lower in our cohort as compared to other centres<sup>1</sup>, possibly related to the expertise at our centre. Success rate of cannulation based on biochemical and radiological criteria was lower for the right adrenal vein compared to the left. Discordance between radiologists on success of cannulation as well as between radiological and biochemical criteria was also greater on the right side, thus reflecting the technical difficulty involved in cannulating the right adrenal vein.

## References:

- Young WF. Role for adrenal venous sampling in primary aldosteronism. *Surgery* 2004 Dec 136(6):1227-35

