

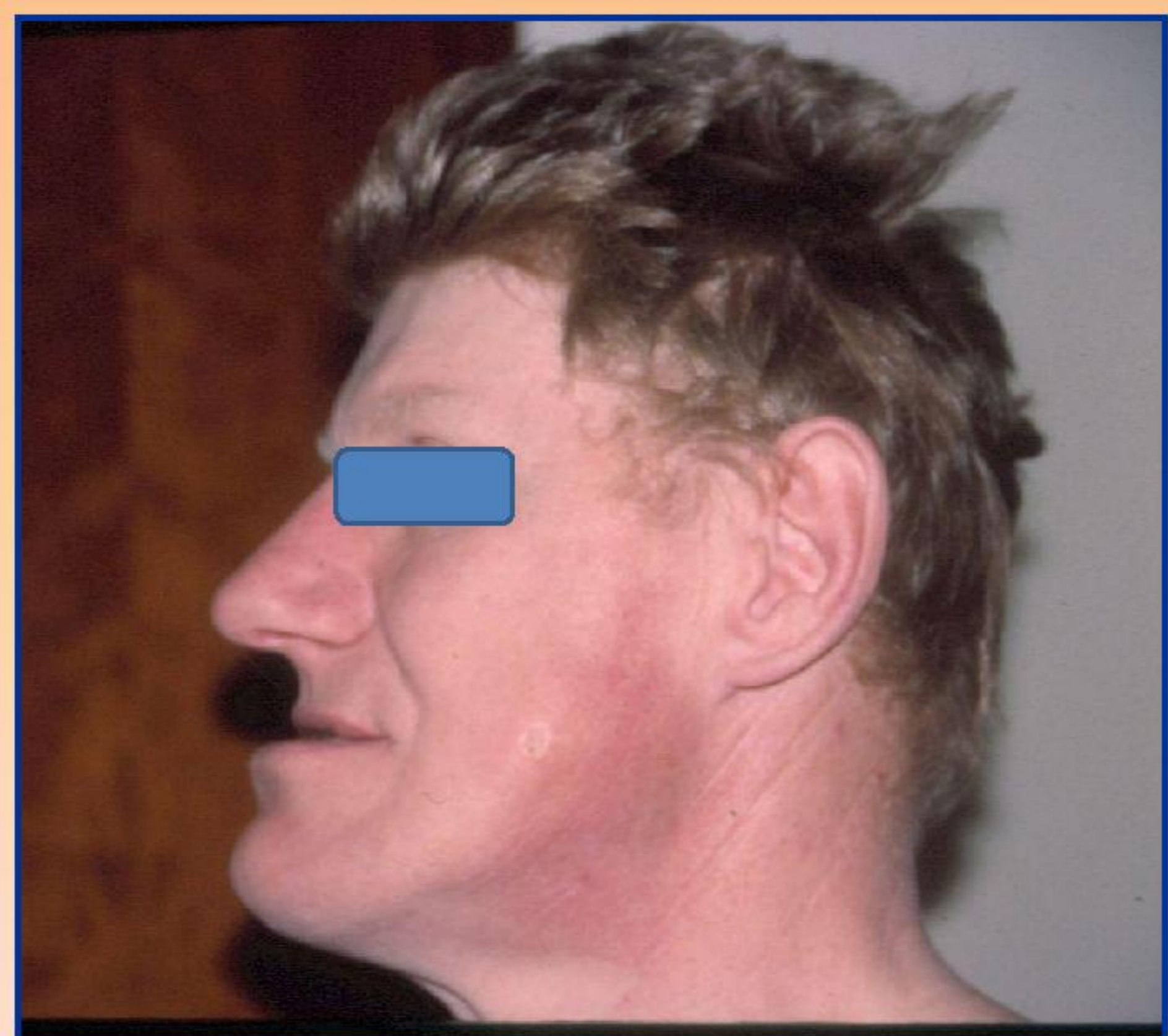
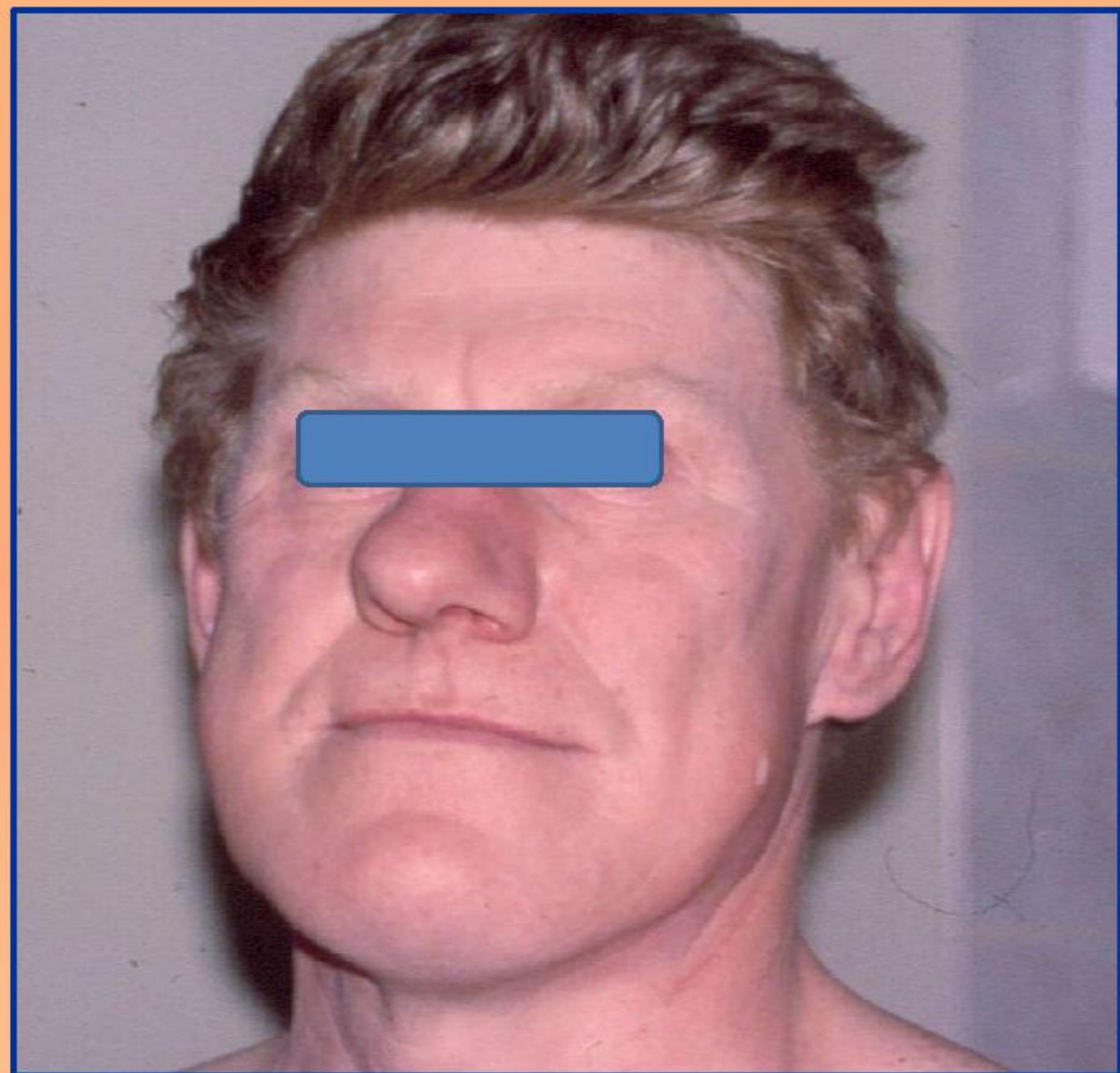
Persistent hyponatremia in patient with acromegaly, congestive heart failure and diabetes insipidus



Maria Kurowska, Joanna Malicka, Agnieszka Zwolak, Jerzy S. Tarach
Department of Endocrinology, Medical University, Lublin, Poland

Introduction. Increased production of vasopressin plays a key role in the development of fluid retention and hyponatremia in patients with decompensated heart failure. Antidiuretic hormone deficiency in the course of diabetes insipidus leads to the loss of water, dehydration and hypernatremia.

The aim of the study was to present difficulties in the successful treatment of hyponatremia in a patient with cardiomyopathy and heart failure, receiving desmopressin because of postoperative diabetes insipidus.



Case report. 70-year-old man with somatic features of acromegaly, after transsphenoidal surgery propter pituitary microadenoma (7.2 mm) before 12 years. Postoperative immunohistopathological examination showed mixed pituitary adenoma: ACTH(-); TSH(-); FSH (+); PRL (+); HGH (+). He developed postsurgical pituitary insufficiency requiring long-term substitution of hydrocortisone, thyroxin, testosterone and desmopressin.

Before the diagnosis of acromegaly, the clinical picture was dominated by symptoms of cardiomyopathy. After surgery there was an improvement of heart failure, lasting for about 8 years. 4 years ago the worsening of heart failure appeared with an increased atrial natriuretic peptide ranging from 701 to 2358 pg/ml. Between 2010-2011 the patient was hospitalized eight times in cardiological and endocrinological departments because of circulatory decompensation and severe hyponatremia (118-120 mmol/l).

Dilated cardiomyopathy was diagnosed with insufficiency of mitral valve III°, tricuspid valve III°, aortic valve II° and a congestive heart failure NYHA II/III. Substitution of adrenal and thyroid insufficiency was correct.

In October 2011, after a withdrawal of desmopressin, normalization of sodium levels in the blood and improvement of heart function persisting up to now were achieved.

Conclusion. An improvement of heart failure and normalization of blood natremia after the desmopressin withdrawal may suggest the regression of diabetes insipidus in our patient (12 years after an operation?), or, what is more likely, the beneficial influence of partial deficiency of antidiuretic hormone on reduction of the retention of body fluids and cardiovascular efficiency.

