

New onset sarcoidosis after remission of Cushing's syndrome

Zeynep Cantürk, Alev Selek, Serap Argun Barış, Berrin Çetinarslan, İlhan Tarkun, Zeynep Akyay

Kocaeli University Faculty of Medicine, Department of Endocrinology and Metabolism
Kocaeli University Faculty of Medicine, Department of Chest Medicine

OBJECTIVES

Glucocorticoids, even endogenous or exogenous, suppress the inflammatory response therefore they are the most preferred treatment options in inflammatory diseases. Persistent hypercortisolism induces lymphopenia and lymphoid tissue atrophy. Excessive endogenous hypercortisolism might mask the active inflammatory disease. Rebound immune modulation may occur after Cushing's syndrome (CS) remission, leading to the new onset of autoimmune diseases.

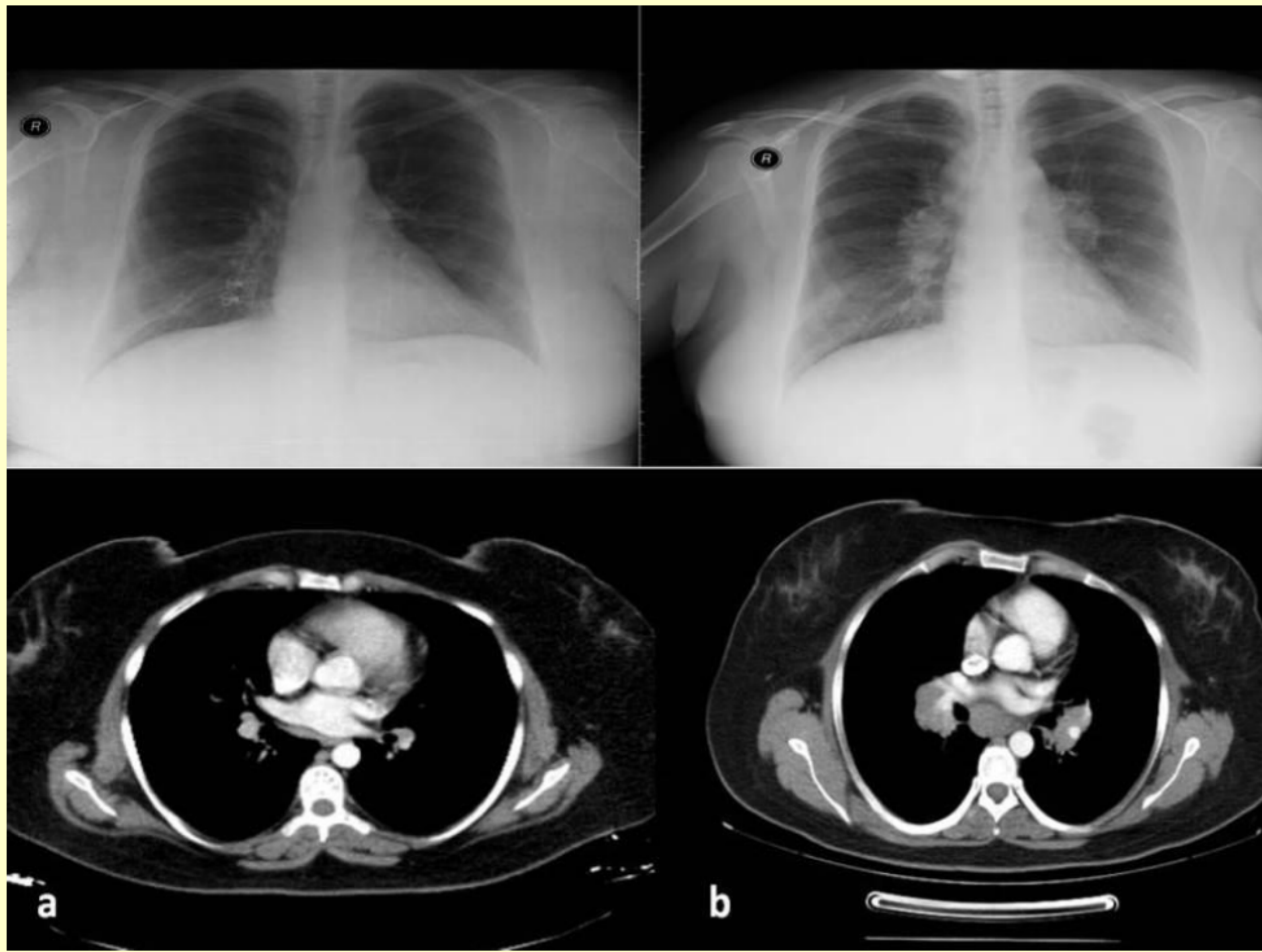
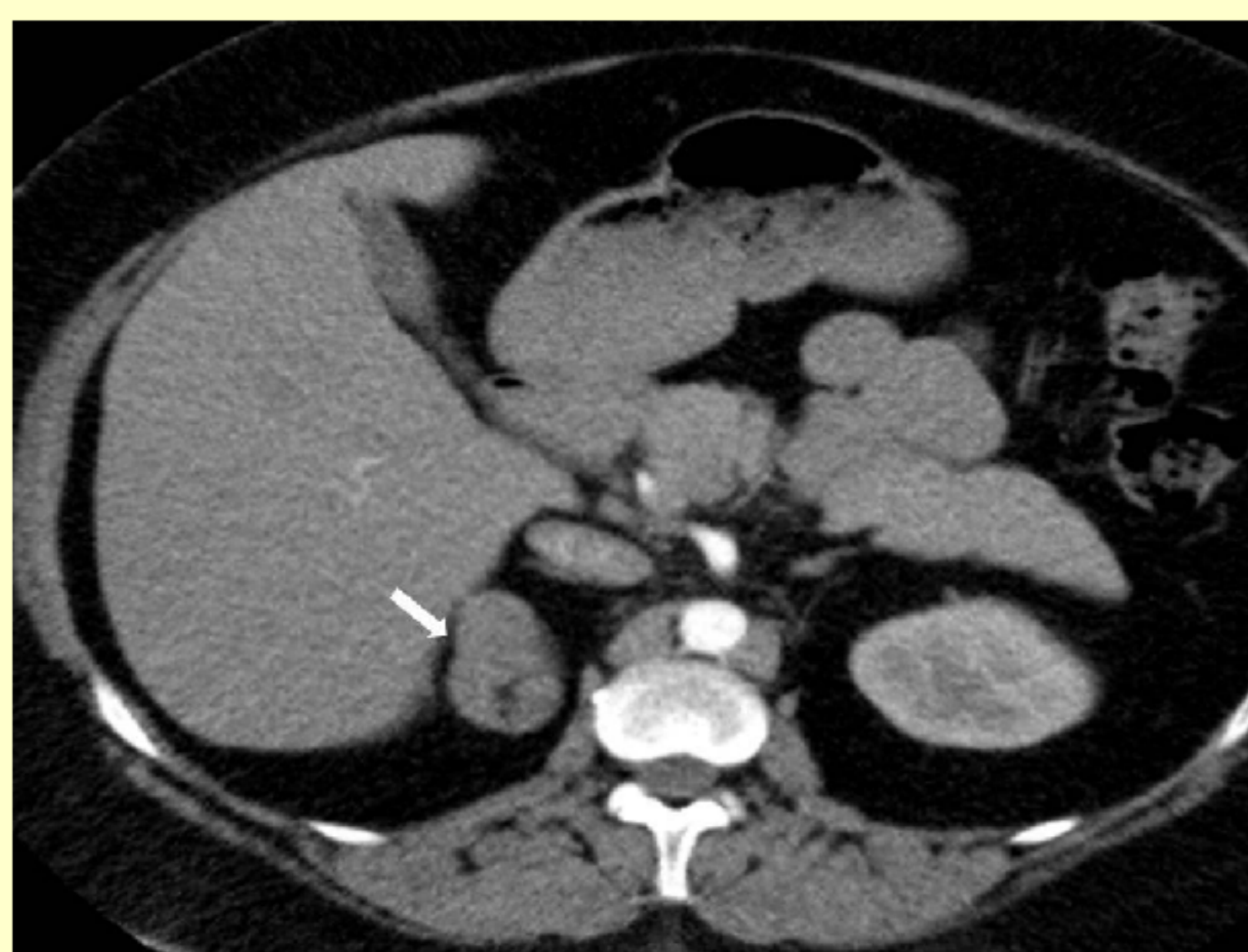

Figure: Plain chest X-ray and CT of the patient before (a) and after (b) the treatment of CS.



CASE

A 27 year old female admitted to our hospital with a right adrenal adenoma that is discovered during evaluation for right flank pain. She had a history of hypertension for 3 years and was complaining of 23 kg weight gain in two years. The patient was normotensive with valsartan/hydrochlorothiazide 160 mg/12,5 mg once daily, no history of hypertensive spells and other past medical history was unremarkable. On physical examination, she had moon face with facial plethotrea, buffalo hump, acne, abdominal obesity with BMI 32 kg/m², purple abdominal stria and easy bruising.

Laboratory evaluation revealed normal oral glucose tolerance test, complete blood count, liver and renal functions. Functional screening of the adrenal adenoma was performed in order to rule out Conn's syndrome, Cushing's syndrome and pheochromocytoma. 24 hour urinary free metanephrine and normetanephrine levels were in normal limits. Plasma aldosterone/ plasma rennin activity ratio was <20 with normal serum potassium levels. She had high midnight serum cortisol level with 14 ug/dL and the cortisol levels were not suppressed with two day 2 mg dexametasone suppression test. 24 hour free cortisol was four fold increased (1292 mg/d) and Cushing's syndrome (CS) was diagnosed. Basal ACTH levels were <5 pg/mL in three occasions reflecting adrenal dependent cause.

Plain chest x-ray and computerized tomography (CT) of the patient were normal (Figure 1a, 2a). Adrenal CT demonstrated right adrenal mass, 50 mm in diameter (Figure 3). It had clear margins in addition to its low density on CT which were indicative of an adenoma. The patient underwent right adrenalectomy with corticosteroid coverage. The post operative period was uneventful and she was discharged with corticosteroid replacement. The pathology of the adrenal mass was a benign cortical adenoma.

The corticosteroid treatment was reduced gradually and lasted at the end of 18. month. During the last dose decrement, she started to complain cough without sputum or fever. Physical examination of the respiratory system was normal. Chest x ray revealed bilateral hilar and right paratracheal enlargement (Figure 1b). There were bilateral hilar and mediastinal lymphadenopathies in thorax CT (Figure 2b). The biggest lymphadenopathy was nearly 3.5 cm in size at subcarinal region. The serum calcium level was in normal limits. The tuberculin skin test result was 0 mm in the scar positive BCG vaccinated patient. The level of serum angiotensin converting enzyme was increased. (178 U/L; normal range: 0-52 U/L). Carbone monoxide (CO) diffusion capacity (DLCO) was decreased (71%) while the pulmonary function test was normal. Fiberoptic bronchoscopy showed that main and right secondary carinas were edematous and the entry of the left upper lobe was narrowed by mucosal eudema. Bronchoalveolar lavage (BAL) and fine needle aspiration were taken. Flow cytometric evaluation of the bronchoalveolar fluid showed lymphocytic alveolitis (17.1%). CD4/CD8 ratio was 6.71. The histopathologic evaluation of the fine needle aspiration showed that there were noncaseous granulomas. Patient diagnosed with sarcoidosis after the clinic, radiologic and histopathologic evaluations.

CONCLUSIONS

Endogenous Cushing's syndrome is caused either by excess ACTH secretion or by autonomous cortisol release from the adrenal cortex. Glucocorticoids are the main endogenous mechanism to suppress the inflammatory response genes. Exposure to persistent hypercortisolism induces lymphopenia and lymphoid tissue atrophy resulting in immunosuppression. After treatment of CS rebound immunity occurs especially in patients with overt disease. In rare cases, the treatment of CS may result in unmasking or aggravation of diseases responsive to glucocorticoid medication such as thyroid, rheumatologic and allergic diseases Excessive hypercortisolism might suppress the active inflammatory stage of sarcoidosis. However, the disease became apparent after the reduction of cortisol levels following the treatment of CS.

References

- 1.Nieman LK, Biller BM, Findling JW, Newell-Price J, Savage MO, Stewart PM, et al. The diagnosis of Cushing's syndrome: an Endocrine Society Clinical Practice Guideline. *J Clin Endocrinol Metab.* 2008;93(5)
- 2.Da Mota F, Murray C, Ezzat S. Overt immune dysfunction after Cushing's syndrome remission: a consecutive case series and review of the literature. *J Clin Endocrinol Metab.* 2011;96(10):1670-4.
- 3.Doppman JL, Oldfield EH, Chrousos GP, Nieman L, Udelsman R, Cutler GB, et al. Rebound thymic hyperplasia after treatment of Cushing's syndrome. *AJR Am J Roentgenol* 1986;147:1145-4.Swearingen B, Biller BM, Barker 2nd FG, Katznelson L, Grinspoon S, Klibanski A, et al. Long-term mortality after transsphenoidal surgery for Cushing disease. *Ann Intern Med* 1999; 130:821-4.
- 5.Ntali G, Asimakopoulou A, Siamatras T, Komninos J, Vassiliadi D, Tzanela M, et al. Mortality in Cushing's syndrome: systematic analysis of a large series with prolonged follow-up. *Eur J Endocrinol.* 2013;169(5):715-23
- 6.Schaefer S, Meyer S, Brueck CC, Weber M, Lueddecke D, Wagner HJ, et al. Sarcoidosis following Cushing's syndrome: A report of two cases and review of the literature. *Exp Clin Endocrinol*

