

Successful treatment of huge pituitary macroadenoma secreting TSH and GH

Agnieszka Adamska, Agnieszka Zapora-Kurel, Maria Górska

Department of Endocrinology, Diabetology and Internal Medicine,
Medical University of Białystok, Poland



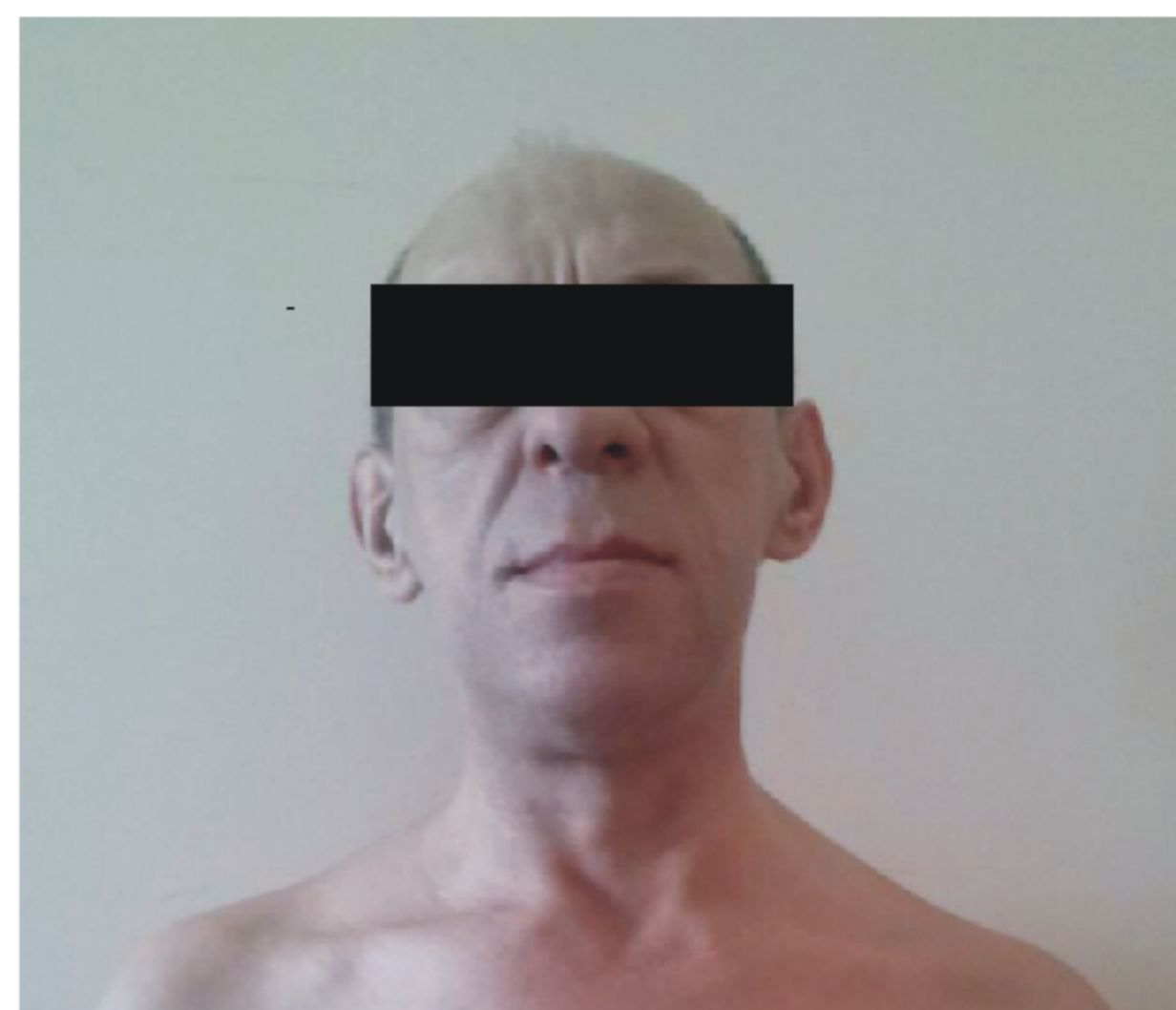
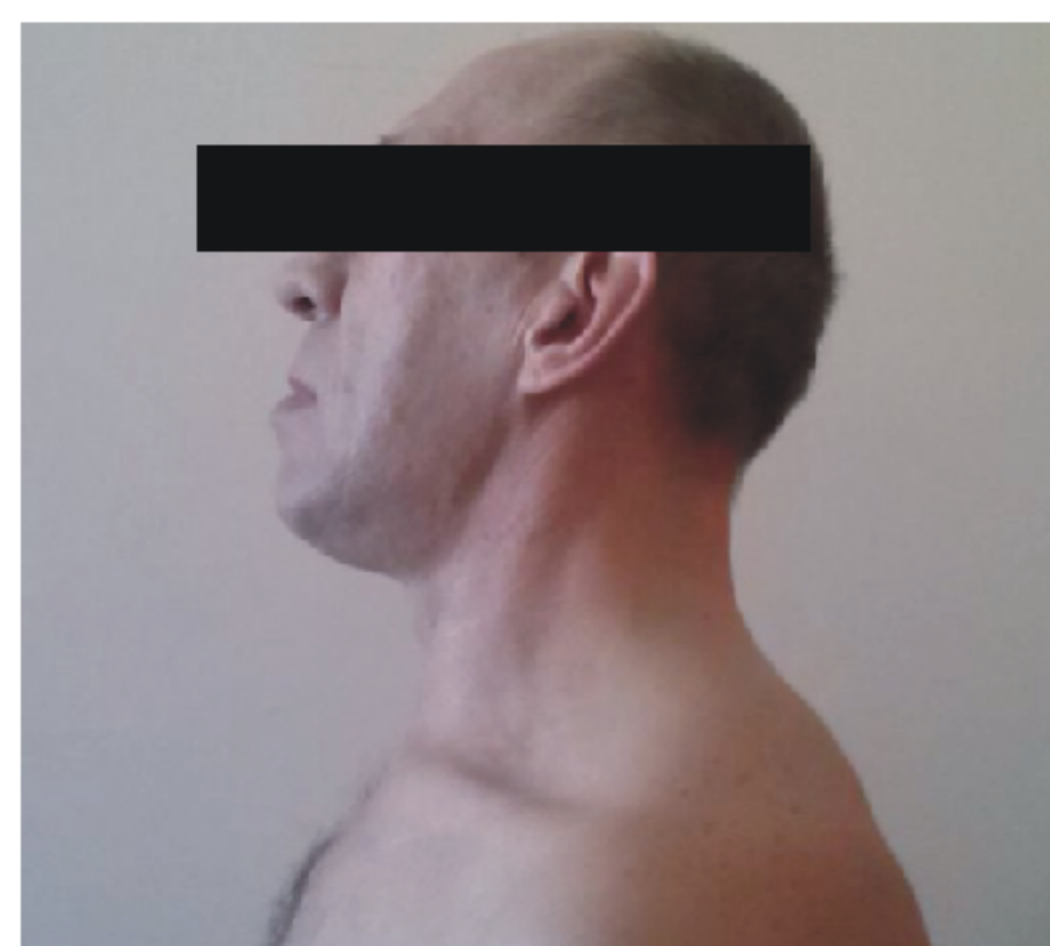
Introduction

The mixed tumor which secretes an excess of both GH and TSH causing acromegaly and hyperthyroidism is rare. The main problem is the late diagnosis, especially in men, even 10 years after the occurrence of the first symptoms.

Case presentation

Main complaints

A 53-year-old man, was admitted to our department in 13.01.2014, with complaints of excessive sweating, palpitation, headache, blurred vision and enlargement of the hands and feet.



Other tests

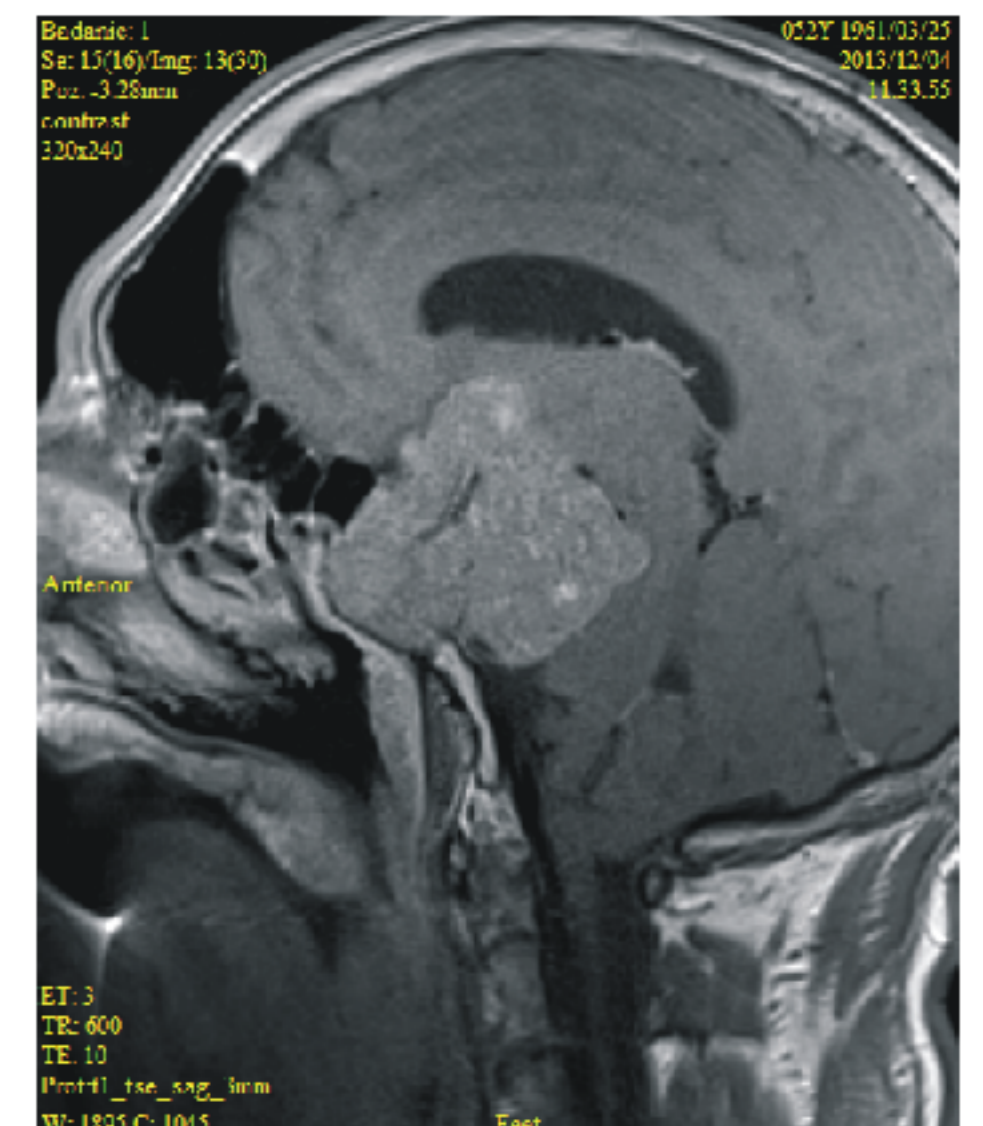
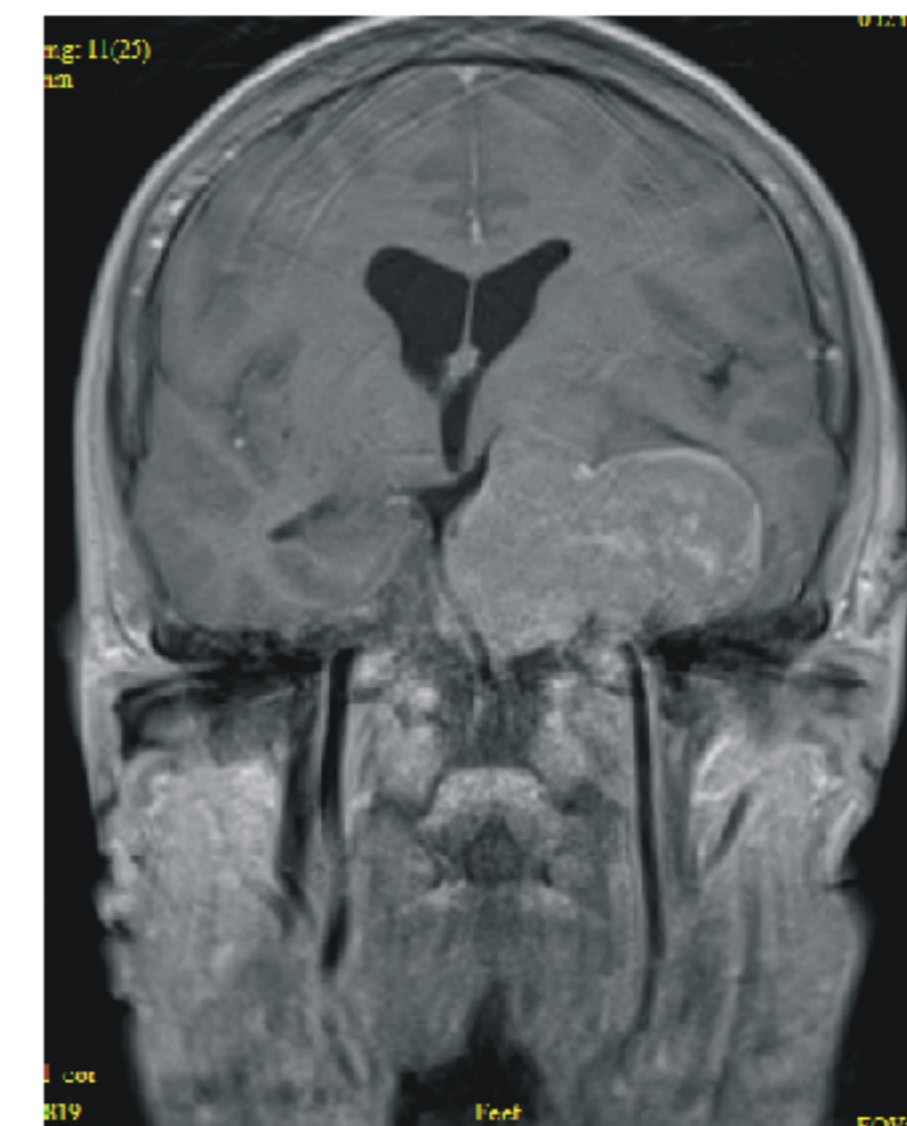
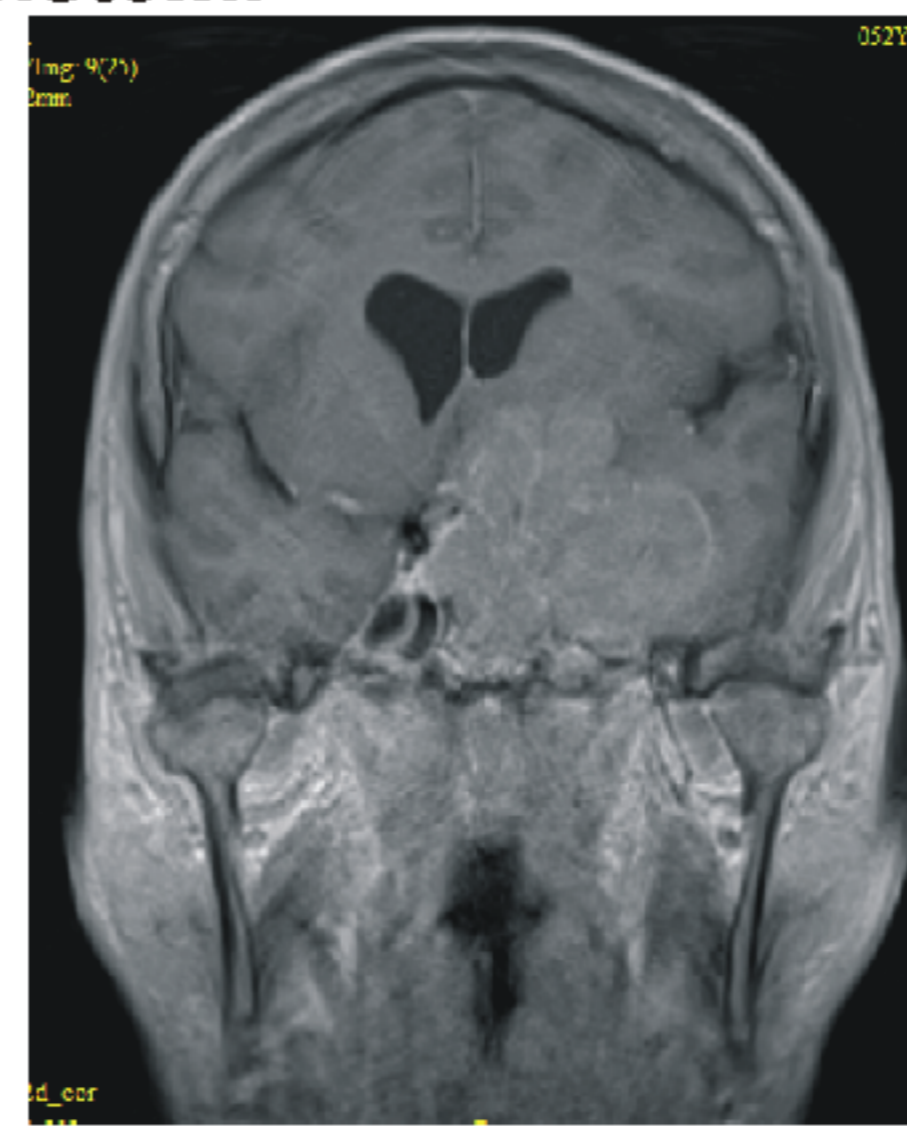24-h urine collection for cortisol (norm range to 176): 16.8 ug/24h

ACTH: 40.7 pg/ml

Test with ACTH (250ug cosyntropin)- cortisol 0'- 5.7 ug/dl, 30'-14.9 ug/dl, 60' 18.3 ug/dl

LH: 2.45 mIU/ml, FSH:2.92 mIU/ml

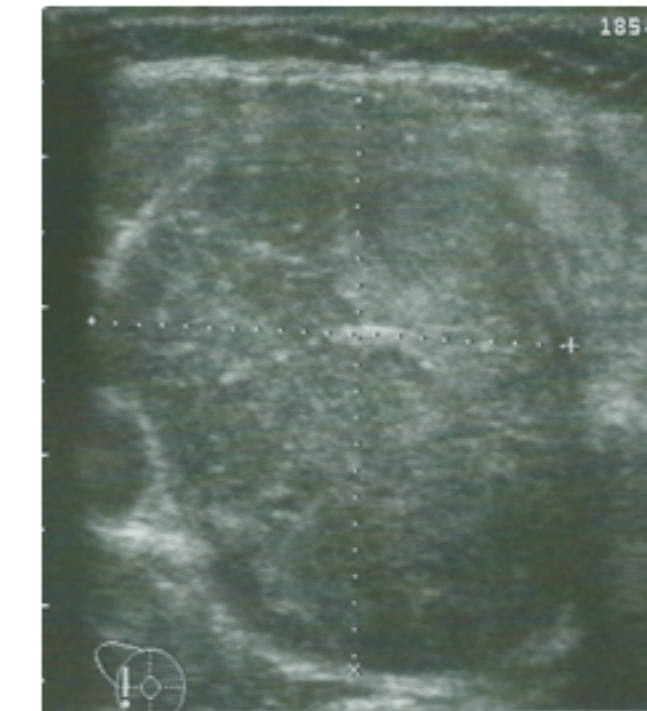
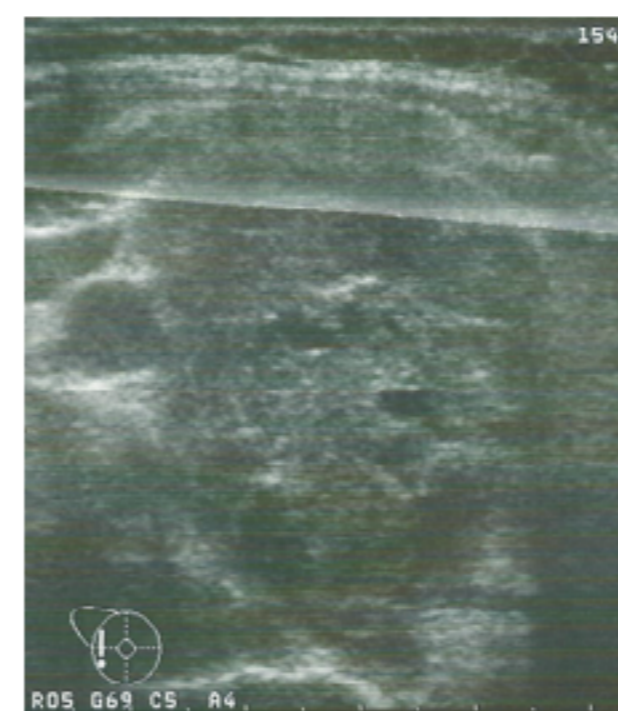Magnetic resonance imaging (MRI) of the sella revealed a large pituitary macroadenoma measuring 5 x 6 x 6 cm with left cavernous and sphenoid sinus invasion, with compression of the optic chiasm, the third ventricle as well as the brainstem.



Other investigation

Vision field revealed bi-temporal hemianopia.

USG of the neck:



History of presenting complains

Patient has noticed symptoms for the first time two years ago.

Past medical history

Past medical history revealed subtotal thyroidectomy 20 years ago.

Review of systems

His medical history included arterial hypertension.

Physical examination

Physical examination showed typical signs of acromegaly and nodules in both lobes of the thyroid gland.

Investigation

Initial laboratory testing revealed central hyperthyroidism (Table 1, 2) in addition to autonomic secretion of GH (Table 1).

Table 1

Test	Value	Normal range
GH (basal) (ng/ml)	7,2	(1-5)
GH (after 75g glucose) (ng/ml)	6.67	below 0.4
IGF-1 (ng/ml)	593	(87-267)
TSH (mIU/ml)	6.095	(0.35-4.94)
freeT4 (ng/ml)	3.09	(0.7-1.48)
freeT3 (pg/ml)	17.49	(1.45-3.48)
PRL (ng/ml)	79.52	(0-29)

Table 2

Test with TRH	Value
TSH 0'	3.6937
TSH 20'	6.9201
TSH 60'	6.0099
TSH 90'	7.0608
TSH 120'	5.1522

Treatment

1. Pre-operative treatment with thiamazole and octreotide LAR was initiated.
2. Patient proceeded to transsphenoidal resection of the pituitary macroadenoma (07.2014- first stage) with consecutive partial reduction of the tumor mass.
3. The left site temporal craniotomy (02.2015- second stage) with partial resection of the tumor has been performed. An improvement of vision and peripheral facial nerve paralysis on the left side was noticed after operation. After neurosurgery laboratory signs of hyperthyroidism resolved but serum GH concentration was still elevated. Currently, the patient is under octreotide LAR therapy.

Conclusions

We presented an unusual case with a huge pituitary macroadenoma secreting TSH and GH. Patient was successfully treated with transsphenoidal adenomectomy (at the first stage) and additional craniotomy with the partial resection of the tumor. This case showed that despite of symptoms and size of mixed tumor, diagnosis could be missed for the long time. On the other hand, the proper preparation for surgery, lets avoid the complications during the perioperative period.

