

DIPNECH: under-recognised and a diagnostic challenge

V. L. Salazar, B R. O'Driscoll, A.Mukherjee

Salford Royal Foundation NHS Trust
Salford, M6 8HD, U.K.

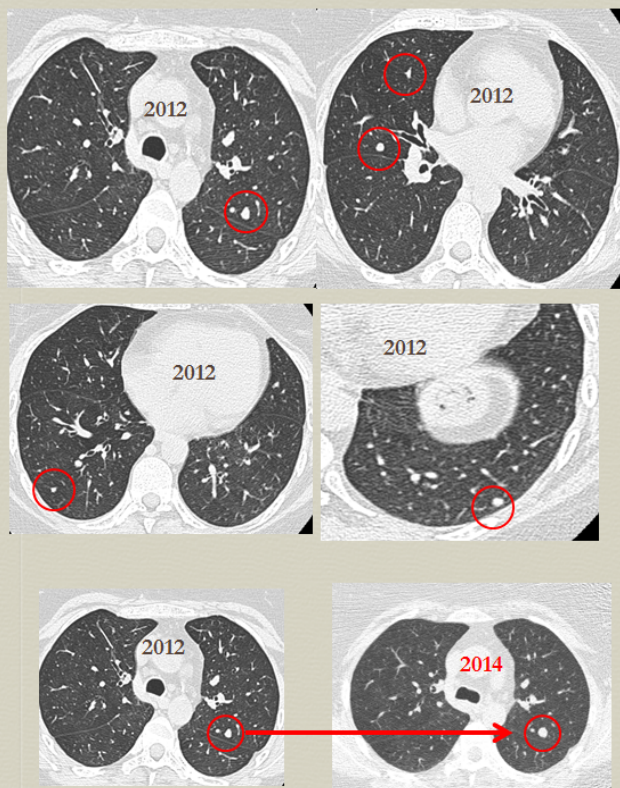
Case Report

A 48 year old non-smoking female was seen in the chest clinic for cough and breathlessness on a background of asthma type symptoms for 20 years. Her cough was exacerbated by inhalers, productive of yellow sputum and intermittent streaks of blood. On examination, her lungs were clear but she coughed almost continuously for five minutes after using her inhaler. CT Scan showed bronchiectasis with multiple small nodules scattered throughout the lungs ranging in size from 4-8mm. Subsequent scans over two years showed these nodules to have slightly increased in size. She remained extremely symptomatic with persistent cough despite steroid inhalers and mucolytics. She underwent video thoracoscopy which was converted to left thoracotomy to obtain a lung biopsy. The pathological findings were consistent with Diffuse Idiopathic Neuroendocrine Cell Hyperplasia (DIPNECH). She was referred to the Oncology service where she was treated symptomatically.

DIPNECH is a rare condition which is closely related to carcinoid tumours. Middle aged women represent 92% of cases and most are non-smokers. Symptoms include cough, dyspnea and wheezing. Imaging shows lung nodules and bronchiectasis. The histological appearance takes many forms comprising of generalised proliferation of scattered neuroendocrine cells, small nodules (neuroendocrine bodies) or a linear proliferation of pulmonary neuroendocrine cells superficial to the basement membrane. Extension beyond the basement membrane are termed tumourlets. Nodules >5mm in diameter are classified as carcinoid tumours.

Conclusion

DIPNECH is typically an indolent and non-progressive disorder although it may progress to carcinoid tumour. A patient presenting with persistent cough and wheezing with multiple nodules on CT scan should raise suspicion of DIPNECH. A "wait and watch" approach can be an option but studies have shown somatostatin analogues may improve respiratory symptoms and may lead to disease stabilization. However, surgical excision of dominant lesions should be undertaken if possible.



References:

- Nassar A, Jaroszewski DE, Helmers RA, Colby TV, Patel BM. Diffuse idiopathic pulmonary neuroendocrine cell hyperplasia: a systematic review. *American Journal of Respiratory Critical Care Medicine* 2011 Jul 1; 184 (1):8-16
- Davies S, Gosney J, Hansell D, Wells A, du Bois R, Burke M. Diffuse idiopathic pulmonary neuroendocrine cell hyperplasia: an under-recognised spectrum of disease. *Thorax* 2007; 62:248-252