

# Delayed diagnosis of Small bowel adenocarcinoma due to Thyroiditis induced thyrotoxicosis in a healthy young adult

Yu Ji Kim, Seol A Jang, Kyung Ae Lee, Heung Yong Jin, Hong Sun Baek, Tae Sun Park

Division of Endocrinology and Metabolism, Department of Internal Medicine, Research Institute of Clinical Medicine  
Chonbuk National University Medical School, Jeonju, South Korea

## INTRODUCTION

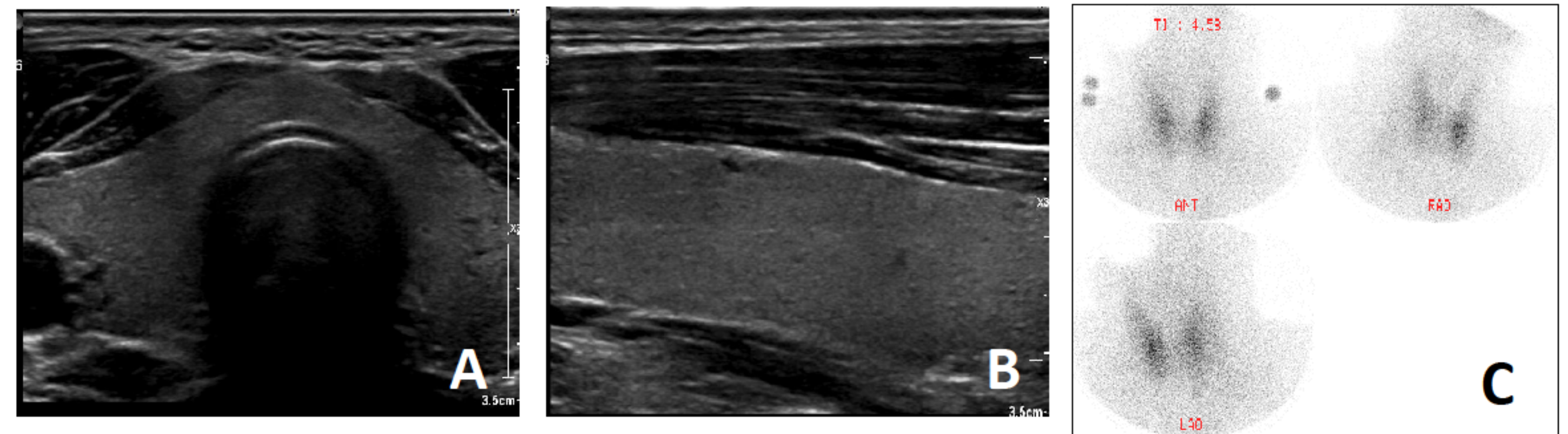
- Various systemic symptoms may occur in patients with thyrotoxicosis
- Gastrointestinal manifestations such as hyperphagia or frequent defecation, often coexist with other thyrotoxic symptoms. Vomiting also has been mentioned. In this setting, systemic symptoms of underlying malignancy may be confused with those of thyrotoxicosis leading to a delay in diagnosis.
- We report a case with delayed diagnosis of small bowel adenocarcinoma due to thyroiditis induced thyrotoxicosis in a healthy young adult.

## CASE REPORT

- A 22-year-old man presented with palpitation, vomiting and 10 kg weight loss over the past 1 month. About 3 months before visiting our hospital, the patient reduced the weight about 10 kg through diet and exercise.
- The patient had no proptosis, eyelid lag, the thyroid gland was not palpable, and no tenderness or rebound tenderness was found in the epigastrium.
- Laboratory examinations revealed low level of TSH, elevated free T4 level, hyponatremia and hypokalemia. Serum antibodies to TSH-receptor and thyroid peroxidase were negative (Table 1).
- Tc-99m thyroid scan was performed and uptake was decreased in both thyroid lobe (Figure 1). The patient was diagnosed with thyroiditis induced thyrotoxicosis.

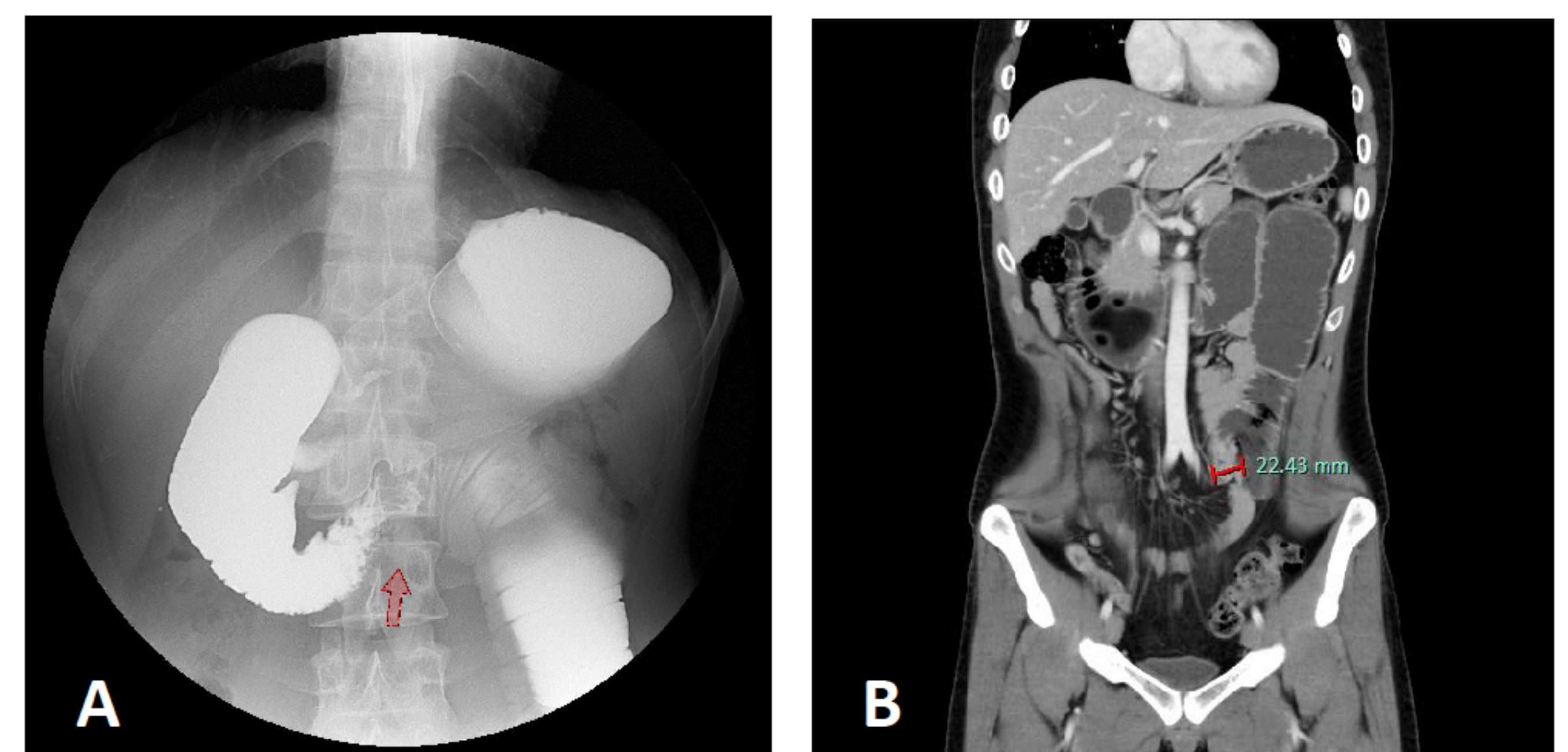
**Table 1.** Anthropometrical characteristics of the patient upon admission to hospital

On admission			
WBC ( $\times 10^3/\mu\ell$ )	16.70	ESR (mm/hr)	16
Hb (mg/dL)	13.5	hs-CRP (mg/L)	17.21
Serum sodium (mmol/L)	121	TSH (uIJ/mL)	0.039
Serum potassium (mmol/L)	3.3	Free T4 (pmol/L)	43.28



**Figure 1.** (A)(B) Transverse and longitudinal sonographic images of the thyroid showed mild hypoechogenicity, fine echotexture, an AP diameter from 1 to 2 cm, normal vascularity (C) Thyroid scan (99m-Tc) revealed an normal size of thyroid with decreased radiotracer uptake

- At the initial approach, the symptoms of patient including nausea and vomiting were considered uncommon thyrotoxic manifestations. However, vomiting was not improved despite symptomatic treatment
- Upper gastrointestinal series and computed tomography of abdomen revealed slow passage of contrast media and narrowing of small bowel with upstream dilatation due to small bowel mass (Figure 2).



**Figure 2.** (A) Upper gastrointestinal series showed slow passage of contrast media and narrowing of small bowel with upstream dilatation (B) Computed tomography of abdomen revealed an about 2cm sized, irregular mass in the proximal jejunum

- He underwent small bowel segmental resection. The pathology reported adenocarcinoma of proximal jejunum.

## CONCLUSIONS

- This case highlights the importance of a comprehensive clinical history and examination for all patients presenting with thyrotoxicosis.