

Parathyromatosis following endoscopic parathyroid surgery: A rare case report

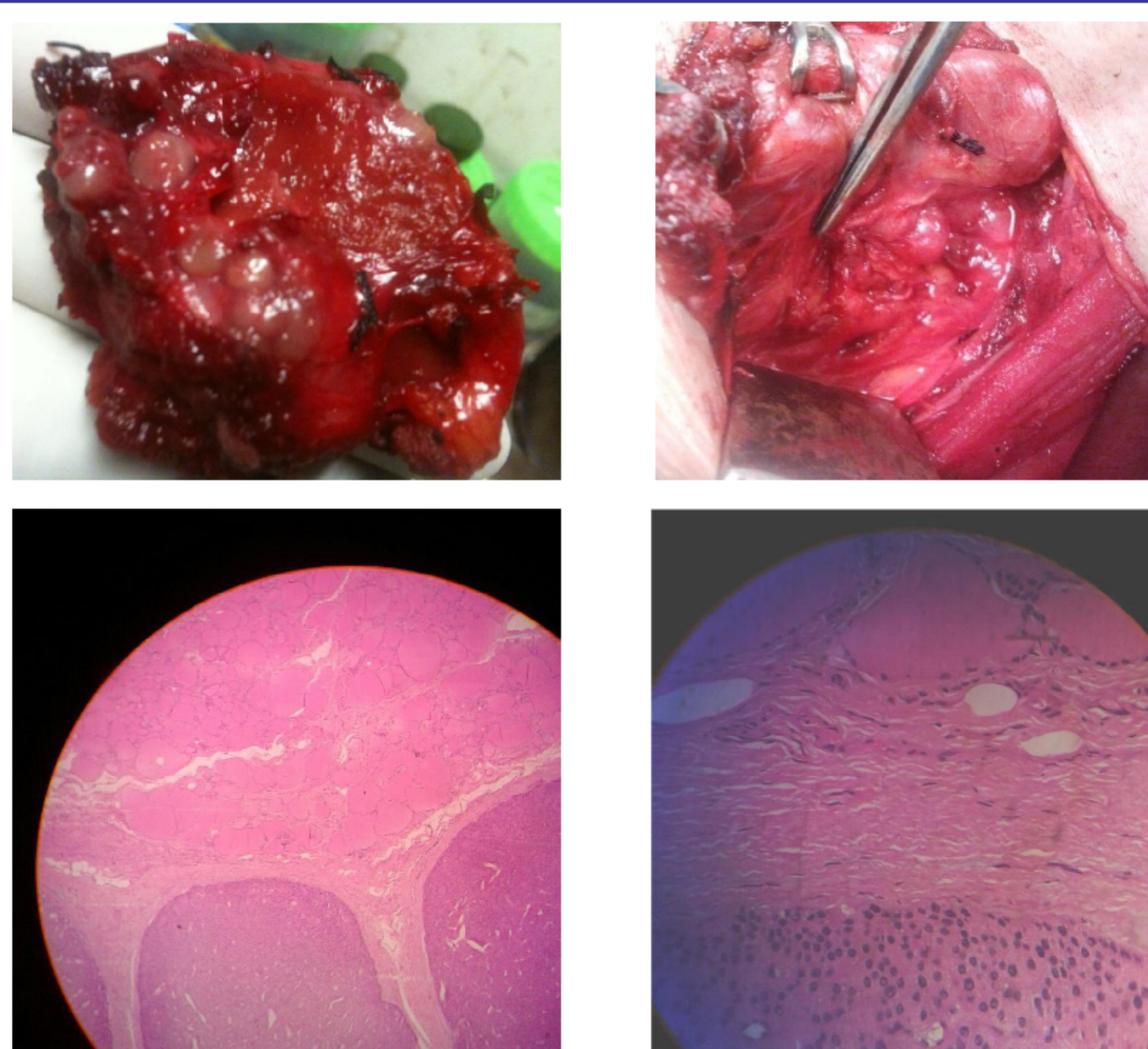
Ajay Aggarwal DM, Vivek Aggarwal*Mch, Roopak Wadhwa DNB, Rajeev Khanna DM

Department of Endocrinology and Endocrine Surgery*, Fortis Hospital, Shalimar Bagh, New Delhi (India)

Introduction

- Parathyromatosis, a rare cause of recurrent hyperparathyroidism, consists of ectopic hyper-functioning parathyroid tissue scattered throughout the neck
- Two forms of parathyromatosis have been reported, type1 due to hyperplasia of parathyroid rests from embryological development and type2 occurs due to spillage, seeding of parathyroid tissue during parathyroid surgery
- Repeated surgery often is necessary. Preoperative diagnosis is rarely made, may be due to lack of awareness of entity

Gross and histopathological findings



Case History

A 55-years old male presented with bony pains and nausea for 1 year. He had focused left superior endoscopic parathyroidectomy done 2-years back for adenoma

Physical examination: Unremarkable

Laboratory Investigations: The reports were suggestive of recurrent hyperparathyroidism (Table)

Imagings: Ultrasonography, MIBI and PET scans failed to localise lesion. Possibilities of incomplete removal, hyperplasia, multiple/ectopic adenoma, malignancy and parathyromatosis were considered.

On exploration: Multiple nodules (< 5mm) were found in the left side neck compartment embedded in strap muscles, sternocleidomastoid, thyroid surface and left central compartment. Opposite parathyroid glands were normal. The surgical procedure included left hemithyroidectomy, removal of ipsilateral straps, parts of sternocleidomastoid, berry picking of superficial nodules and clearance of tissue close to entry of ports

Post-op laboratory results: Showed serum calcium 2.4 mmol/l and undetectable PTH levels (<2.5ng/l)

Histopathological findings: Multiple small hypercellular parathyroid glands along with normal looking thyroid follicles s/o parathyromatosis

Discharge plan: Patient was discharged on oral calcium and vitamin D supplementation

Follow up: After 1-year serum calcium is normal

Laboratory Investigations

December 2010

- S.Calcium: 4.1 mmol/l
- S.Phosphorous: 0.58 mmol/l
- S.Albumin: 33 gm/l
- S.ALP: 1631.7 IU/l
- S.Creatinine: 88.4 µmol/l
- S.PTH levels: 1982 ng/l

January 2013

- S calcium: 3.5 mmol/l
- S.Creatinine: 97.24 µmol/l
- S.ALP: 446 IU/l
- 24 hours urinary calcium: 16.24 mmol/ 24 hrs
- 24 hours urinary creatinine: 1.4 gm/24 hrs
- Calcium creatinine clearance ratio: 0.024
- PTH: 1400ng/l

Conclusions

This is first case report to show parathyromatosis occurring following endoscopic surgery for benign parathyroid adenoma. Surgical cure is often unsuccessful as it is difficult to identify and remove all the disseminated tiny nodules of parathyroid tissue. So, Utmost care should be taken to avoid parathyroid spillage during surgery and every effort should be made to not rupture parathyroid capsule, even of benign tumour of the gland

References

1. A Mohammadi et al- Parathyromatosis or recurrent multiple parathyroid adenomas? A case report. J Clin Med 2012;7(1): 66-69
2. A Aksoy-Altinboga et al- Parathyromatosis: Critical diagnosis regarding surgery and pathologic evaluation. Kor J Path 2012;46:197-200
3. M P Hage et al- Parathyromatosis: A rare yet problematic etiology of recurrent and persistent hyperparathyroidism. Metab Clin and Exp 2012;61: 762-775

