

Ectopic Thyroid of young child with severe dysphagia: a surgical indication.

M S Merad¹, Z. Benzian¹, F. Mohammedi¹, A. Benouis².

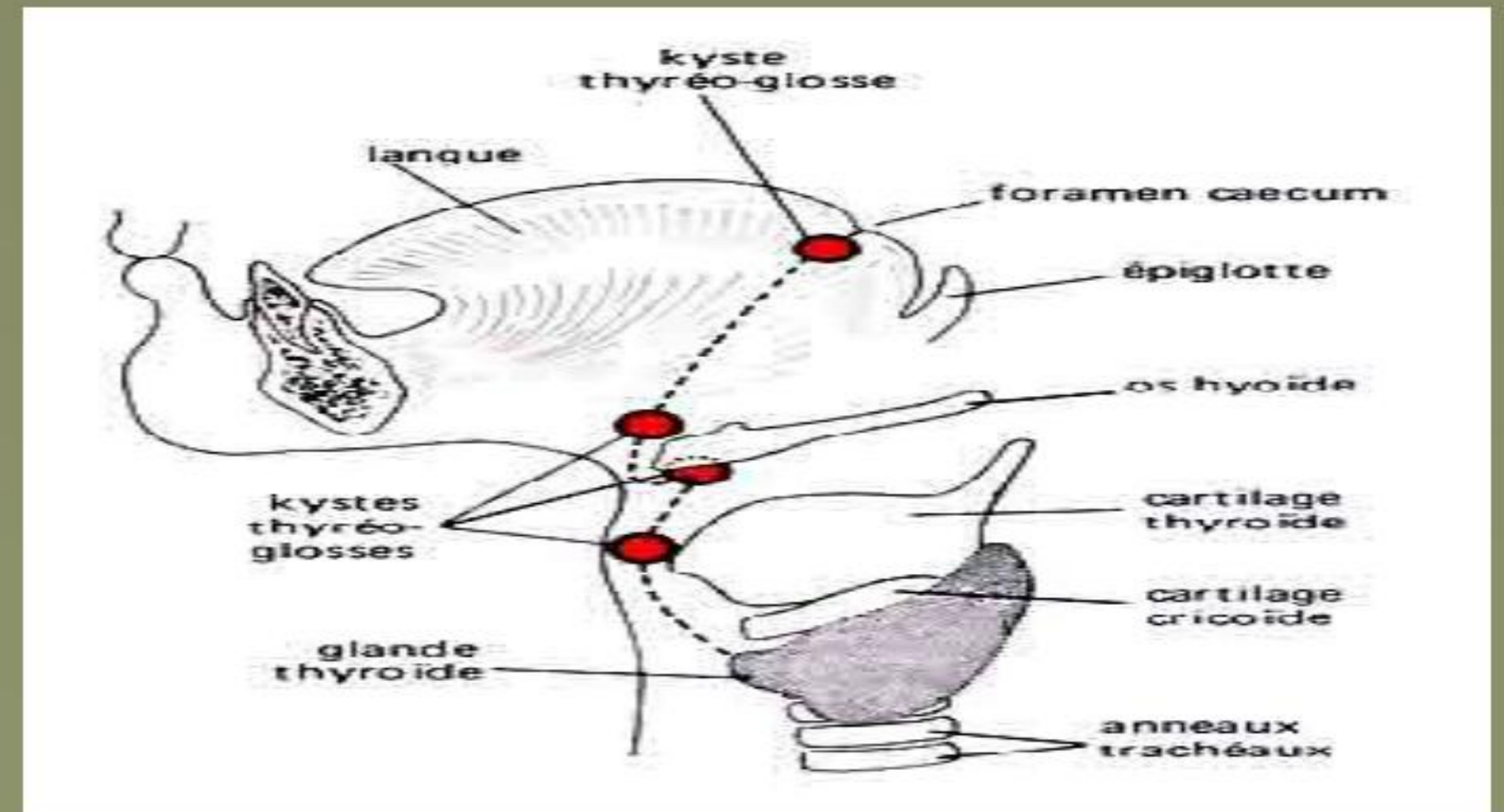
(1) Endocrinology and Diabetology Service -Laribere Clinic –university Hospital Dr Benzerdjeb Oran (Algéria).

(2) Biology Laboratory of Developmental and Differentiation university ES-Senia Oran(Algéria).

Introduction

The incidence of lingual thyroid is estimated to occur in one of 3,000 to one of 200,000 and is reported as being four to eight times more common in females. The lingual thyroid is a rare developmental anomaly that occurs following the failed caudal migration of the thyroid gland from the ventral pharynx to the normal pretracheal position in the neck. The pathogenesis of this event is currently not known.

Many patients are asymptomatic but some report complaints secondary to anatomic obstruction of the oropharynx including dysphagia, dysphonia, dyspnoea and haemoptysis. We present a child patient with a lingual thyroid resulting in severe dysphagia that was cured surgically.



Case report

An 4-year-old male child presented to our department for failure to thrive estimate at less 2 DS. He present a severe dysphagia to food, some episodes of transitional dyspnea and hypothyroidism treated since 1 year with lévothyrox.

The examination finds a child with a delay staturale of (- 3SD), a delay ponderal of (- 2SD), a good development psychomotor and a normal pubertal development.

We do not find true signs of dysthyroïdie but we note episodes iterative of dysphagie has every meal relate by the mother; neck's examination revealed no palpable thyroid gland in the normal pretracheal position, no cervical adenopathy an normal oral cavity.

Blood tests

TSHus	> 100 µUI/l	CALCEMIE	93,95 mg/l
FT4	7,89 pmol/l	POHOSPHOREMIE	50.05 mg/l
AC TPO	72 UI/l	PTH	15 pg/ml
TG (THYROGLOBULINE)	465,4 ng/ml	UREE	0,15 g/l
BASIC CORTISOL	759 nmol/l	CREATININEMIE	5 mg/l

Bone age

Estimation is 2 years old
According to the method of Greulich

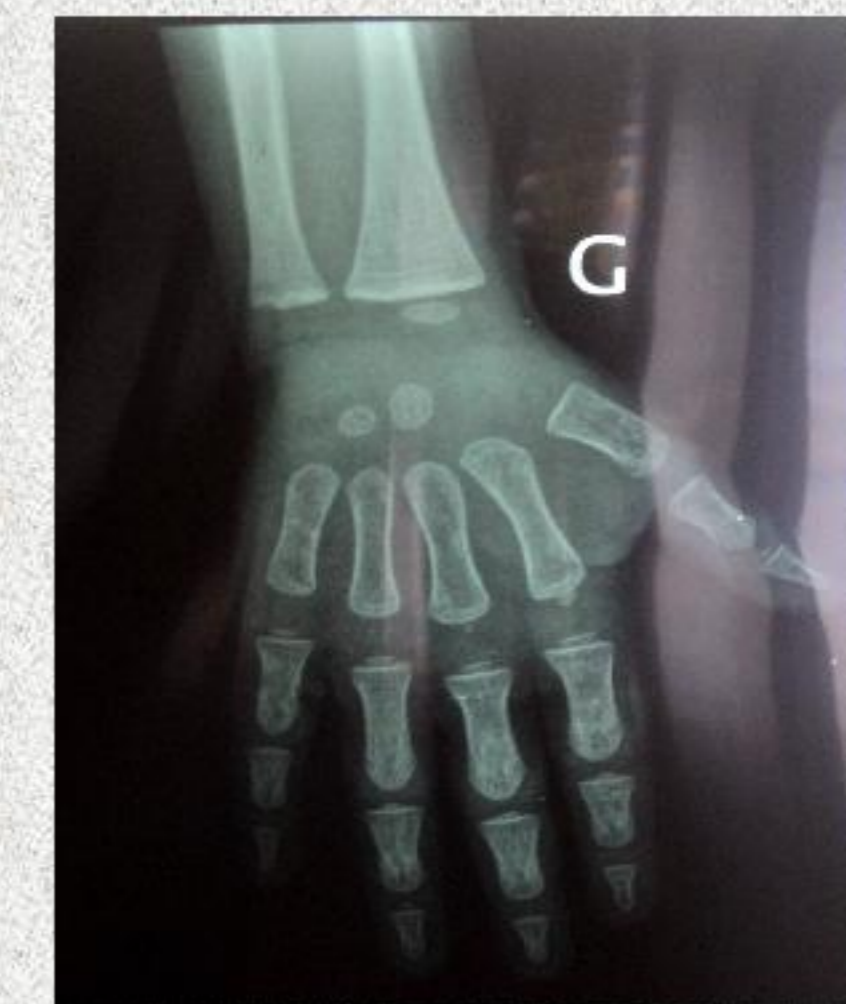

fig-1

ULTRASOUND THYROID

Shows no thyroid, an homogeneous and echogenic median high cervical mass (between 2 salivary glands) ovale bilobate measuring 22,7 mm in length on 6,84 mm in thickness without discernible

Oeso- gastroduodenal fibroscopy

no visualized obstacle

The thyroid scintigraphy

with 99mTc-Perthchnetate showed an uptake region at the base of the tongue representing a lingual thyroid. There was no thyroid uptake in the usual site in the neck

fig-2

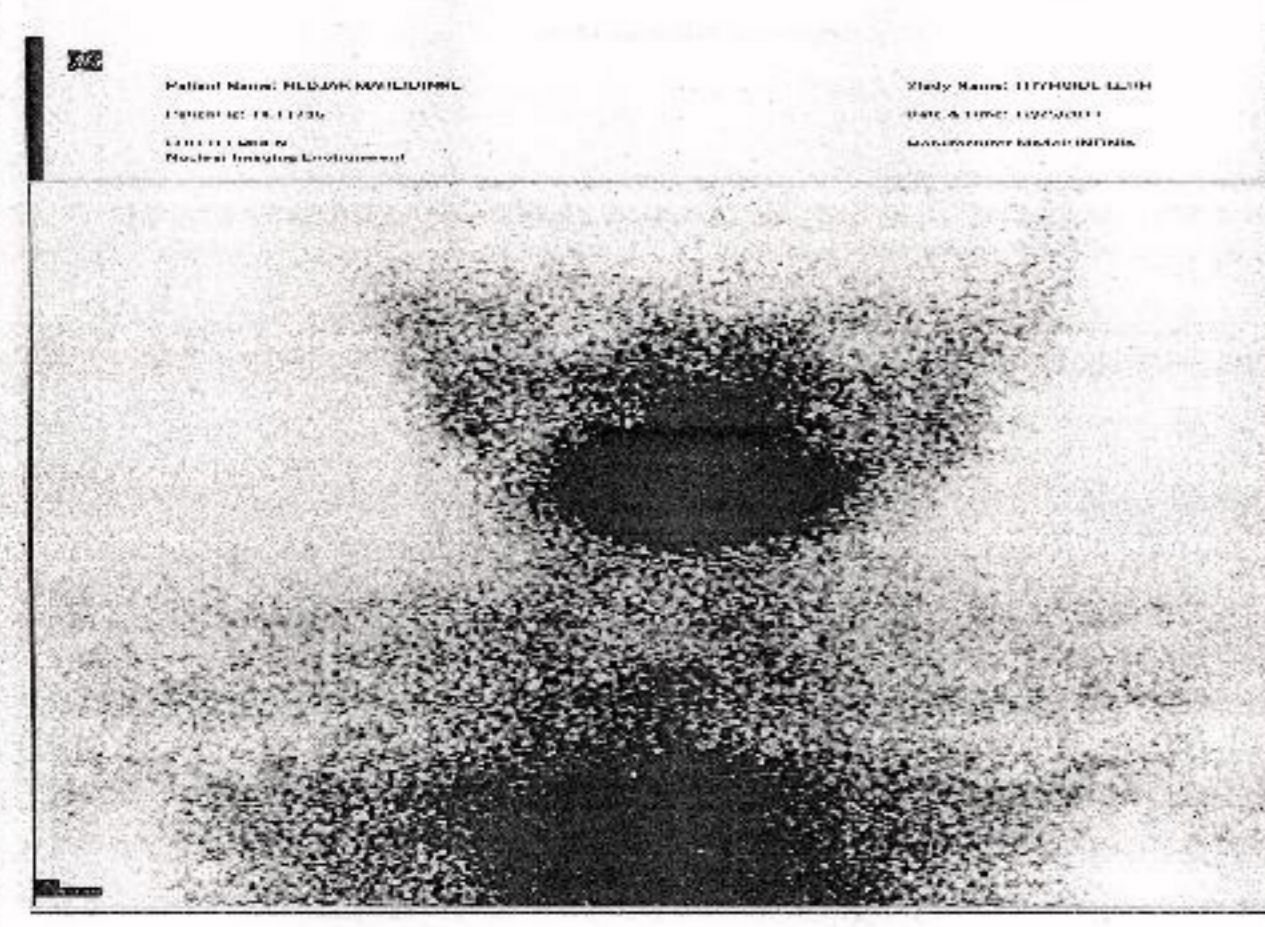


fig-2

Computed tomography scan

tissue density formation sit at sub median lingual soft parties, measuring 07 / 09mm with enhancement after injection contrast medium in an intense and homogeneous way in the contact of the bone hyoïde with small picture of bony erosion. thyroid empty houses.

fig-3

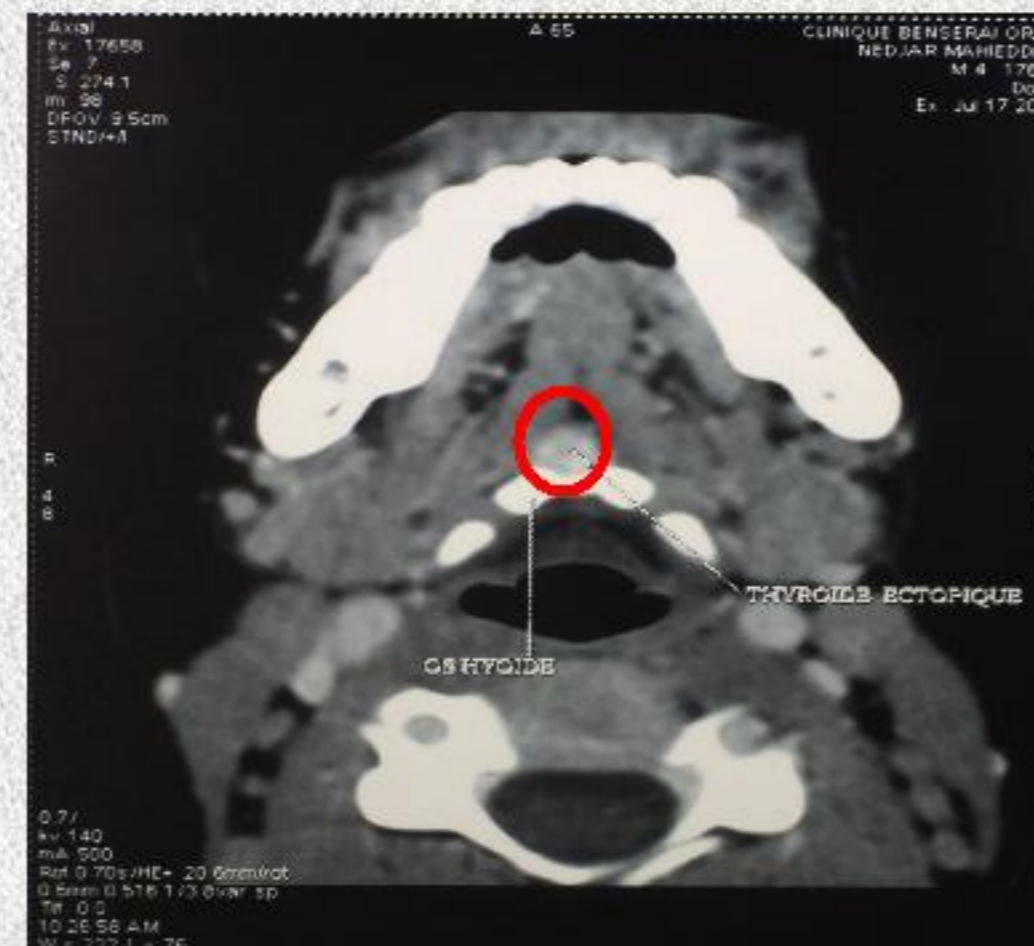
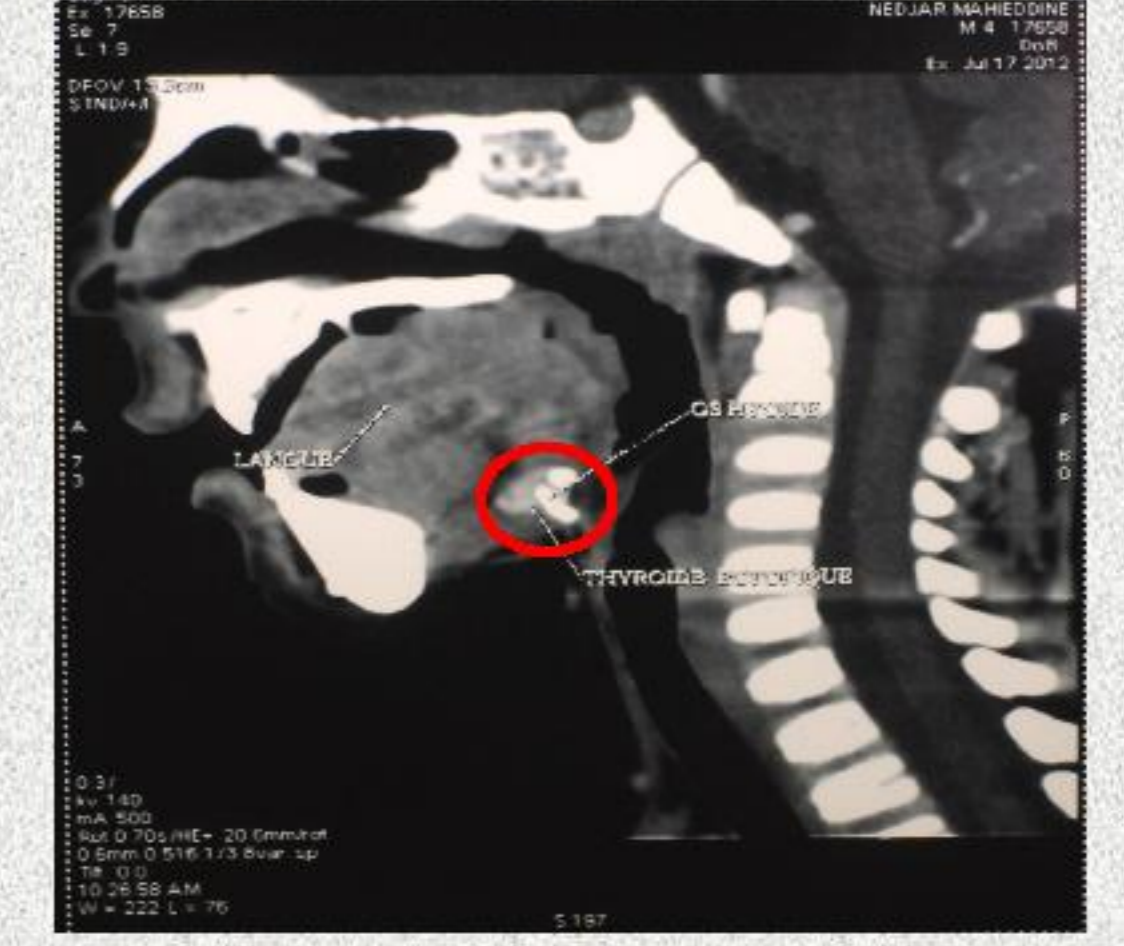
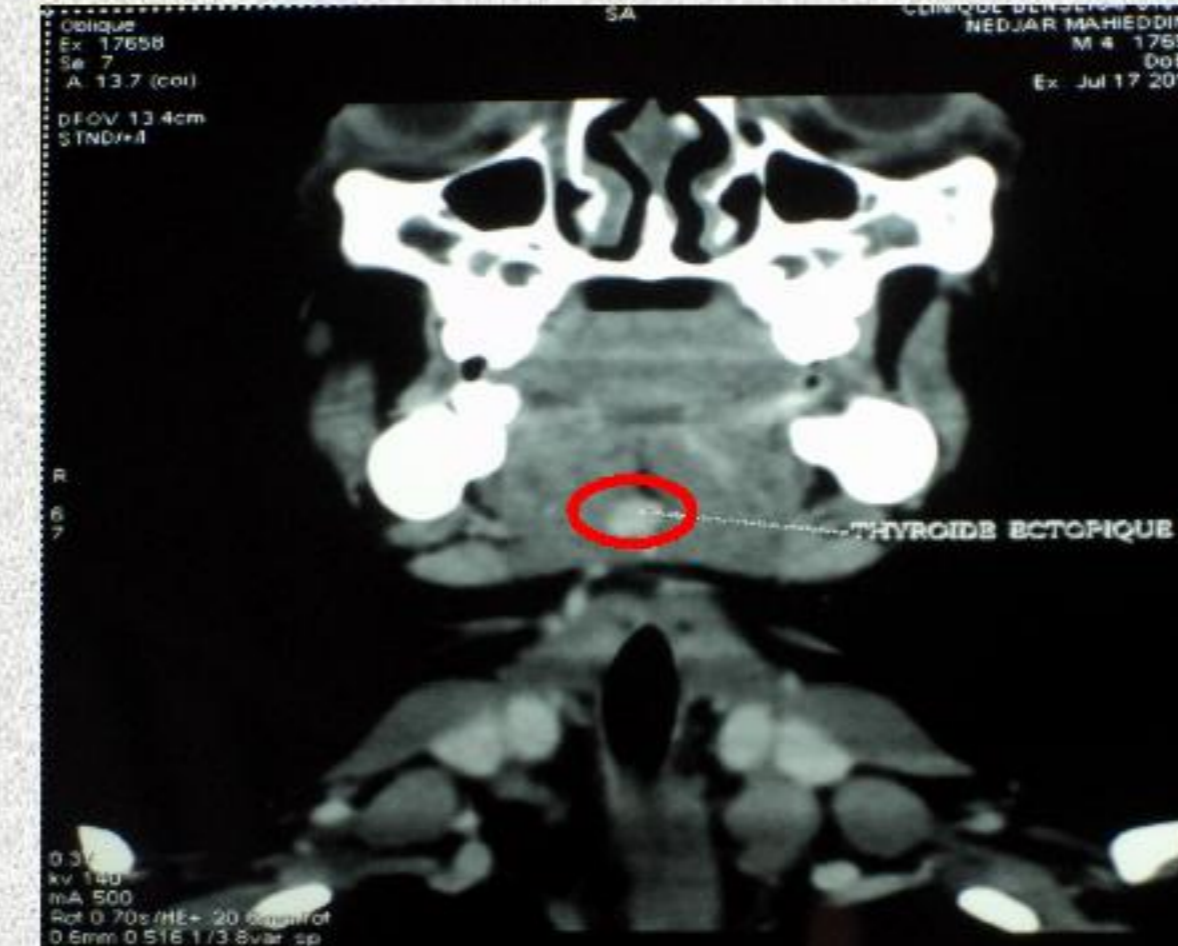fig-3



Discussion

The lingual thyroid is a relatively rare condition with an incidence of 1 in 3000 persons [1]. It is a developmental anomaly, in which thyroid tissue is seen at the base of the tongue between circumvallate papillae and epiglottis. The thyroid analogue, which arises from the ventral pharynx between first and second pharyngeal pouch fails to descend leading to development of this anomaly [2]. Lingual thyroid is the only functional thyroid tissue in 70% of these patients [2].

Majority of patients with lingual thyroid are asymptomatic. Symptomatic lingual thyroid is commonly seen in women in a ratio of 7:1 over men [2]. It may present with complaints of dyspnoea, dysphagia, dysphonia or bleeding [4]. The symptoms are related to the size of the ectopic thyroid [2]. Diseases of normal thyroid may also occur in lingual thyroid. In the present patient T3, T4 levels were decreased and TSH, TG (THYROGLOBULINE) level was increased suggestive of hypothyroidism.

The diagnosis can be confirmed on radionuclide scans using I132 or Tc99. In the present patient, a Tc99 radionuclide scan revealed absence of uptake in the region of normal thyroid gland, and increased uptake in the region of base of tongue, suggestive of ectopic lingual thyroid. Although MRI has been advocated as the most useful radiological investigation as it allows multiplanar imaging and provides good soft tissue definition.

In the present patient CT helped to define the relationship of lingual thyroid to the adjacent structures. The differential diagnosis of midline mass at the base of tongue is teratoma, carcinoma and soft tissue sarcomas [3]. Asymptomatic and euthyroid patients are normally followed up regularly [1]. Patients with sub clinical hypothyroidism may require thyroxine supplementation. Surgical treatment is required in patients with considerable symptoms [1].

Thyroid ablation with radioactive iodine is an alternative to surgery and is usually reserved for unfit patients or those who refuse surgical intervention.

Conclusion

Our case suggests that ectopic thyroid tissue should be entertained as a tentative diagnosis in child presenting failure to thrive estimate at less 2 SD with severe dysphagia and hypothyroidism.

A surgical treatment is only chance to cure a case like our patients with obstructive complication of lingual thyroid.

References

1. Prasad KC, Bhat V. Surgical management of lingual thyroid. A report of four cases. J Oral Maxillofac Surg. 2000;58:223-7.
2. Batsakis JG, El-Naggar AK, Luna MA. Thyroid gland ectopias. Ann Otol Rhinol Laryngol. 1996;105:996-1000.
3. Kamat MR, Kulkarni JN, Desai PB, et al. Lingual thyroid: a review of 12 cases. Br J Surg. 1979;66:537-9.
4. Lee CC, Chen CY, Chen FH, et al. Imaging of huge lingual thyroid gland with goitre. Neuro-radiology. 1998;40:335-7.

