

4 years between diagnosis and insulin therapy in a case of slow onset type 1 diabetes mellitus

Authors: D.T. Cosma¹; C.A. Silaghi^{2,3}; H. Silaghi^{3,4}; I.A. Veresiu^{1,3}
 Coordinator: I.A. Veresiu

¹ Diabetes, Nutrition and Metabolic diseases Clinical Center, Cluj-Napoca
² Endocrinology Clinic
³ "Iuliu Hatieganu" University of Medicine and Pharmacy, Cluj-Napoca
⁴ Vth Department of Surgery

INTRODUCTION:

Type 1 diabetes mellitus (T1DM) is the most common form of diabetes in children and young adults. The natural history of type 1 diabetes involves the following stages:

- a long preclinical period (antibodies and T-cells reactive with β -cell antigens can be detected);
- decline in β -cell function (observed years prior to the onset of clinical T1DM);
- hyperglycemic state (80-90% of the β -cells mass is lost due to insulinitis in the presence of antibodies and T-cells directed against islet α cells)

CASE REPORT

A 19-year-old male, diagnosed with T1DM at the age of 15, with no insulin treatment, was admitted to our department via a routine exam at his GP for high blood glucose (BG) values in the last 2 weeks (highest BG value of 365mg/dl).

His past medical history was consistent with: left popliteal and left femoral deep vein thrombosis in the context of a moderate (27%) deficit of S protein, mild dyslipidemia, moderate thinness (BMI=21.8kg/m²; 50-75 percentile) and mild normocytic, normochromic anemia, for which he received treatment with Aspirin 75mg daily and iron. During hospitalization for thrombosis, he presented slightly elevated basal BG values, intermittent glycosuria but no ketonuria.

Labs exams:

July 2010	December 2010	March 2011
basal BG=149 mg/dl; 2h-OGTT=386 mg/dl; A1c=5.2%; GAD-II=802 IE/ml (NV<10); ICA Ab <1/10 (NV<1/10); basal insulinemia=6.51 uIU/ml (NV= 6-27); C-peptide= 1.52 ng/ml (NV=0.9-4)	basal BG=114 mg/dl; A1c=5.2%; basal insulinemia=7.7 uIU/ml (NV < 27); C-peptide= 2.83 ng/ml (NV=0.9-4)	basal BG=132 mg/dl; A1c=7.28%;

Table no. 1: Evolution of labs exams in the first months after diagnosis

Type 1 DM (pro)	MODY (cons)	Type 2 DM (cons)
<ul style="list-style-type: none"> • age; • high level of GAD-II; • C peptide and insulin levels in the normal lower range; 	<ul style="list-style-type: none"> • no family history for DM; • normal BG values of both parents; 	<ul style="list-style-type: none"> • no history of overweight or obesity; • moderate thinness.

Table no. 2: Pro and cons for differential diagnosis

Due to good BG values under dietary treatment (with BG max <170mg/dl), the insulin treatment was postponed. The patient had followed the dietary recommendations only 6 months.

At admission in our department: weight=59kg; BMI=16.7kg/m²; BP=105/75 mmHg; Pulse=82/min. Labs exams revealed: G=285mg/dl, mild hypokalemia, mild dyslipidemia, ketonuria (150mg/dl), significant glycosuria (1g/dl) and the A1c >14% was consistent with a severe glycemic imbalance in the last 3 months.

A basal bolus regimen with glargine and lispro insulin was started, adjusted according to the BG values and carbs ingestion and respecting the correction factor (FC) of 1:50mg/ dl and the sensibility factor (FS) of 1:15g carbs. The screening for diabetes-related microvascular complications and autoimmune diseases was negative.

Discussions:

The diagnosis of slow onset type 1 DM:

- may be often a random discovery;
- involves mandatory the use of immunological labs exams and a sharp clinical judgment;
- may present a long asymptomatic period.

To our knowledge, this case presents the largest period (4 years) from the diagnosis of T1DM and initiation of the insulin therapy.

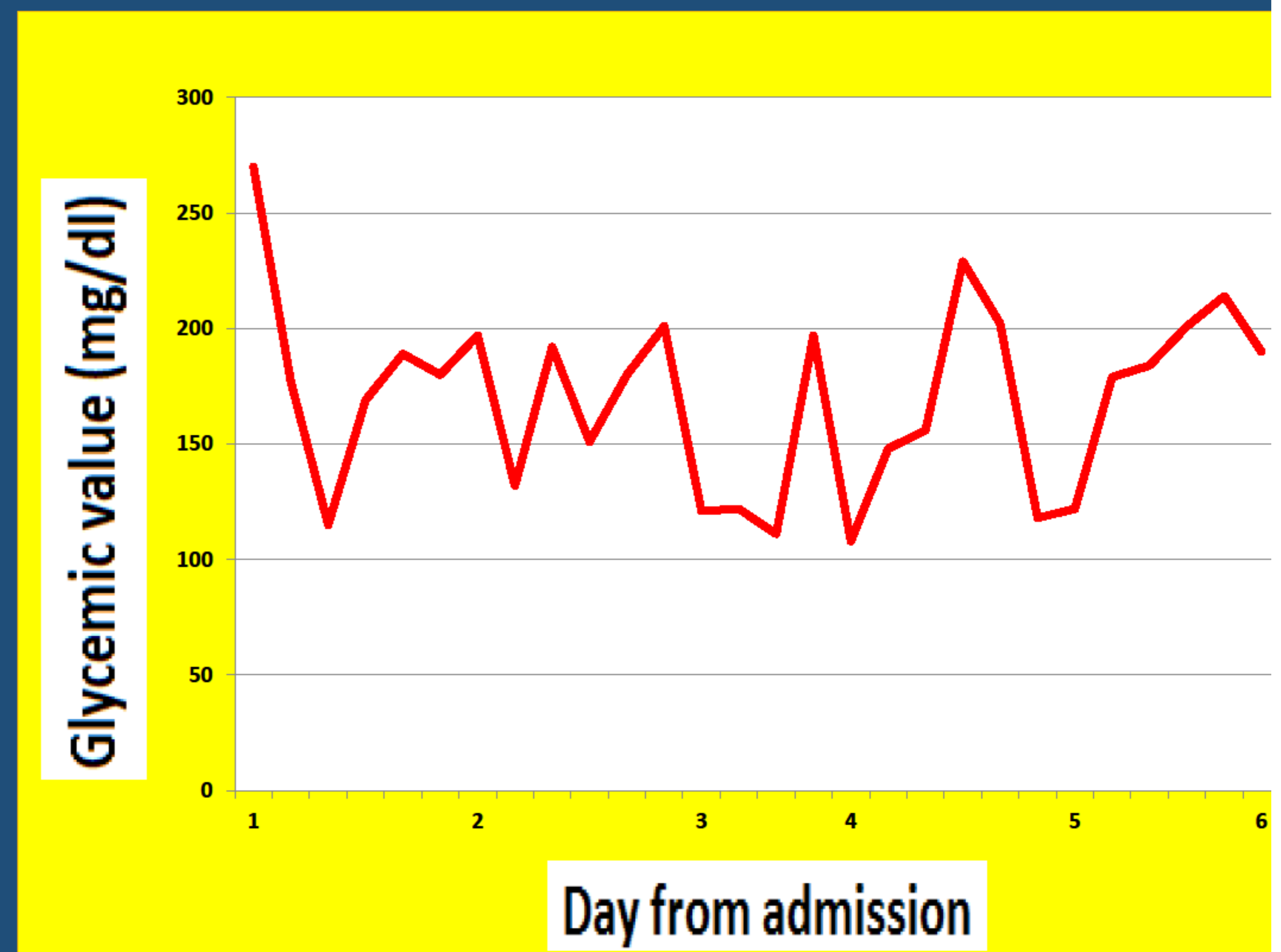


Fig. no. 1: Glycemic profile according to time from admission

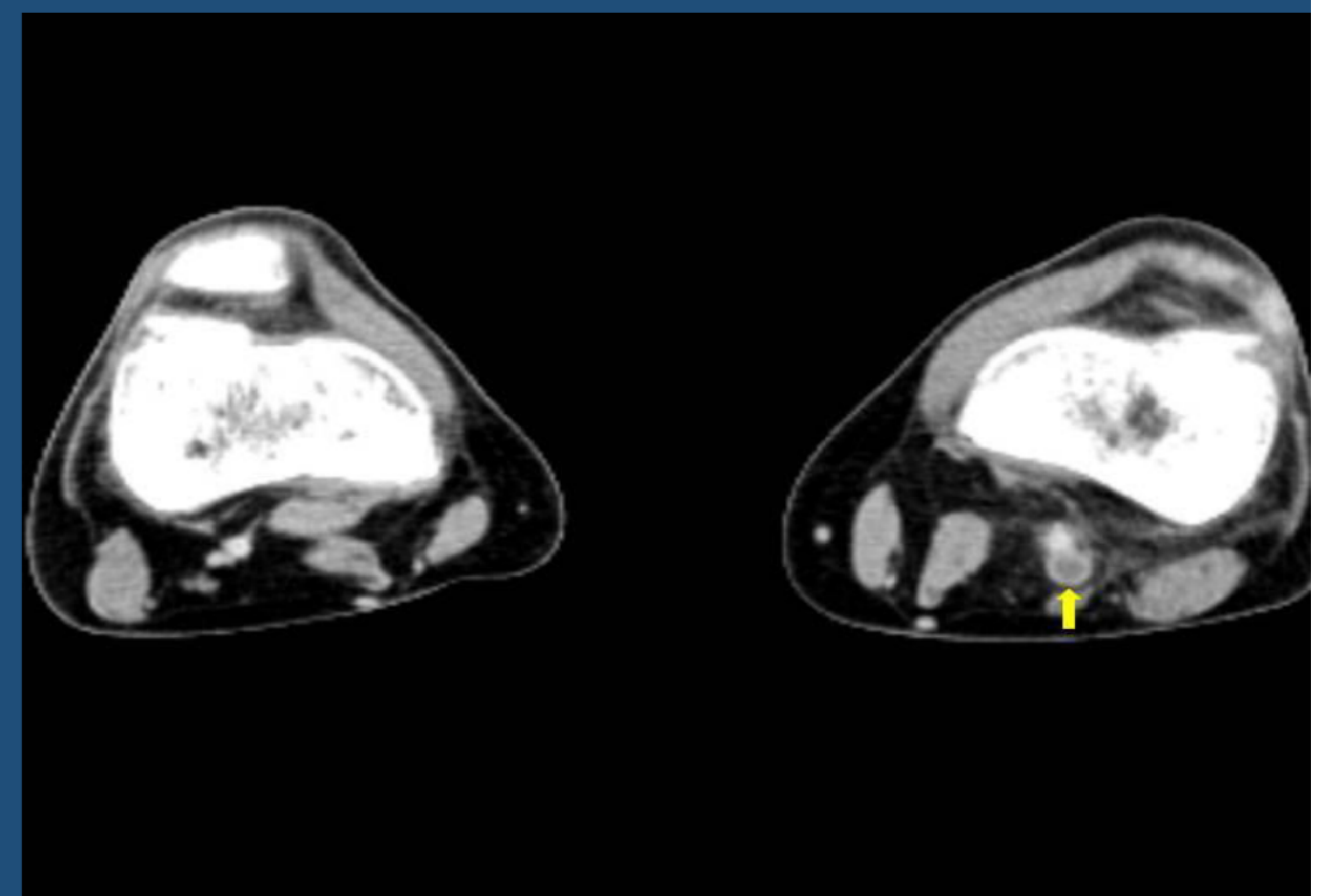


Fig. no. 2: Angio-CT (axial view): left popliteal vein thrombosis with edematous infiltrated adjacent fat

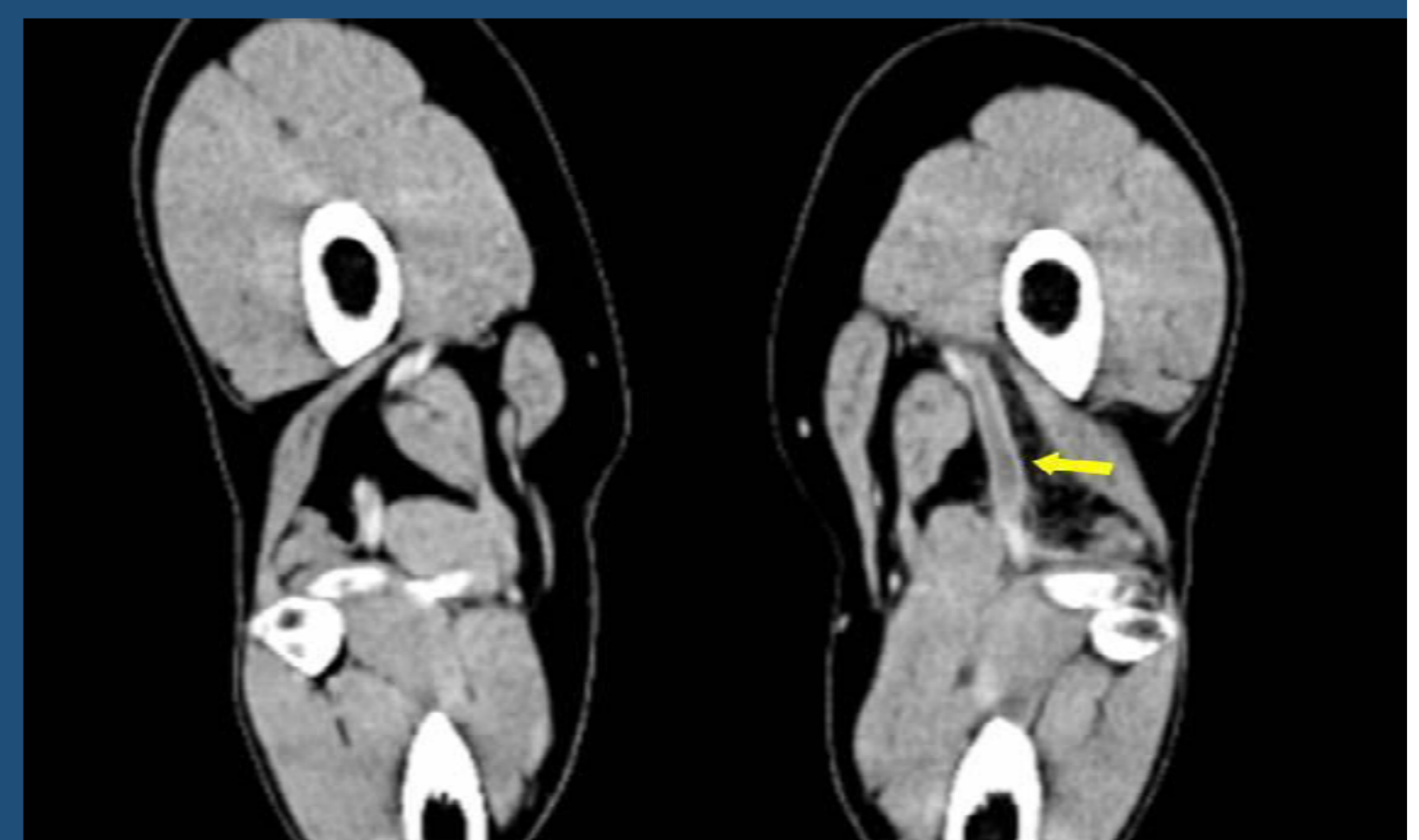


Fig. no. 3: Angio-CT (coronal section): left popliteal vein thrombosis edematous infiltrated adjacent fat

