

Diabetes Mellitus, Pre-Dialysis, Extreme Anxiety and Sarcoidosis

U.Shah(1)E. Soule(1), A. James(2), E. Casey(1), K. Nikookam(1)

Department of endocrinology(1) and renal medicine(2) King George Hospital, Barking, Havering and Redbridge University Trust Hospital, Greater London, United Kingdom

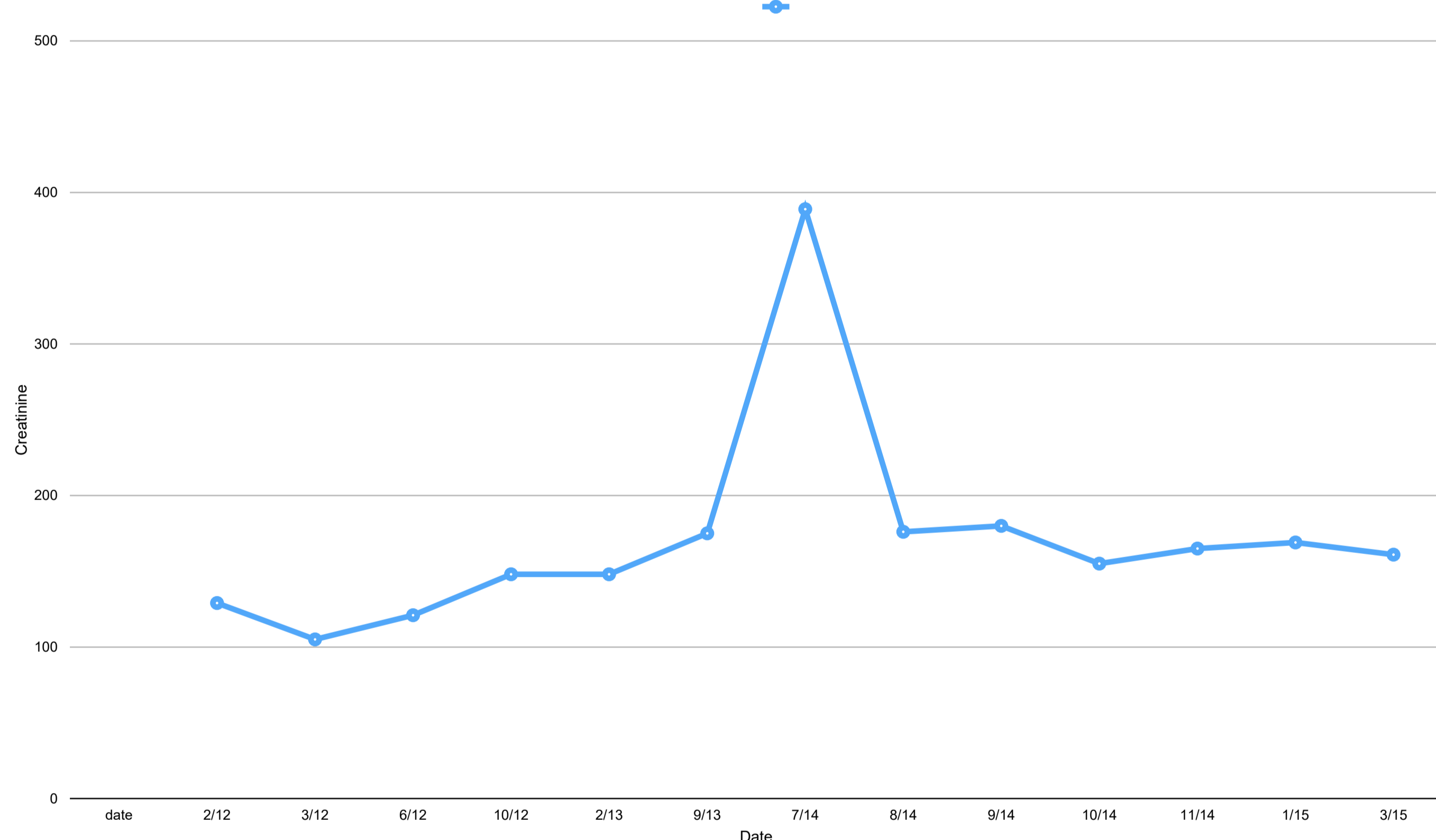
Introduction

Diabetic nephropathy is the leading cause of chronic kidney disease and is responsible for 30-40% of all end stage renal disease. Where there is rapid decline in eGFR, we should also consider other aetiologies

History, Examination and Investigation

This is the case of a 65 year old Caucasian gentleman with complex presentation and novel management strategy with type 2 diabetes mellitus since 1999 which was effectively managed, evident by reasonable control of HBA1c. Pharmacotherapy regimen was modulated sensitive to patient tolerability and outcome. His HBA1c has remained stable between 6 and 7%. On subsequent follow up his creatinine was 389umol/L from baseline of around 160umol/L. When patient was informed of possibility of dialysis over coming year, it caused him severe anxiety. During history taking, it was revealed that the patient had an episode of anterior uveitis for which he was under ophthalmology care. Thorough physical examination led to the discovery of an erythematous lesion on his left shin, and meticulous review of laboratory findings revealed intermittent hypercalcemia. This triad of observations led to discover shadowing, suspicious of hilar lymphadenopathy on chest x-ray

Creatinine results during follow up



Treatment and Outcome

moderate-dose prednisolone therapy was initiated for presumptive sarcoidosis; Biopsy was precluded due to body habitus. Corticosteroids provided a rapid return of creatinine to baseline, however, also necessitated introduction of insulin due to induction of hyperglycaemia. On subsequent commencement of azathioprine, prednisolone dosages were rapidly reduced, and insulin requirement were significantly reduced.

CONCLUSIONS

To encourage physicians to consider alternative aetiologies to diabetic nephropathy for acute renal failure in a diabetic patient, such as renal sarcoidosis. Secondly, rapid withdrawal of moderate-dose corticosteroids and substitution with a steroid-sparing agent as a novel therapeutic modality for treatment of renal sarcoidosis in the setting of diabetes mellitus was superior to the established protocol(1,2). This sequential pharmacotherapy has preserved quality of life, as renal failure requiring long-term haemodialysis was imminent, and corticosteroid withdrawal allowed for continuing better glycaemic control.

References

1. Treatment of renal sarcoidosis: is there a guideline? Overview of the different treatment options. *Nephrol Dial Transplant*. 2014 Oct;29(10):1841-7. doi: 10.1093/ndt/gft442. Epub 2013 Nov 13.
2. Unexpected hypercalcemia in a diabetic patient with kidney disease. *World J Nephrol*. 2015 Jul 6; 4(3): 438-443. Published online 2015 Jul 6. doi: [10.5527/wjn.v4.i3.438](https://doi.org/10.5527/wjn.v4.i3.438) PMID: PMC4491935

