

# Sentinel lymph node biopsy in medullary thyroid microcarcinoma using methylene blue dye mapping - a pilot study -

## Authors:

Radan Dzodic<sup>1,2</sup>, Nada Santrac<sup>1</sup>, Merima Goran<sup>1</sup>, Marko Buta<sup>1,2</sup>, Igor Djuriscic<sup>1</sup>, Gordana Pupic<sup>3</sup>, Ognjen Zivkovic<sup>3</sup>, Ivan Markovic<sup>1,2</sup>

<sup>1</sup> Institute for Oncology and Radiology of Serbia, Surgical Oncology Clinic, Pasterova 14, Belgrade, Serbia

<sup>2</sup> University of Belgrade, School of Medicine, Dr Subotica 8, Belgrade, Serbia

<sup>3</sup> Institute for Oncology and Radiology of Serbia, Department of Pathology, Pasterova 14, Belgrade, Serbia



## INTRODUCTION

Serum calcitonin level (sCT) is a precise marker for medullary thyroid carcinoma (MTC) [1]. However, lymph node (LN) metastases can be found in lower sCT, as well, and preoperative ultrasound may provide false negative findings on regional LNs [2, 3].

**The aim was to present original technique of sentinel lymph node (SLN) biopsy of jugulo-carotid regions, after methylene blue dye mapping procedure, and its usefulness for selection of clinically N0 patients with MTC for modified radical neck dissection (MRND).**

## MATERIALS AND METHODS

From 2007 to 2015<sup>th</sup>, 14 patients were operated in our Surgical Oncology Clinic due to MTC with sCT lower than 1000pg/ml, tumors under or 10mm in size and clinically negative regional LNs. Central neck dissection was done in all patients. **SLN mapping was performed with 0.2-0.5ml of 1%-methylene blue dye [4].** Levels II and III were explored on both sides, blue stained SLNs (Figure) were removed and examined by frozen section analysis. If *ex tempore* result was negative (benign SLNs), additional surrounding non-colored LNs were removed for more precise evaluation and no further dissection was needed. If SLNs were positive (malignant), MRND was performed.

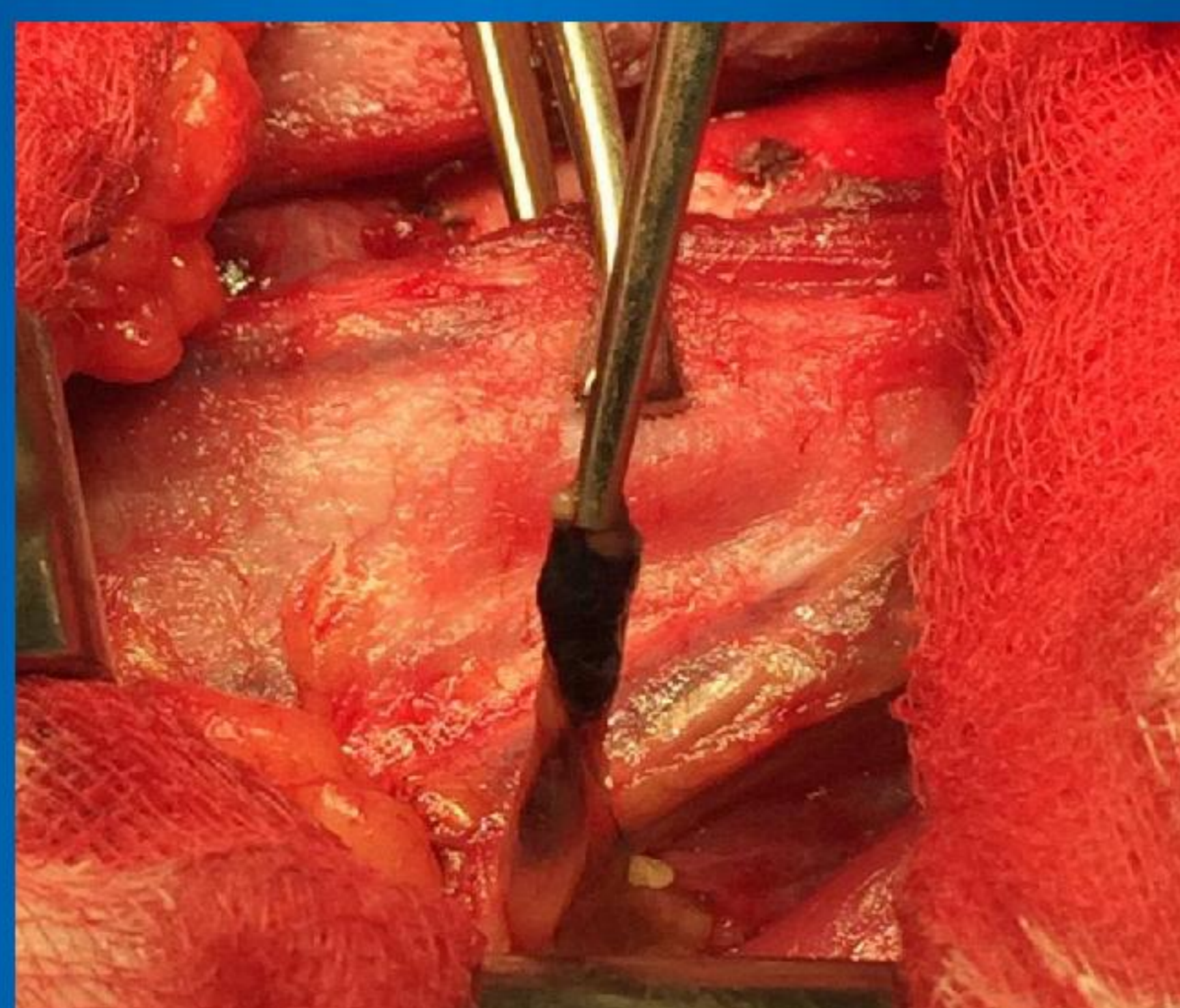


Figure: Blue-stained sentinel lymph node identified in the right jugulo-carotid region

## RESULTS

One patient had hereditary form of MTC, with bilateral subcentimeter tumors, while others had sporadic, unilateral MTC. Sporadic MTCs showed no central nor lateral LN metastases on bilateral SLN biopsy, with no indication for MRND. Hereditary MTC had central LN metastases, with positive SLNs on both sides, thus one-time bilateral MRND was performed. This patient had metastases in other dissected LNs, as well, and sCT of 200 pg/ml. Frozen section and definite pathological analysis were 100% match.

## CONCLUSION

SLN biopsy after methylene blue dye injection can be precisely used for intraoperative assessment of lateral LNs. It optimizes surgery for patients with MTCs, selecting clinically N0, but true positive patients for MRND. **This pilot study is the first reported experience with SLN biopsy of jugulo-carotid regions in MTC, using methylene blue dye.**

## REFERENCES

1. Miyauchi A, Onishi T, Morimoto S, Takai S, Matsuzuka F, Kuma K, Maeda M, Kumahara Y. Relation of doubling time of plasma calcitonin levels to prognosis and recurrence of medullary thyroid carcinoma. *Ann Surg* 1984; 199(4): 461-466.
2. Sippel RS, Kunnimalaiyaan M, Chen H. Current management of medullary thyroid cancer. *Oncologist* 2008; 13(5):539-547.
3. Dralle H, Damm I, Scheumann GF, Kotzerke J, Kupsch E, Geerlings H, Pichlmayr R. Compartment-oriented microdissection of regional lymph nodes in medullary thyroid carcinoma. *Surg Today* 1994; 24(2): 112-121.
4. Dzodic R, Markovic I, Inic M, Jokic N, Djuriscic I, Zegarac M, Pupic G, Milovanovic Z, Jovic V, Jovanovic N. Sentinel lymph node biopsy may be used to support the decision to perform modified radical neck dissection in differentiated thyroid carcinoma. *World J Surg* 2006; 30(5): 841-846.

Endocrine tumors and neoplasia

