


# Mechano growth factor (MGF) expression increased in secondary compared to primary foci in well neuroendocrine neoplasms

EP618

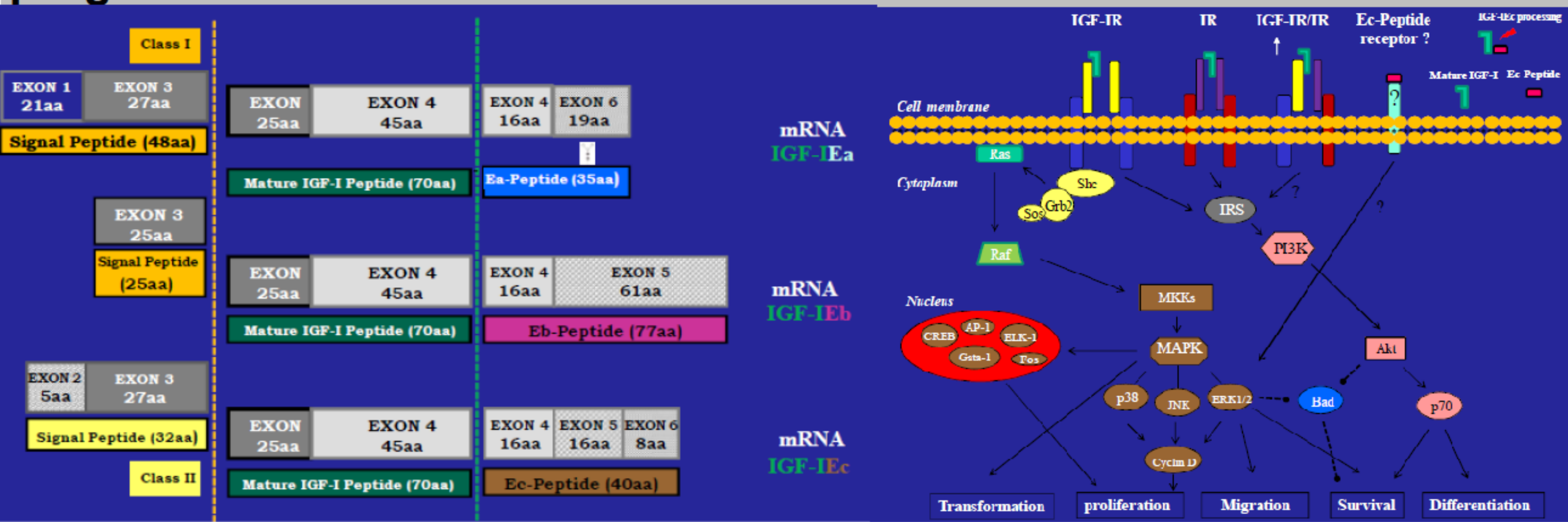
Krystallenia Alexandraki, Anastasios Philippou, Georgios Boutzios, Panagiotis Moschouris, James Karnezis, Irini Theohari, Michael Koutsilieris, Ioanna Delladetsima, Gregory Kaltsas



Department of Pathophysiology, Laikon Hospital, Medical School, National and Kapodistrian University of Athens, Greece  
 Department of Experimental Physiology, Medical School, National and Kapodistrian University of Athens, Athens, Greece  
 First Department of Pathology, Medical School, National and Kapodistrian University of Athens, Athens, Greece

## Introduction

Insulin-like growth factor-I (IGF-I): important role in cell proliferation, differentiation, migration, and survival.  
 Alternative splicing → different IGF-I mRNA transcripts → proteins with different responses in different stimuli as IGF-IEc (mechano growth factor, MGF): muscle regeneration process + mitogenic and anti-apoptotic role in the pathophysiology of various types of cancer.  
 Prostate cancer: high grade cancers more autonomous and less sensible in IGF-1 compared to low grade malignancy + IGF-1: limited role in early development of the cancer but central role in cancer progression.



## Objectives

The role of MGF in the pathophysiology of neuroendocrine neoplasms (NENs).

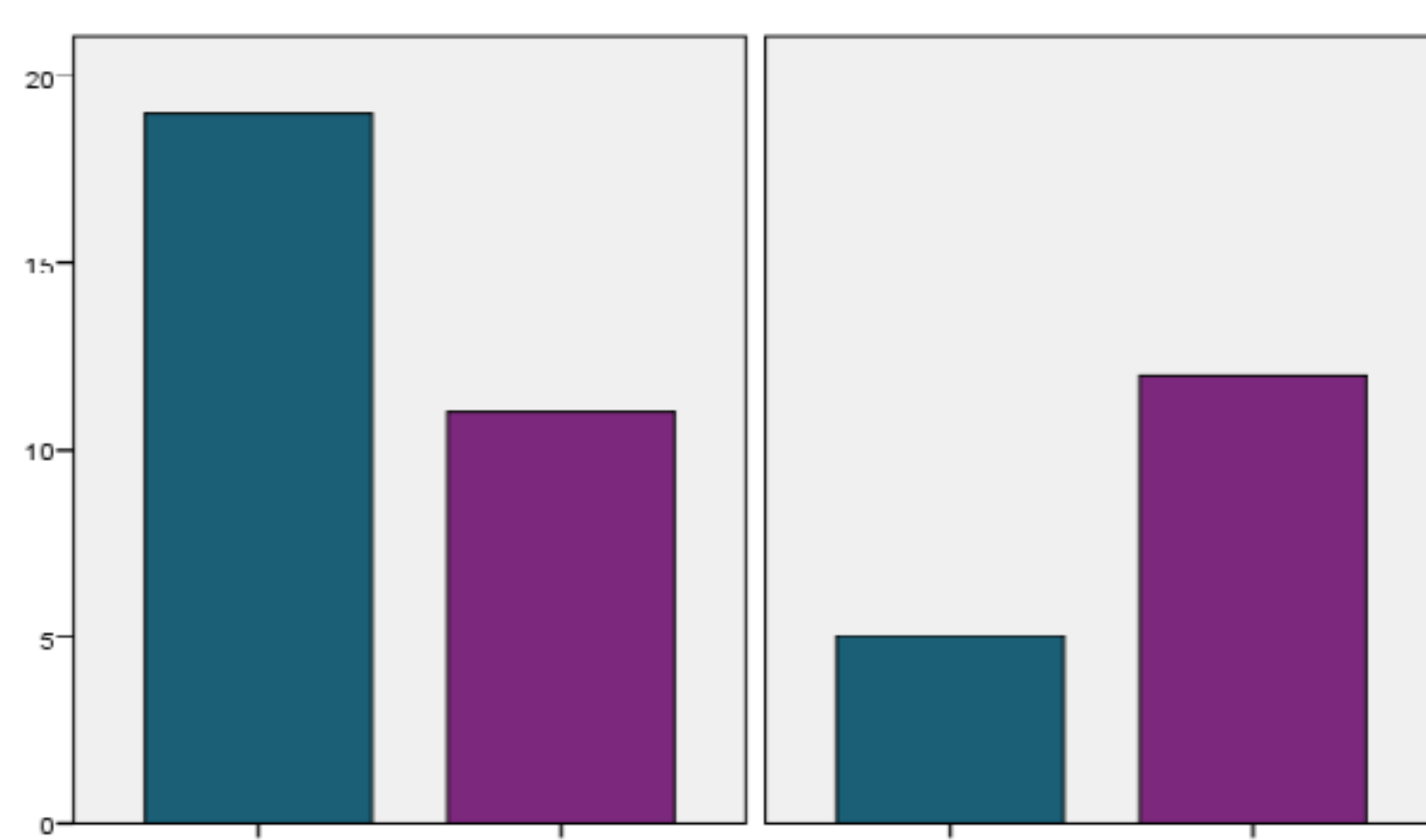
## Materials and methods

We have used immunohistochemistry in 47 specimens of patients with NENs to show the expression status of MGF isoform. Proliferation index ki-67 MIB1 (%) was evaluated. We have studied 8 gastric, 17 pancreatic, 3 appendiceals, 9 small intestine, 2 colic and 1 retrosigmoidal, 1 gallbladder, 2 lung NENs, 1 well differentiated unknown primary (UPO), 3 poorly differentiated UPO, and 1 other. We have studied the following subgroups:  
 1. specimens with negative staining (A), staining 1-10% (B), staining >50% (C)  
 2. specimens with Ki-67 ≤2% (I), 2-20% (II), >20% (III)

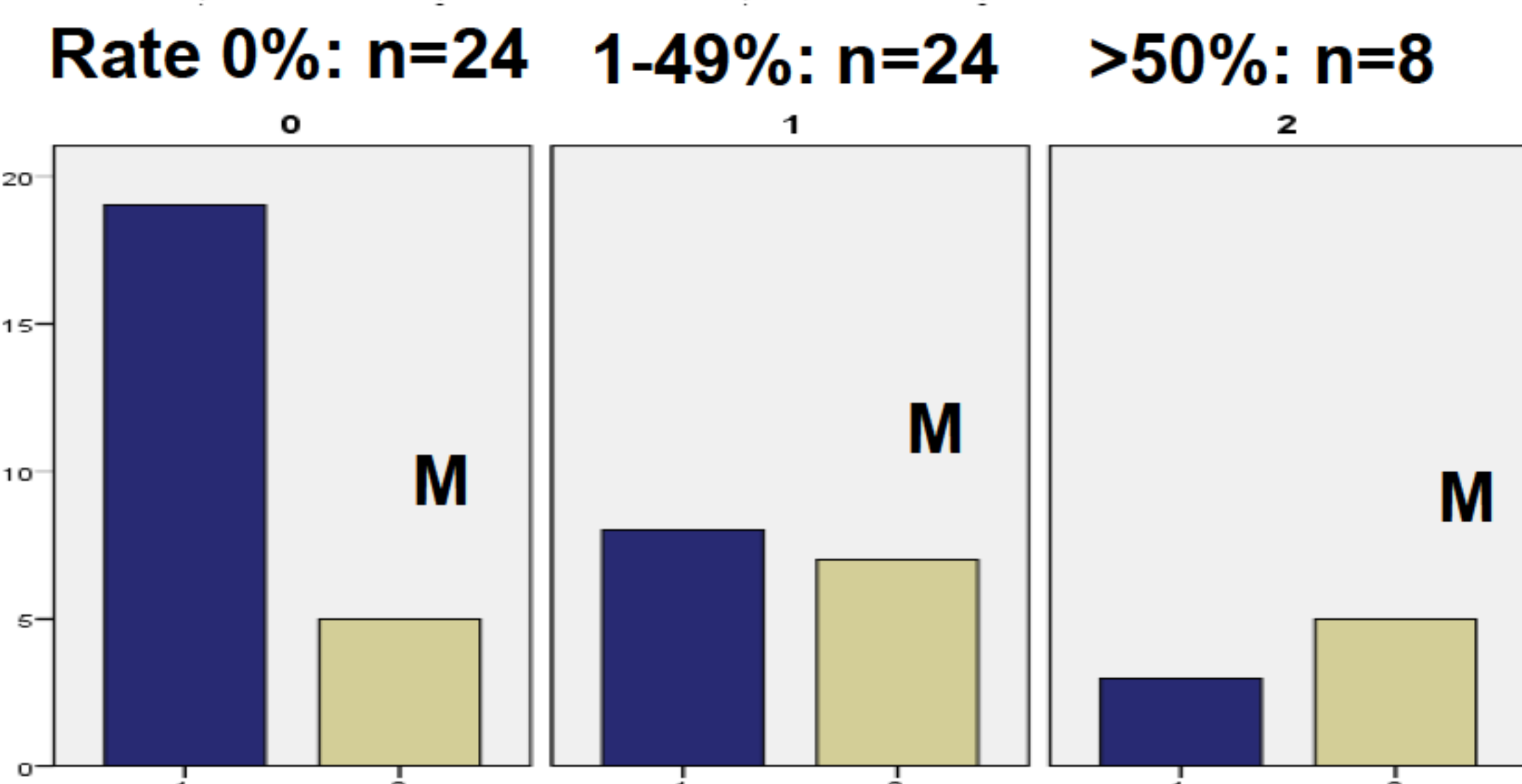
## Results

No MGF staining was found in 24 (51%) specimens. Cytoplasmatic staining was found in 23 specimens: 1% in 6 (26%), 10% in 9 (40%), 50% in 4 (17%), 80% in 1 (4%) and 100% in 3 (13%); focal staining in 15 (32% η 65%); diffuse in 7 (15% η 30%) and dot like in 1 (2% η 5%) specimen.

PRIMARY SITE METASTATIC FOCI



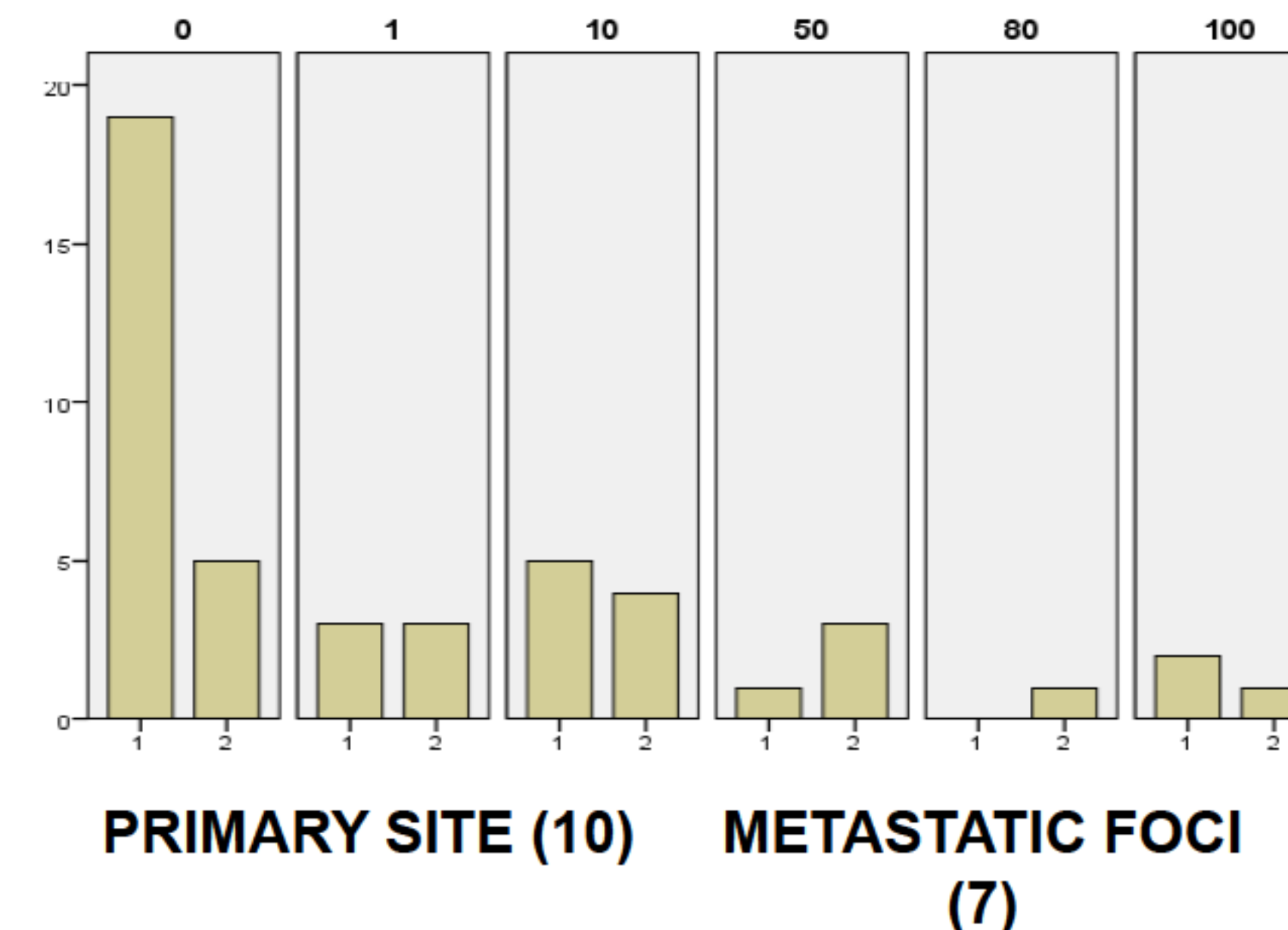
IGF1Ec isoform F staining was more prevalent in specimens from metastatic foci compared to specimens from primary tumours (p=0.036).



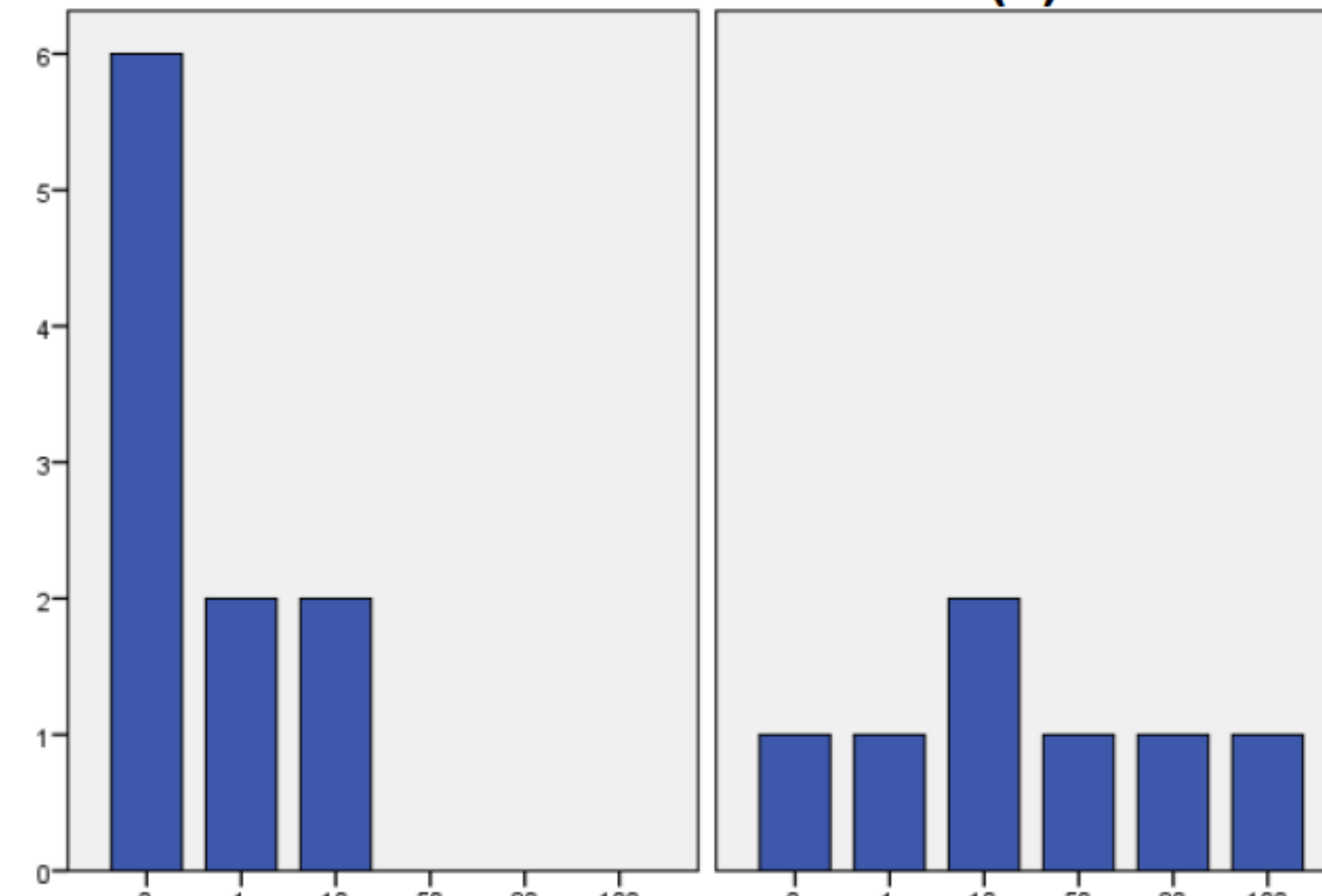
MGF staining was more prevalent in specimens from metastatic foci (p=0.029).

## Results

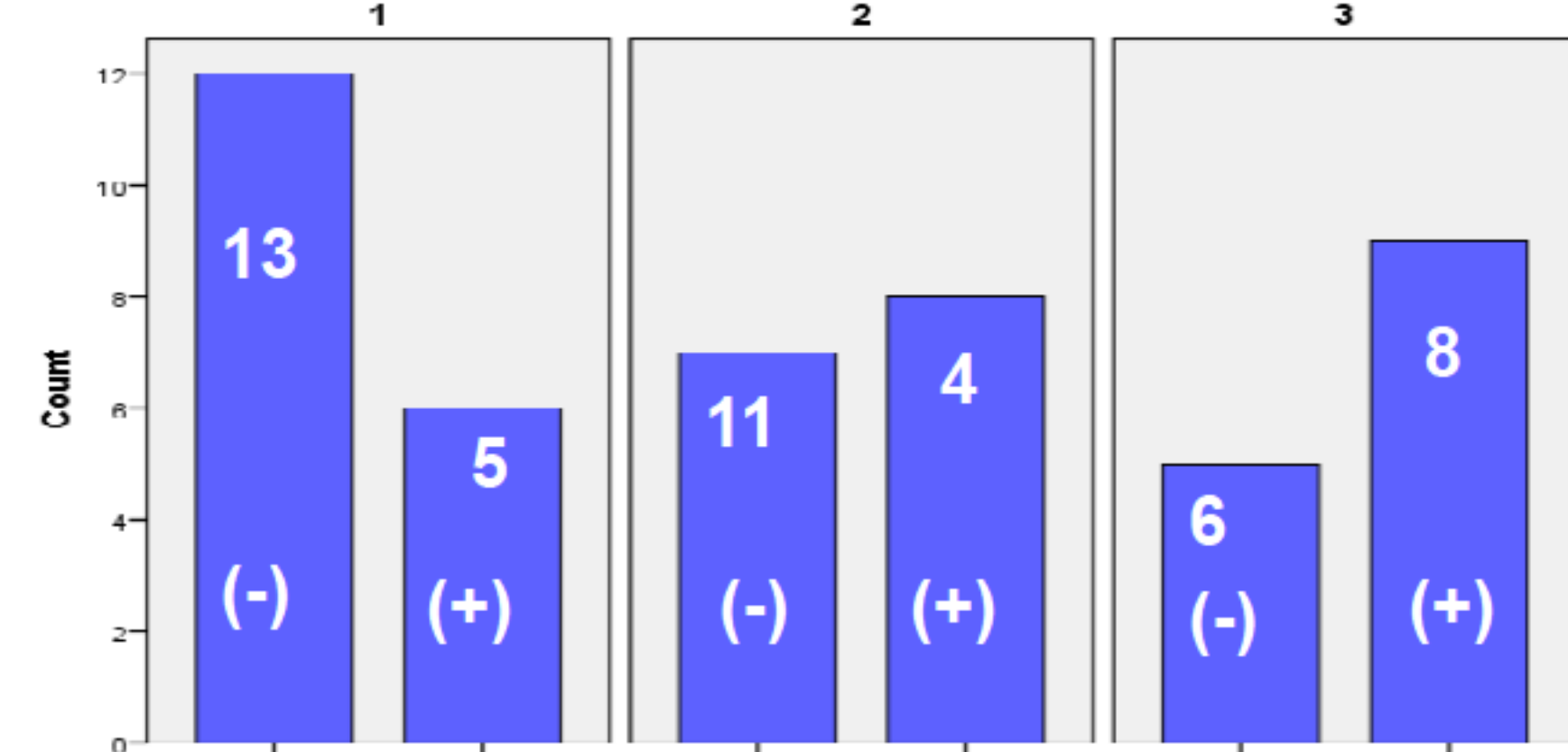
Rate of MGF staining in subgroups from primary or metastatic sites.



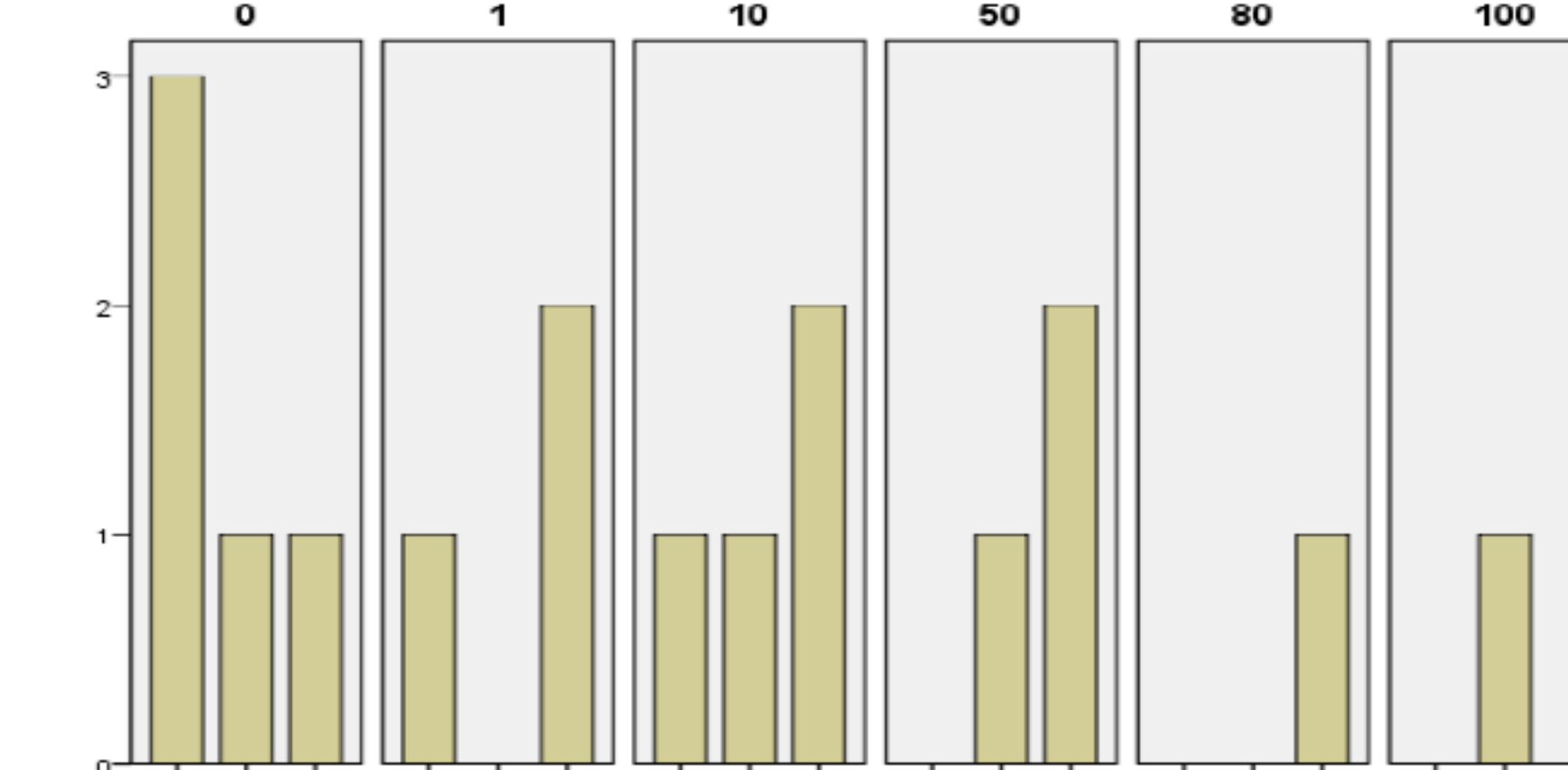
Group 1: specimens from primary tumours.  
 Group 2: specimens from metastatic.



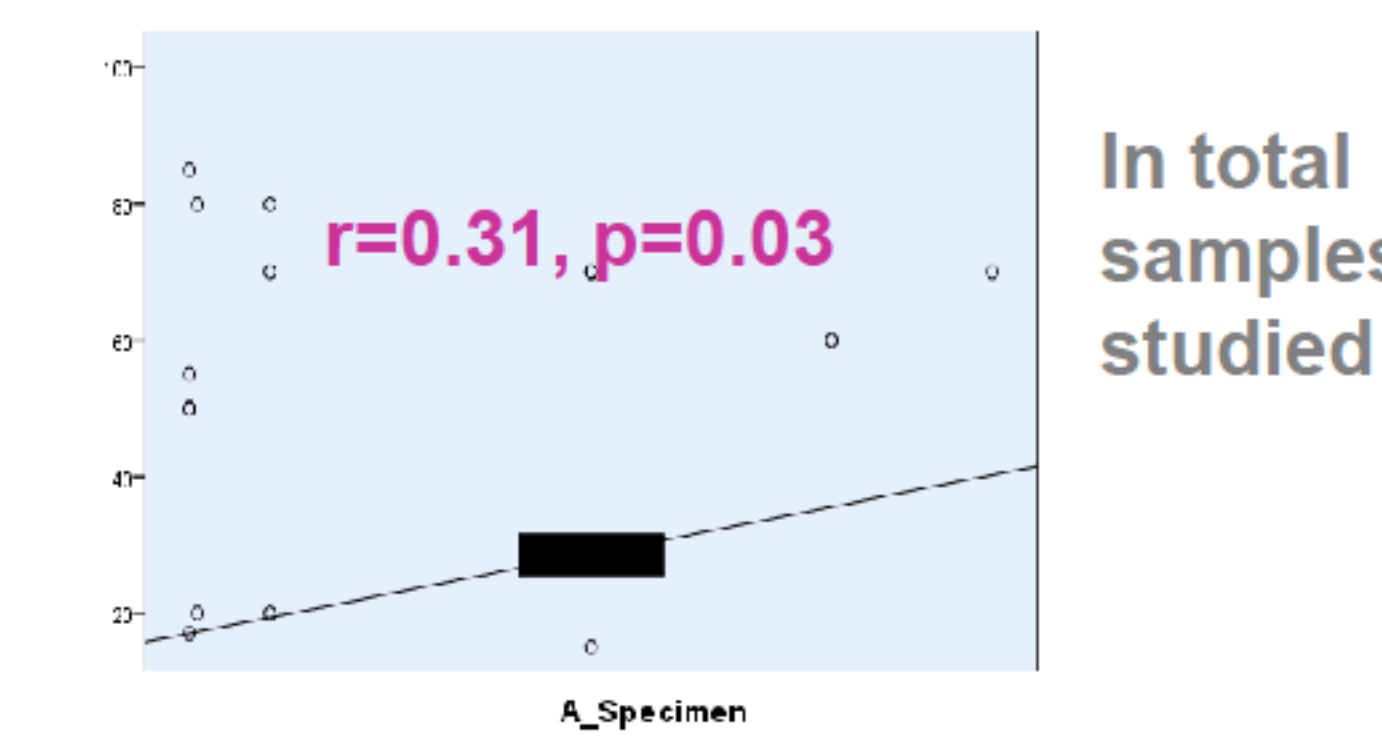
17 specimens from pancreatic NENs.



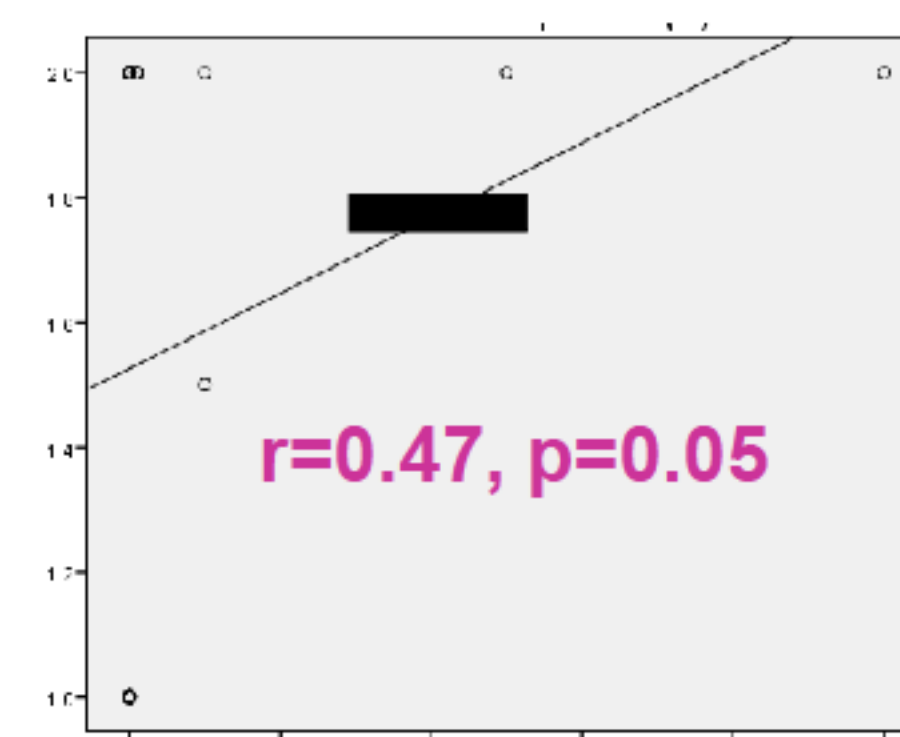
Group 0: specimens from primary tumours.  
 Group 1: specimens from metastatic.  
 Subgroups with different Ki-67: 1 (18): Ki-67 ≤ 2%; 2 (15): Ki-67 2%-20%; 3 (14): Ki-67 ≥ 20%.



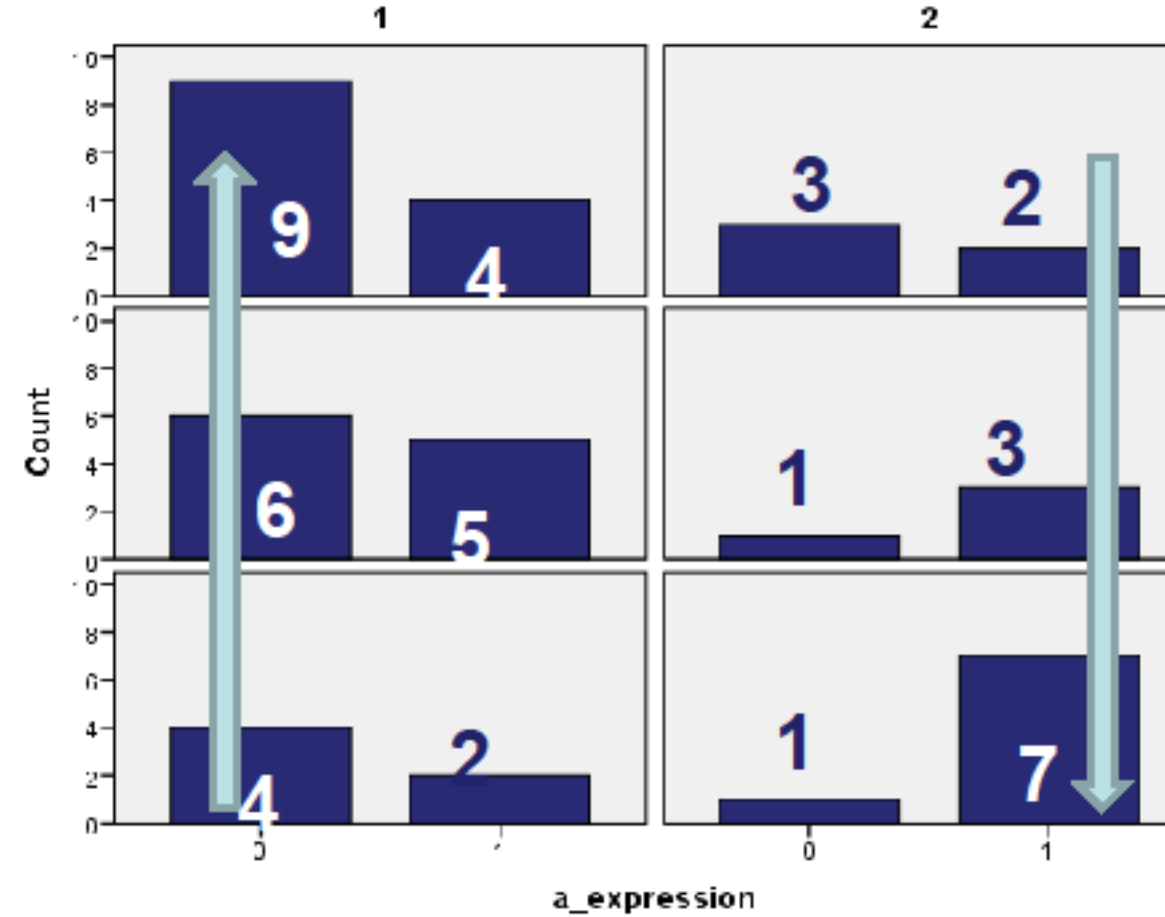
Subgroups with different Ki-67: 1: Ki-67 ≤ 2%; 2: Ki-67 2%-20%; 3: Ki-67 ≥ 20%.



In total samples studied



In subgroup with Ki-67 ≤ 2



Increased expression of MGF in metastatic sites.  
 Positive correlation of MGF and Ki-67.  
 Less expression of MGF in primary sites with low Ki-67.  
 High expression of MGF in metastatic foci with high Ki-67.

## Conclusions

Our preliminary data suggest that MGF expression may be involved in the pathophysiology of well differentiated NENs. Further studies will shed light to the exact role of IGF1Ec isoform in the presentation or progress of NENs particularly in secondary sites.

## References

- Philippou et al 2011 *Anticancer Res.* 31, 4259-4265.
- Philippou et al 2013 *Front Endocrinol (Lausanne)* 4:31.
- Wulbrand et al 2000 *Eur J Clin Invest.* 30:729-39.
- Vitale et al 2006 *Oncol Rep.* 15:1249-56