

NON-HODGKIN'S B CELL LYMPHOMA PRESENTING AS ACUTE ADRENAL CRISIS

Introduction:

We present a rare case of Non-Hodgkin's large B Cell lymphoma presenting as circulatory collapse and acute adrenal insufficiency.

Case Description

A 47-year-old woman was referred with a 1 month history of weight loss of 7 kg and vomiting. Shortly after admission her condition deteriorated and she developed acute hypotension, BP was 92/58 mmHg, heart rate 100/min and required volume resuscitation. Examination revealed a thin woman with generalised hyperpigmentation. Serum sodium was 130 mmol/l, serum potassium 5.1 mmol/l, creatinine 112 µmol/l and urea 7.1 mmol/l. Full blood count was normal. She had a history of depression, peptic ulcer, hysterectomy and was taking Escitalopram 10mg daily. Acute adrenal insufficiency was suspected and peak post-Tetracosactrin (*Synacthen*), cortisol was 150 nmol/l (normal > 550 nmol/l). CT scan abdomen revealed massively enlarged adrenals; 8.6 cm x 5.7 cm on the left and similar on the right. There were also solid polar masses in the kidneys with extrinsic compression of the inferior vena cava. She rapidly improved with hydrocortisone and fludrocortisone. Adrenal biopsy demonstrated a diffuse large B cell lymphoma (non-germinal center subtype).

Proliferation fraction was 60%. PET scan demonstrated uptake in the right rib, bone marrow aspiration did not show evidence of infiltration. Staging was 4b. She was treated with Rituximab, Cyclophosphamide, Doxorubicin and Vincristine (CHOP). Antiphospholipid screen IgG antibody was negative. She subsequently went into a partial remission with a modest reduction in adrenal dimensions. Lymphoma with partial adrenal hypofunction has been reported to involve the adrenals in 3% of cases^{1,2}.

Learning Points / Discussion:

1. This lymphoma presented as an adrenal crisis while very rare, would have been life threatening if missed. In addition, adrenal hormone replacement therapy was critical for toleration of subsequent chemotherapy.
2. The case illustrates the importance of imaging the adrenals in cases of primary adrenal insufficiency.

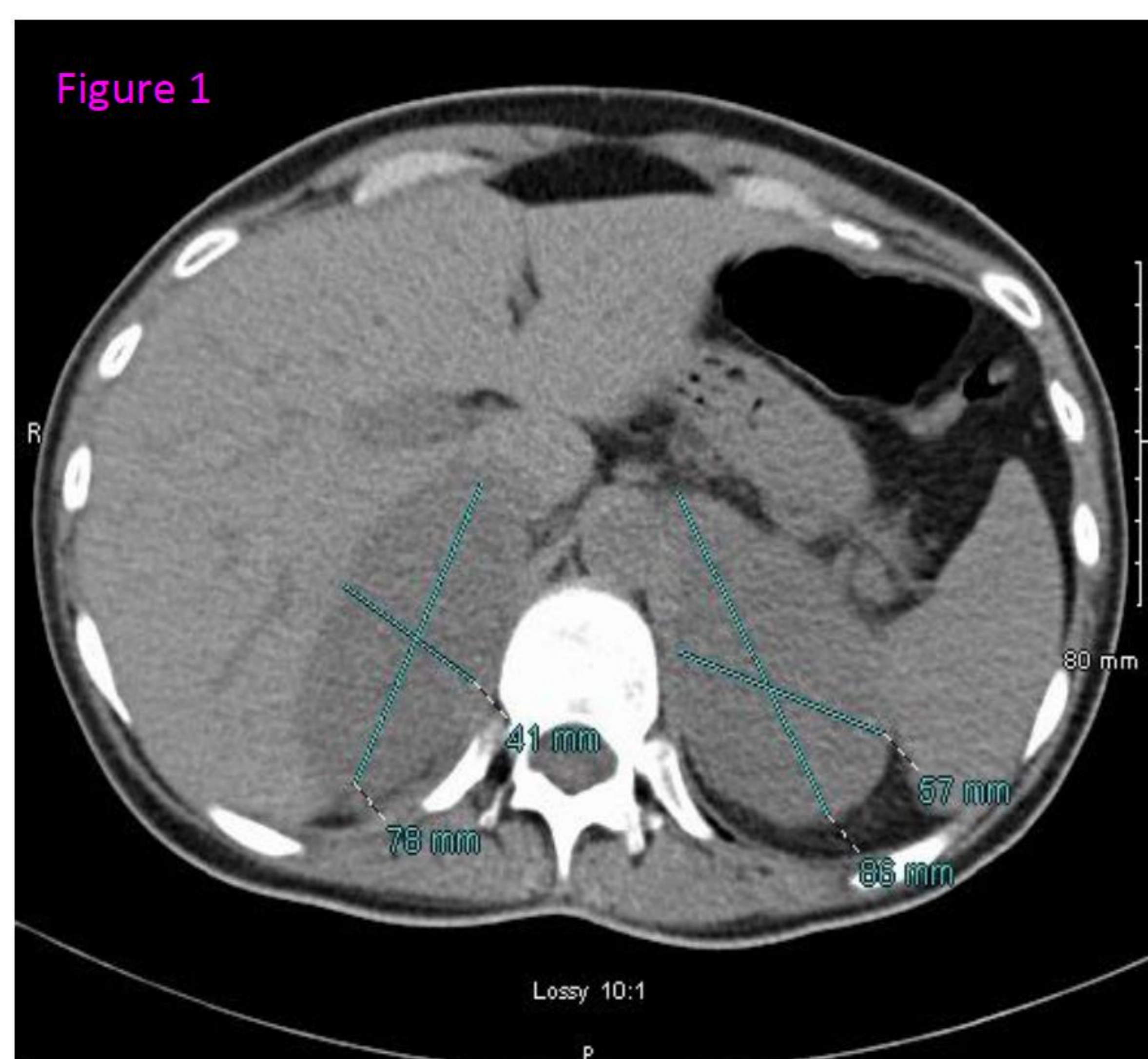


Figure 1:
CT Abdomen at presentation revealed enlarged adrenal glands and kidneys; Right: 8.6 cm x 5.7 cm and left: 7.8 cm x 4.1 cm.

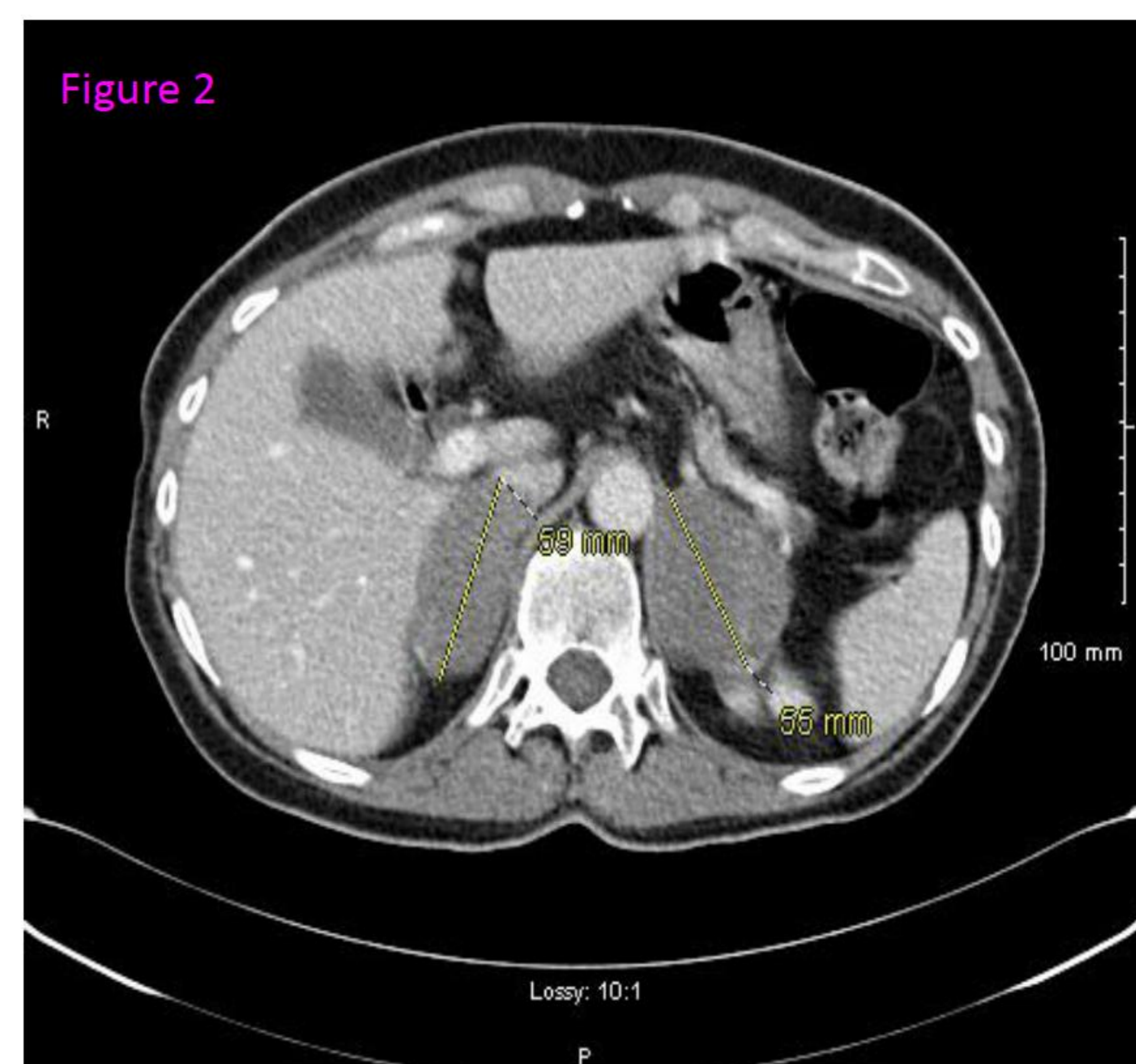


Figure 2:
CT Abdomen (Post Chemotherapy) on 1-year follow-up shows both adrenal glands have reduced in size.

References:

1. Nishiuchi T, Imachi H, Fujiwara M, Murao K, Onishi H, Kiguchi T, Takimoto H, Kushida Y, Haba R, Ishida T. A case of non-Hodgkin's lymphoma primary arising in both adrenal glands associated with adrenal failure. *Endocrine*. 2009;35:34-37.
2. Lee KS, Chung YS, Park KH, Kim HS, Kim HM. A case of primary bilateral adrenal lymphoma with partial adrenal insufficiency. *Yonsei Med J*. 1999;40:297-300.

