

PHEOCHROMOCYTOMA IN PREGNANCY

Kavitha Ganapathy, Murali Ganguri, Ramesh Babu Vanka, Shilpa Mahadasu, Rasha Mukhtar

James Cook University Hospital,
South Tees Hospitals NHS Foundation Trust
Middlesbrough



Case Study

- A 28 year old, 34 weeks pregnant female was referred to the endocrine antenatal service, during her second pregnancy with persistent palpitations, paroxysmal hypertension, throbbing headache. She had previously been investigated extensively by the cardiologists, without an underlying cause found.
- A diagnosis of anxiety was made and she was started on sertraline and a beta blocker, with worsening of her symptoms.
- In clinic, she was noted to be mildly hypertensive (148/93mmHg), with postural symptoms.
- On questioning, it was noted that her aunt was diagnosed with a pheochromocytoma and treated surgically. There was no other family history of endocrine related disease.
- Investigations for pheochromocytoma were completed and included :
 - Plasma metadrenaline : 118pmol/L
 - Plasma normetadrenaline : >25,000 pmol/L
 - 3-methoxytyramine: 508 pmol/L
 - U metadrenaline : 0.04umol/mmol
 - U normetadrenaline 4.16umol/mmol
- An MRI adrenal confirmed the presence of a right adrenal 59*54*58 mm, which was highly suspicious of a right adrenal pheochromocytoma
- She was started on treatment with Phenoxybenzamine 10mg tds with the addition of Bisoprolol 5mg, once alpha-blocked.
- At an MDT meeting, a decision was made for an elective LSCS at 37 weeks, followed by MIBG imaging to clearly localise any lesions prior to surgery.
- A healthy baby was delivered safely at 37 weeks. She remained on alpha and beta blockade.

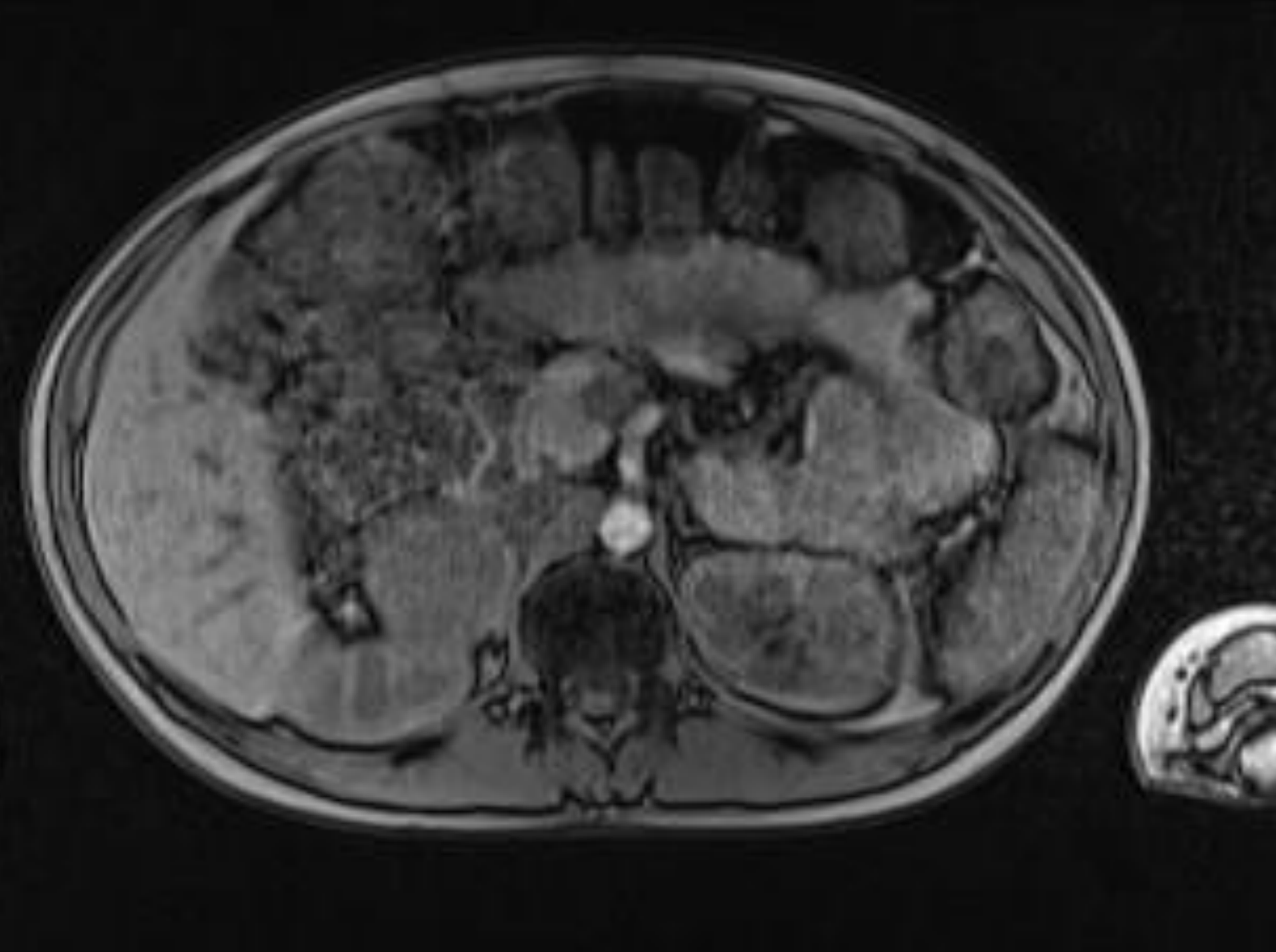
Case study continued

- MIBG scan confirmed the presence of a 5cm right adrenal mass and in addition a 1-2cm lesion within the left adrenal gland.
- Following another MDT discussion, it was decided to resect the dominant right adrenal mass first and only go back for a left adrenalectomy, if plasma metanephrines remained high.
- Her post surgery metadrenaline levels were
 - Plasma metadrenaline 87pmol/L (80-150)
 - Plasma normetadrenaline 835pmol/L
- The left adrenal mass was assumed to be incidental in view of the normalized biochemistry. Histology confirmed a pheochromocytoma positive for synaptophysin and chromogranin.
- Her blood pressure normalized post surgery, and her symptoms of palpitations, sweating and postural dizziness all resolved.
- She was sent for Genetic screening due to the family history.. This was negative but all family members have been invited for screening and she has been included in the 100,000 GENOME project.
- She is due to be followed up for the coming 10 years.

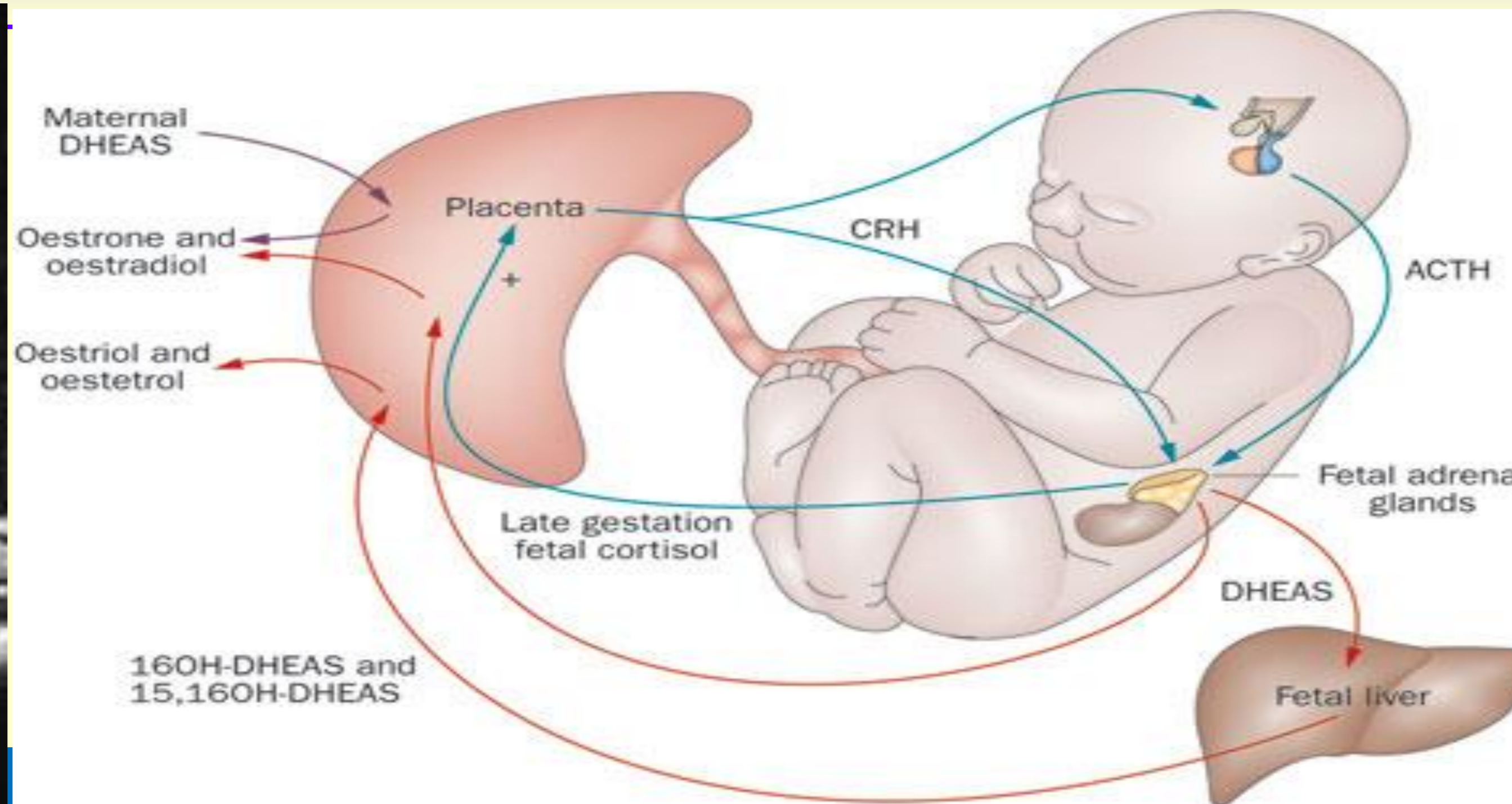
| DATE | 23/12/2015 Pre -surgery | 20/04/2016 Post surgery | Reference values |
|-------------------------|----------------------------|----------------------------|------------------|
| Plasma metadrenaline | 118 | 87 | 80-510 pmol/L |
| Plasma normetadrenaline | >25,000 | 835 | 120-1180 pmol/L |

Imaging and Fetal placental unit

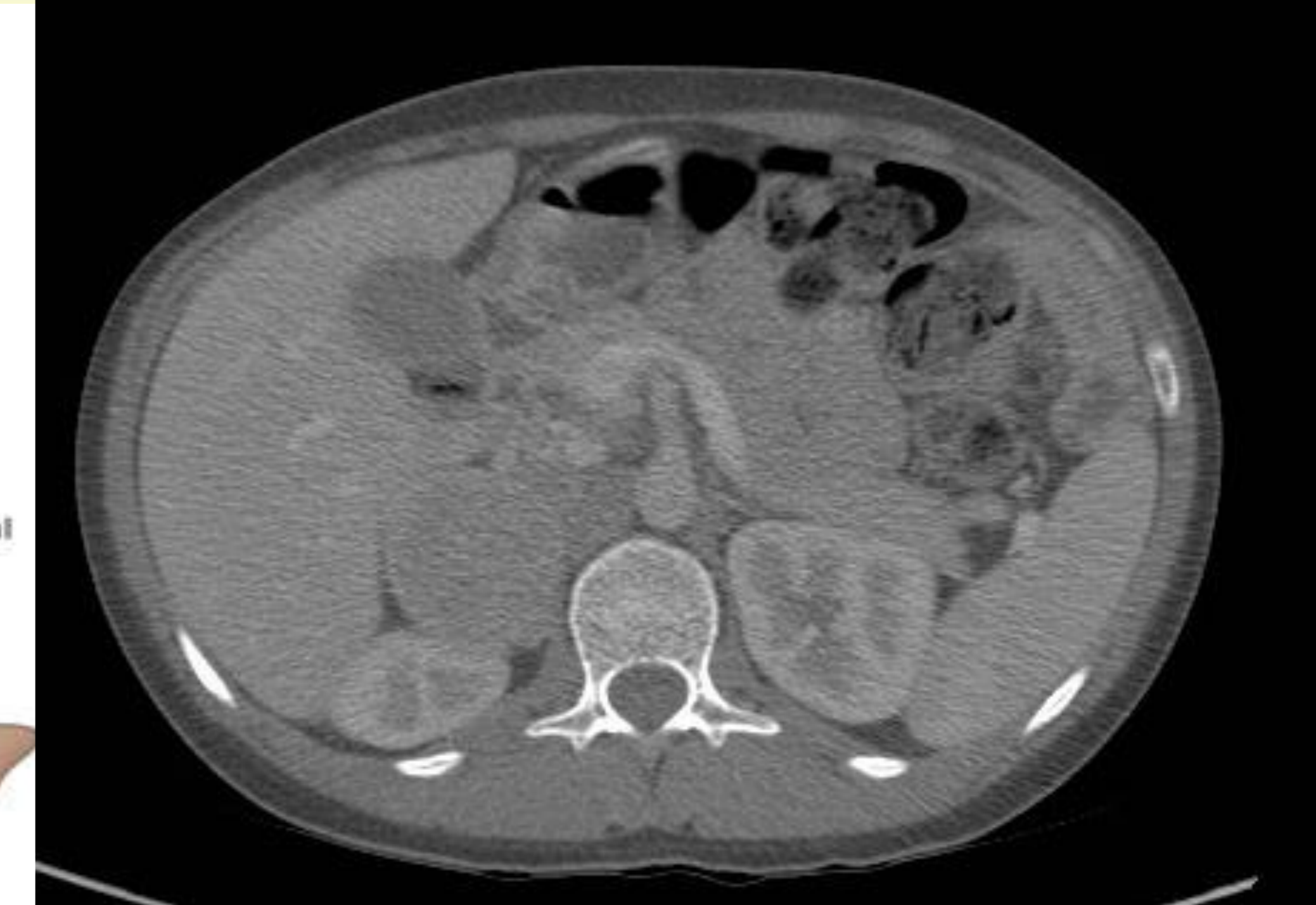MRI showing right sided pheochromocytoma



Fetal placental unit



CT Abdomen and Pelvis post LSCS



Discussion

Reference

The estimated occurrence of pheochromocytoma in pregnancy is 1 in 54,000 pregnancies. Outcomes were poor, but with early diagnosis and proper treatment, maternal and fetal mortality has declined to <5% and <15% respectively from 40-50%. The clinical picture may mimic preeclampsia, with diagnosis of pheochromocytoma being overlooked. Plasma and urinary catecholamine levels can be slightly raised in pregnancy with no increase in morbidity or mortality. An excessive surge of maternal catecholamines, may have deleterious effects on the uteroplacental circulation as extreme vasoconstriction of the vascular bed may possibly result in placental abruption and intrauterine hypoxia, imposing a serious risk to the fetus. During labour, the mother is at risk of cardiovascular compromise due to factors such as labor, abdominal palpation, analgesics, and glucocorticoids which may provoke a hypertensive crisis. Consequently, a high index of suspicion and an early diagnosis is essential to optimize the pregnancy. Plasma and urinary metanephrines are the initial biochemical tests. In pregnancy, MRI is the imaging of choice, as it has the lowest risk of radiation exposure. MIBG scans are avoided, due to the radiation dose to the fetus. If diagnosed before 24 weeks, then surgery should be planned in the second trimester. If not possible, then surgery should be postponed until after delivery, with the mother alpha and beta blocked. Delivery should be by Caesarean section, to reduce the risk of a crisis during labour.

ENDOCRINE DISORDERS IN PREGNANCY: Pheochromocytoma and pregnancy: a deceptive connection
[Jacques W M Lenders^{1,2}](#)
European Society of Endocrinology

