

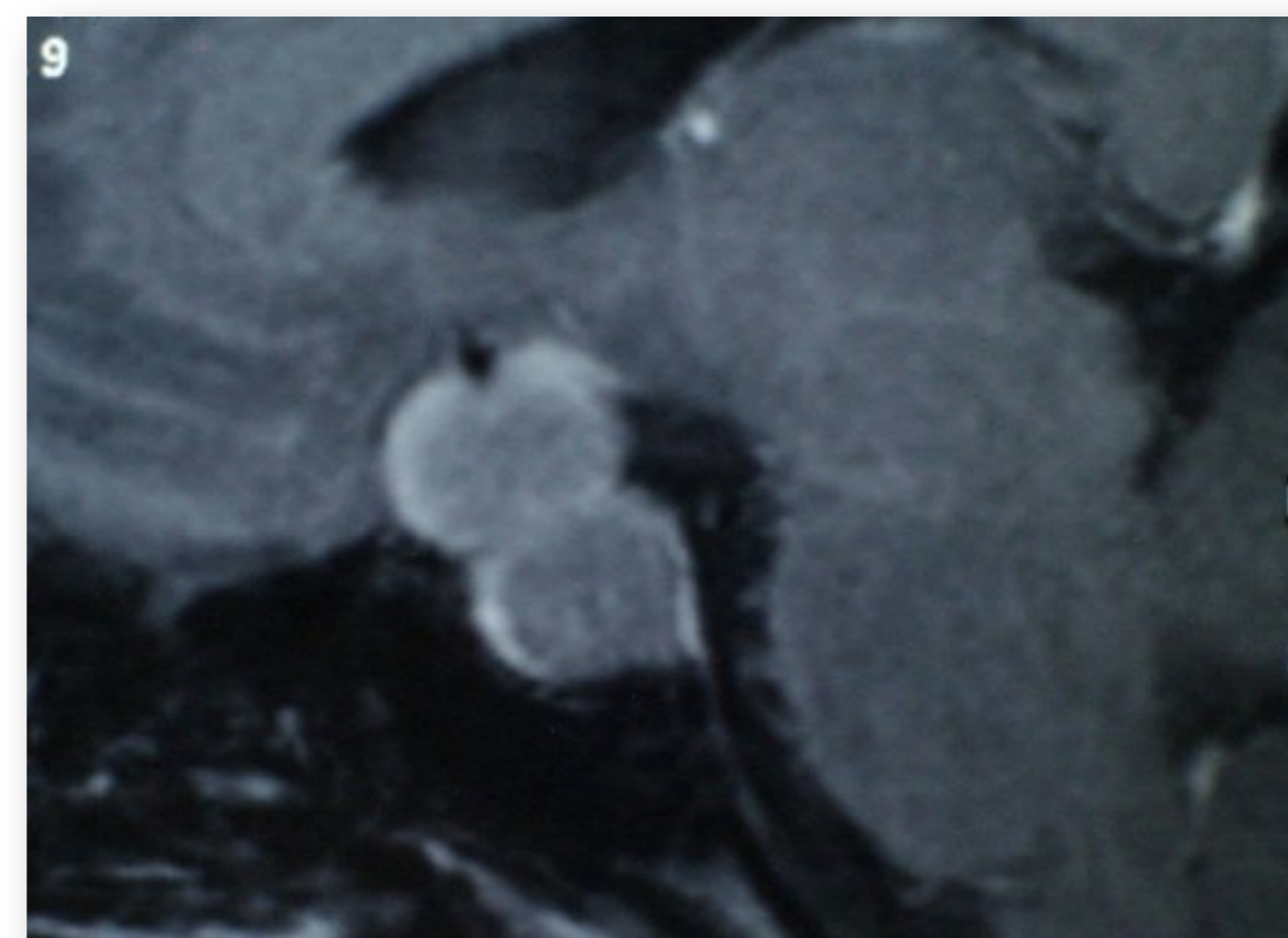
Thyrotropinoma: one tumour, two different clinical presentations.

A. Gómez, S. Maraver, M. Molina, I. Cornejo, A. Muñoz, F. Tinahones.

Endocrinology and Nutrition with Nuclear Medicine Department. Virgen de la Victoria University Hospital. Málaga. Spain

INTRODUCTION

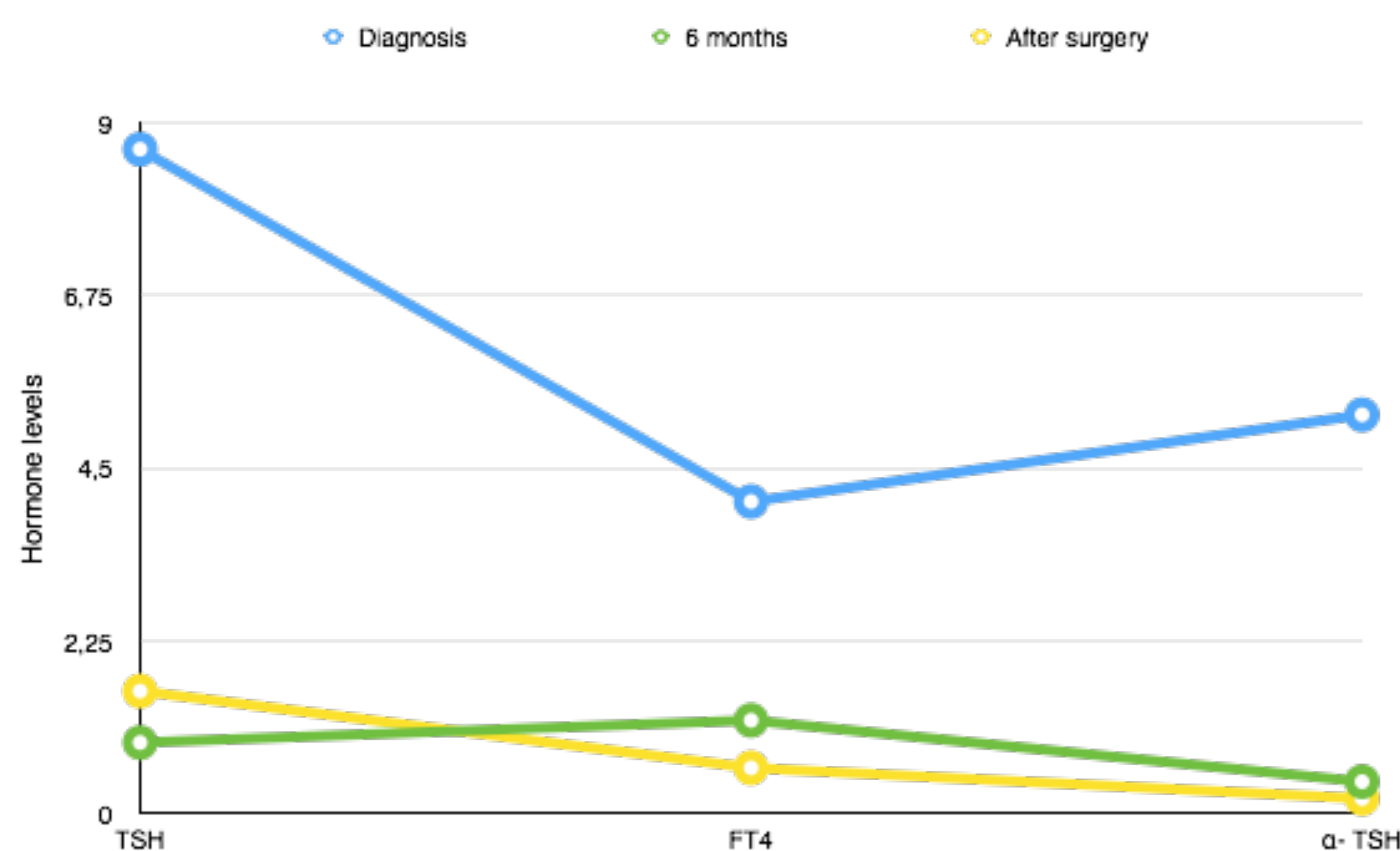
Thyrotropin-secreting pituitary tumors are <1% of pituitary adenomas. Clinical manifestations are similar to other forms of hyperthyroidism. Most of them are diagnosed as macroadenoma (microadenomas <10%).



CASE 1

48 years old woman:

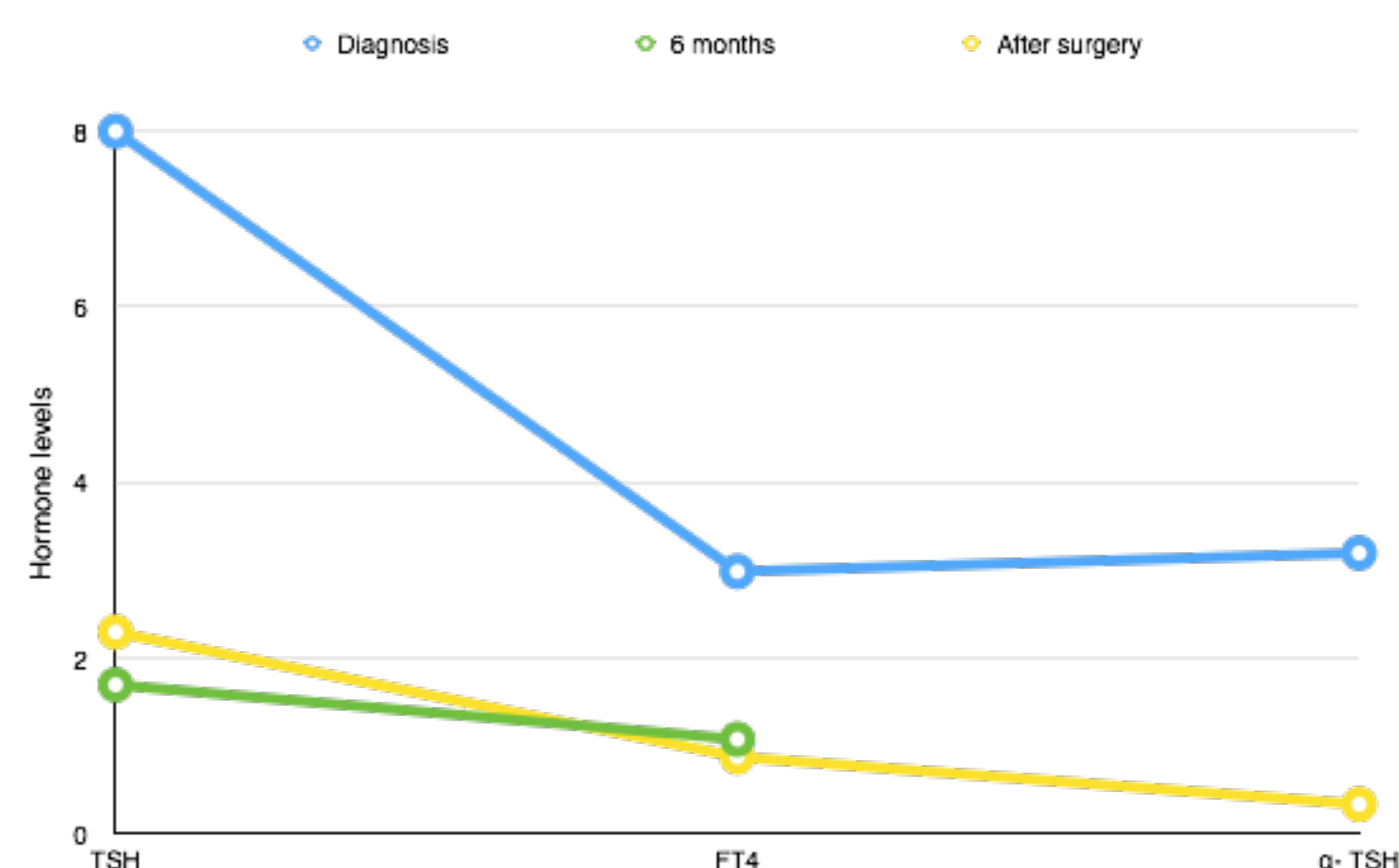
- Menopause presented 6 years ago. Consulting in 2009 for weight loss and palpitations.
- Elastic goiter and distal tremor.
- Blood test: TSH 8.66mcUI/ml (0.2-4.2), FT4 4.7ng/dl (0.7-1.55), FT3 10pg/ml (2-4), α -TSH 5.2UI/L (0.02-0.9), negative antithyroid antibodies, FSH 10.2mUI/ml, LH 4.7mUI/ml, estradiol 28pg/ml and the rest of pituitary hormones in normal range.
- Pituitary MRI: macroadenoma (2cm) with suprasellar invasion, contacting optic chiasm.
- Campimetry: normal.
- Treatment was started: propranolol 30mg/day and octreotide 20mg/28 days.
- Six months after: clinical improvement and restoration of menstruation, TSH 0.93, FT4 1.22, α -TSH 0.42 and slight decrease in tumour size, respecting the optic chiasm (MRI).
- Transsphenoidal surgery in April 2010 \rightarrow immunohistochemistry was positive to TSH-GH.
- Immediate postoperative results: TSH 0.04, FT4 1.1. 8 weeks after: panhypopituitarism (TSH 1.6, FT4 0.6, α -TSH 0.2).
- After 6 months, patient is stable with substitutive treatment and there's no tumour in MRI.



CASE 2

49 years old woman:

- History of complete hysterectomy, consulting in 2008 for TSH 8, FT4 2.99 and positive antithyroid antibodies in a blood test.
- She presented irritability and irregular goiter.
- Pituitary MRI: microadenoma (0.6cm).
- Blood α -TSH 3.2.
- She started octeotide 20mg/28 days.
- After 6 months \rightarrow TSH 1.7, FT4 1.08 and pituitary lesion was stable.
- Transsphenoidal surgery in 2011 with immunohistochemistry positive to TSH.
- 8 weeks postsurgery: TSH 2.3, FT4 0.88, α -TSH 0.34.
- 6 months after, thyroid axis is normal and there's no tumour in MRI.



CONCLUSIONS

We present two different clinical forms of this tumor type, at initial diagnosis and in their postoperative evolution, probably related to tumor size.

However in both cases we observed clinical and analytical response to early medical treatment with somatostatin analogues.