

Descriptive analysis of the histopathologic findings of a series of 1567 thyroidectomies.

D.M. Calderón, M. Delgado, E. Castro, J.J. Alfaro, G. López, J. López, J. Aranda.

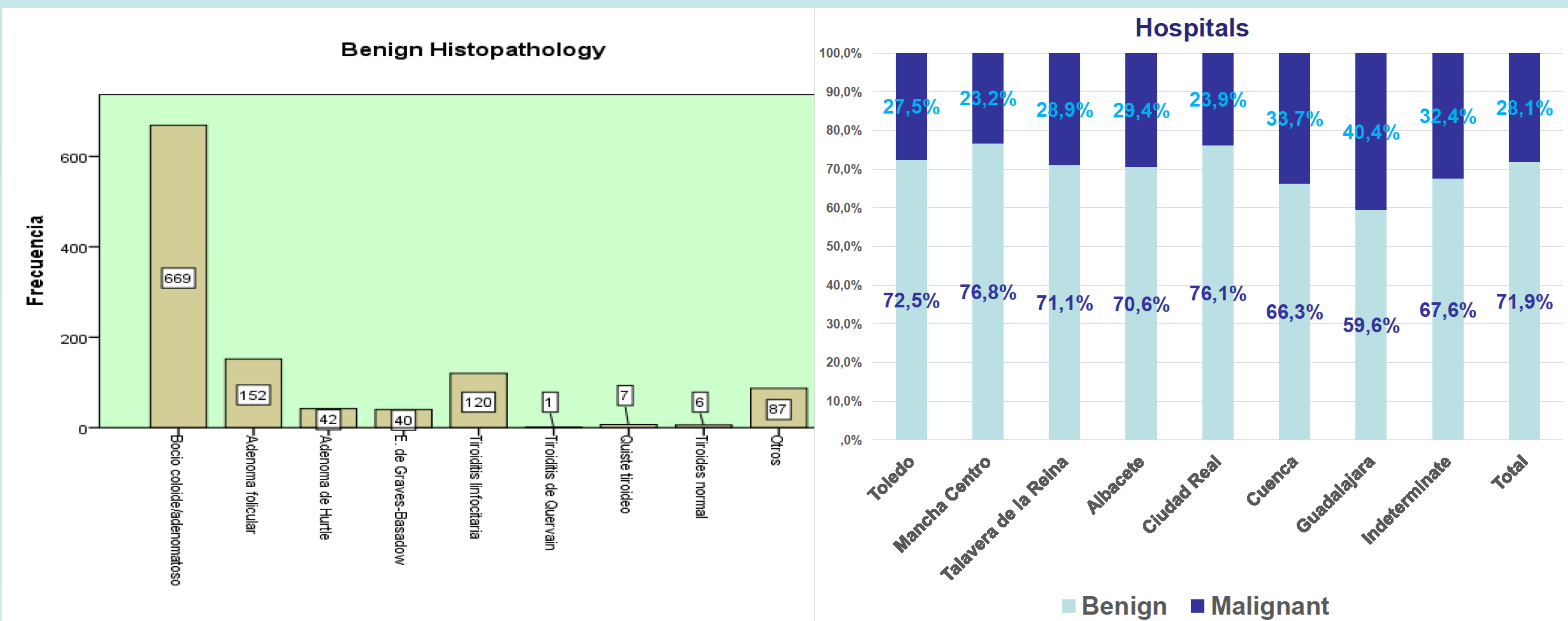
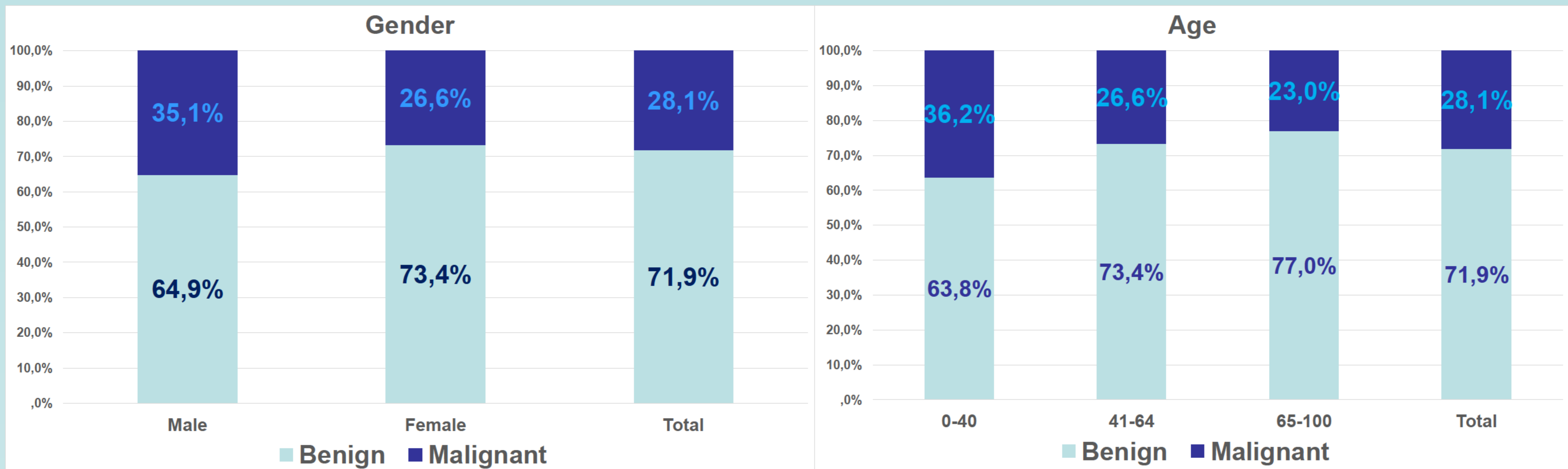
Hospitals of Cuenca, Ciudad Real, Toledo, Albacete, Alcázar de San Juan, Toledo y Cuenca respectively. Spain.

Objectives:

We wanted to analyse the pathology results of thyroidectomies performed in the hospitals of Castilla La Mancha (Spain) between the years 2010-2013, inclusive.

Methods:

A retrospective, multicentered, descriptive study of the histopathologic results of the 1567 thyroidectomies performed in the hospitals of the 8 health districts in our region between the years 2010-2013.



Results:

The histopathologic results were benign in 1124 cases (colloid goiter / adenomatous 42.7%, follicular adenoma 9.7%, Hurthle cell adenoma 2.7%, Graves' disease 2.6%, lymphocytic thyroiditis 7.7%, thyroiditis de Quervain 0.1% , thyroid cyst 0.4%, normal thyroid 0.4%, other 5.6%) and malignant in 402 cases (papillary microcarcinoma 7.5%, macropapilar carcinoma 14.9%, follicular 1.5%, medullar 1.3%, anaplastic carcinoma 0.1%, parathyroid carcinoma 0.1%, other 0.3%), and unknown in 2.6% of cases.

Conclusions:

During the years 2010-2013, 1567 thyroidectomies were performed in the hospitals of Castilla La Mancha. In 1124 cases (71.7%) the histopathology was benign and in 402 cases (25.6%) malignant. The most common tumor was papillary carcinoma.

References:

- Smith JJ, Chen X, Schneider DF, Broome JT, Sipple RS, Chen H, Solórzano CC. Cancer after thyroidectomy: A multi-institutional experience with 1,523 patients. *J Am Coll Surg.* 2013;571-580.
- Raja N, Basharat AK, Ishtiaq AC. Prevalence of malignancy in goitre-A review of 718 thyroidectomies. *J Ayub Med Coll Abbottabad.* 2009; 21(4): 134-136.