

EP-1185

Tatiana Borodich, Larisa Dzeranova, Ekaterina Pigarova, Zhanna Belaya, Elena Przhiyalkovskaya, Maxim Kutin, Alexander Vorontsov, Victoria Vladimirova, Elena Averkieva, Ludmilaya Rozhinskaya
Endocrinology Research Centre, Moscow, Russian Federation

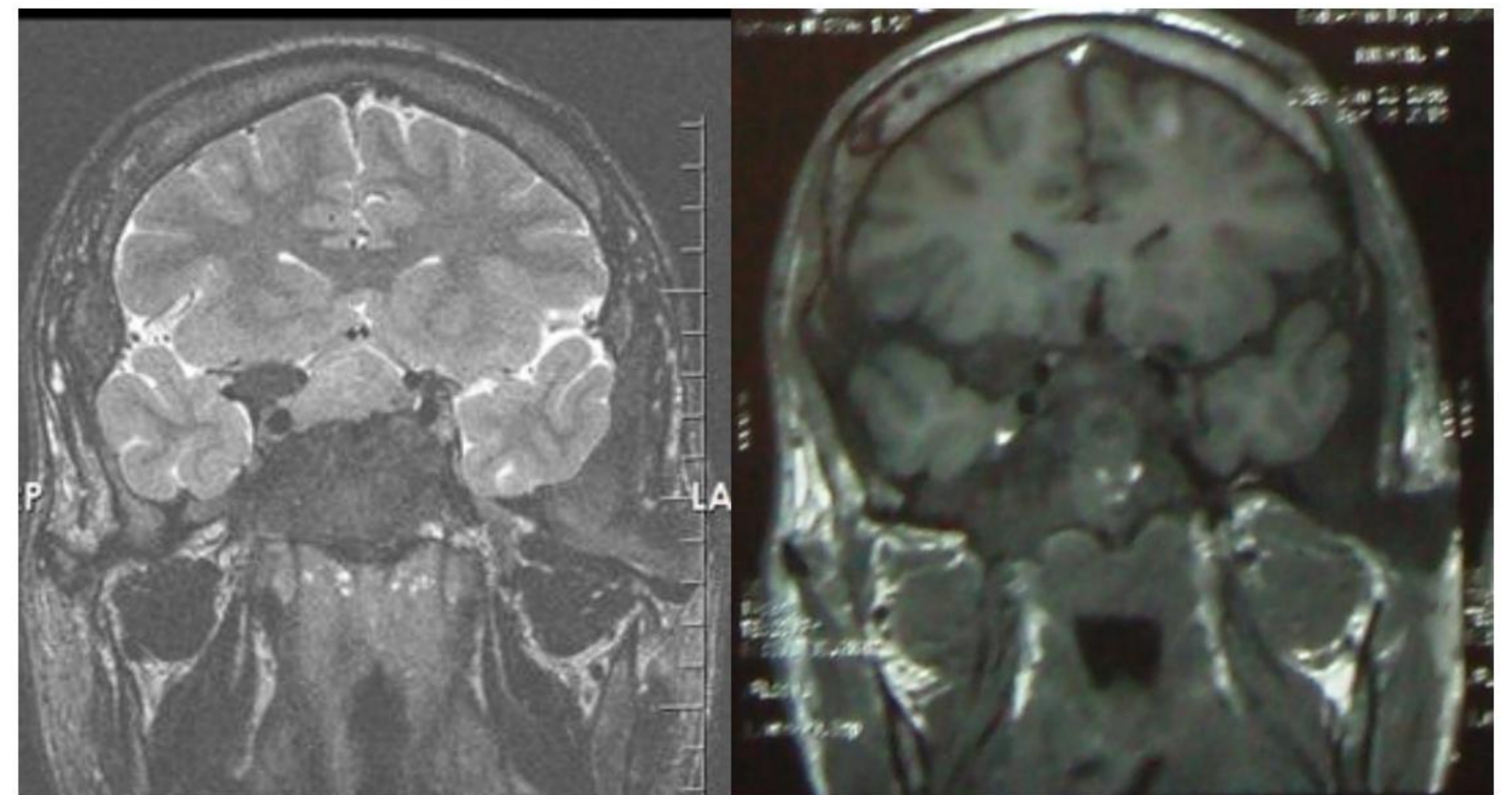
Case report

A 27 – y. o. male patient during past 10 years noted a gradual change in his appearance, but began to seek a medical attention only 1.5 years ago due to reduced vision.

In April 2014, at admission to Endocrinology Research Centre at the age of 27 years the patient was 205 cm tall and weighed 124 kg (BMI 29.5 kg/m²), the patient was 205 cm tall and weighed 124 kg (BMI 29.5 kg/m²). "Café au lait" pigmentation of the skin was noted at the chest, back, and abdomen. His facial features were acromegaloid with sloped towered skull. All these symptoms allowed us to suspect a McCune-Albright (MAS) syndrome. The progressive clinical course of the disease, insensitivity to octreotide treatment was the basis for the choice of further surgical treatment despite the pronounced fibrous dysplasia of the skull base. In October 2014 at Burdenko Neurosurgical Research Institute the patient underwent endoscopic endonasal removal of tumor using navigation BrainLab.

Date of MRI or CT with contrast	Results
March 2013 (MRI)	Adenoma of the anterior part of the pituitary, size 4x7 mm
March 2013 (CT)	Poliostic dysplasia of the skull bones
April 2014 (MRI)	Adenoma size 17x23x14 mm and progression of the fibrous dysplasia
October 2014 (postoperatively)	Visual function had markedly improved

MRI before and after surgery



Conclusions

The treatment of acromegaly in the setting of MAS is characterized by multiple challenges that require the participation of a team of experienced endocrinologists and neurosurgeons.

Date/Hormonal test	GH mIU/l	IGF-1 ng/ml	Testosterone ng/ml	Cortisol, LH, FSH, PRL
March 2013	106 (<20)	567 (<336)	1.91 (3-12)	normal
September 2013	octreotide depo intramuscular injections 10 → 20 mg/28d			
January 2014	119	1033		
April 2014	117	1412		
October 2014 (postoperatively)	27	856		
April 2015	octreotide depo intramuscular injections 30 mg/28 days and cabergoline 2 mg/week			

This work was supported by grant of the President of the Russian Federation MK-5411-2014.7.

