

Mosaic form of Turner's can be associated with normal stature and spontaneous puberty: a case report

Julie Park , Ignatius Losa Department of Paediatrics
Macclesfield District General Hospital, UK

BACKGROUND

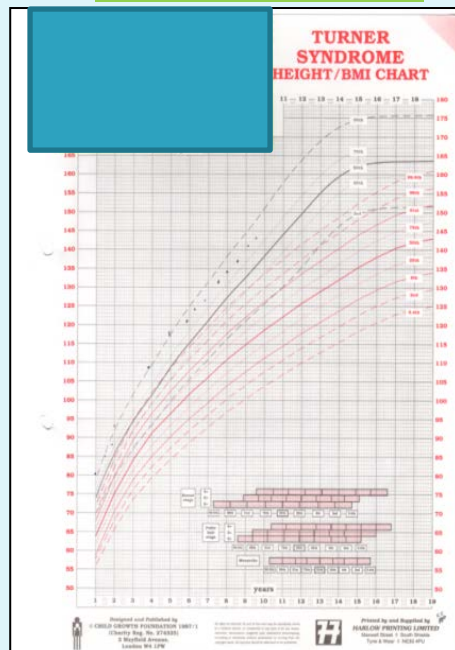
Turner's syndrome is the most common sex chromosome abnormality in females resulting from a 45,X cell line. A mosaic chromosomal complement (eg 45,X/46,XX) is detectable in over half of all patients with Turner's. Characteristically girls with Turner syndrome have a short stature attributable to the presence of *SHOX* (short stature homeobox-containing gene on the X chromosome) gene¹. Most affected women have no pubertal development and primary amenorrhea due to premature ovarian failure. There is a paucity of literature reporting Turner girls with normal height and spontaneous puberty. We describe a girl with mosaic form of Turner's with normal stature achieving spontaneous puberty

CASE

An 11-year old girl was diagnosed with Turner's syndrome by amniocentesis and confirmed postnatally. Amniocentesis was performed due to maternal age. A karyotype of 45,X[19]/46,XX[11] confirmed a mosaic form of Turner's. Phenotypically she had dysplastic nails and a left accessory nipple. However, her renal ultrasound scan and cardiac ECHO were normal. Her thyroid function is normal. She receives support for mathematics. There are no other known learning difficulties. Dad is 180.34 cm. Mum is 170 cm. The mid-parental height is 168cm and target centile range is between the 25th and 98th.

Our patient's height remains on the 91st centile. Her weight is on 25th centile. Pubertal changes occurred at 10 years of age with spontaneous menarche at 10.6 years. Baseline gonadotropins were elevated; FSH of 8.9 iu/L, and LH of 2.6 iu/L. A GnRH test performed at 15 months of age showed an exaggerated FSH response. Her Anti- Mullerian Hormone is 16.36pmol/L (2.56-17.0pmol/L) suggesting low ovarian reserve. Her family have been counselled regarding the possibility of premature ovarian failure.

GROWTH CHART



GnRH results(aged 15 months)

Time(mins)	LH(iu/L)	FSH(iu/L)
0	1.4	9.7
30	10.7	51.3
60	10.0	71.6

CONCLUSION

Mosaic forms of Turner's syndrome may not show problems related to growth. Antenatal screening may change our perception of Turner's aiding appropriate counselling and follow up.

References:

- 1.Sybert VP, McCauley E Turner's syndrome. N Engl J Med. 2004 Sep 16;351(12):1227-38.
- 2.Hong YH, Shin YL Turner syndrome masquerading as normal early puberty. Ann Pediatr Endocrinol Metab. 2014 Dec;19(4):225-8. doi: 10.6065/apem.2014.19.4.225. Epub 2014 Dec 31.
- 3.Carpini S , Carvalho AB, Guerra-Júnior G, Baptista MT, Lemos-Marini SH, Maciel-Guerra AT. Spontaneous puberty in girls with early diagnosis of Turner syndrome. Arq Bras Endocrinol Metabol. 2012 Dec;56(9):653-7.