

Central/peripheral vascularization and resistance index at Doppler ultrasound examination of thyroid nodules. Are they useful to differentiate between benign and malignant pathology?

Pacenza NA¹, Rosmarin M¹, Blanc E¹, Serrano S², Cejas C³, Sforza N¹, Serrano L⁴, Campero A³, Frid S¹, Faingold MC¹, Brenta G¹

Departments of Endocrinology and Metabolism¹, Pathology², Radiology³ and Surgery⁴ of "Dr César Milstein" Hospital, Buenos Aires, Argentina
e-mail: napacenza@yahoo.com.ar

INTRODUCTION

Thyroid Doppler ultrasound (TDUS) is highly used in the evaluation of thyroid nodules (TN)¹. Malignant thyroid pathology has been more frequently associated with central vascularization of such nodules. There is controversy regarding to the usefulness of the Resistance Index (RI) in the assessment of TN^{2,3}.

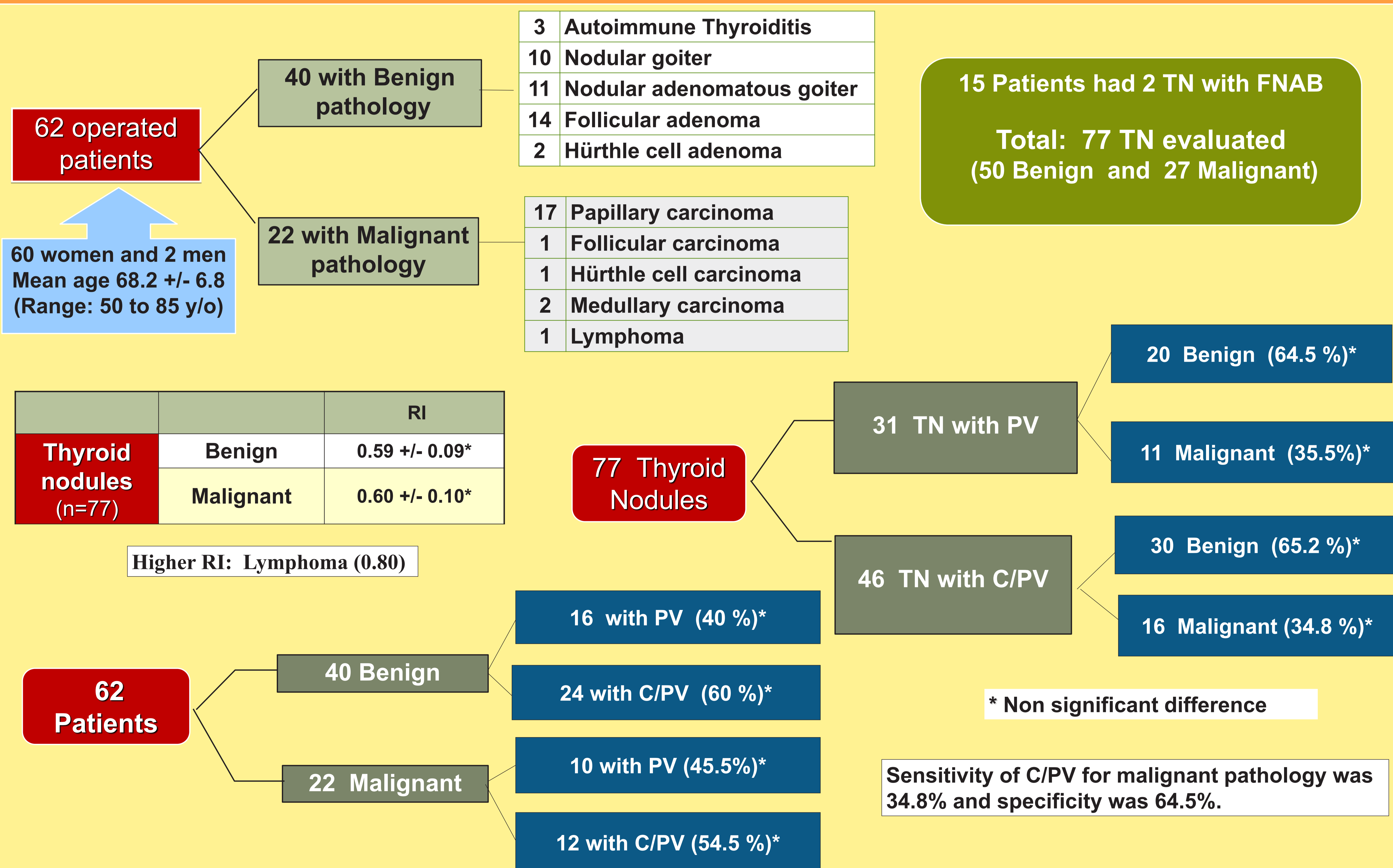
OBJECTIVE

Our aim was to analyze the utility of vascularization characteristics and RI at TDUS in the distinction of benign and malignant TN.

PATIENTS AND METHODS

Characteristics of peripheral vascularization (PV) or central and peripheral vascularization (C/PV), and RI (estimated by blood flow speed at the prominent artery at TDUS) were analyzed in all patients who underwent thyroid surgery and had an US-guided fine needle aspiration biopsy (FNAB) performed in our institution since June 2011 to November 2015.

RESULTS



CONCLUSION

In our experience, characteristics of vascularization (peripheral or central and peripheral) and the RI of TN at TDUS alone were not useful to distinguish between benign and malignant pathology in our population.

BIBLIOGRAPHY

- 1) Risk of Malignancy in Nonpalpable Thyroid Nodules: Predictive Value of Ultrasound and Color-Doppler Features. Papini E. *JCEM* 87(5):1941-46, 2002.
- 2) Vascular Pattern and Spectral Parameters of Power Doppler Ultrasound as Predictors of Malignancy Risk in Thyroid Nodules. Bakhshae M. *Laryngoscope* 118: 2182-86, 2008.
- 3) Thyroid Ultrasound Features and Risk of Carcinoma: A Systematic Review and Meta-Analysis of Observational Studies. Remonti L. *Thyroid* 25 (5):, 2015.