

An adrenal vascular cyst masquerading as malignancy

A Case Report

S.S Seshadri, S Krishnan, A Mathews, J Mathews

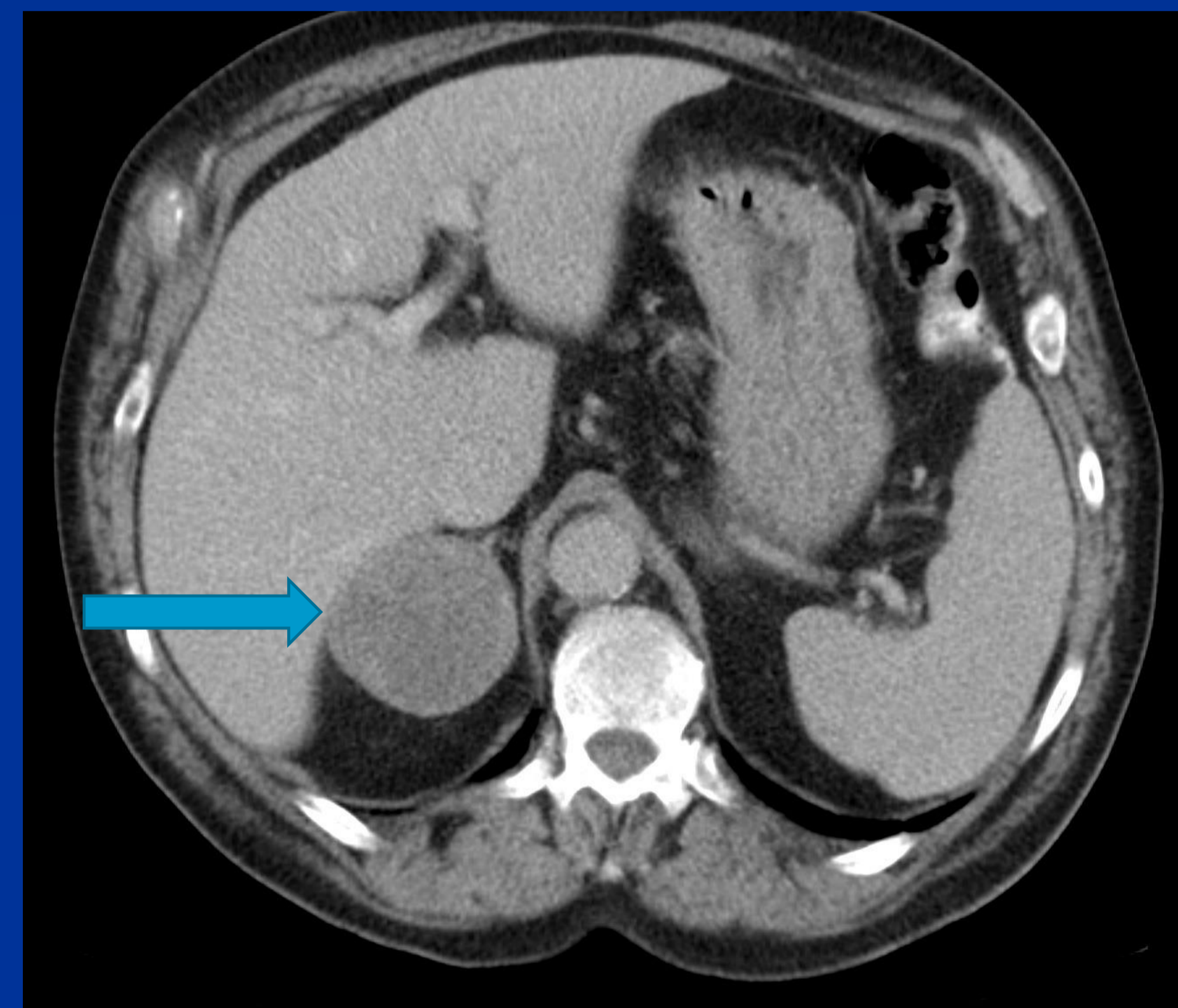
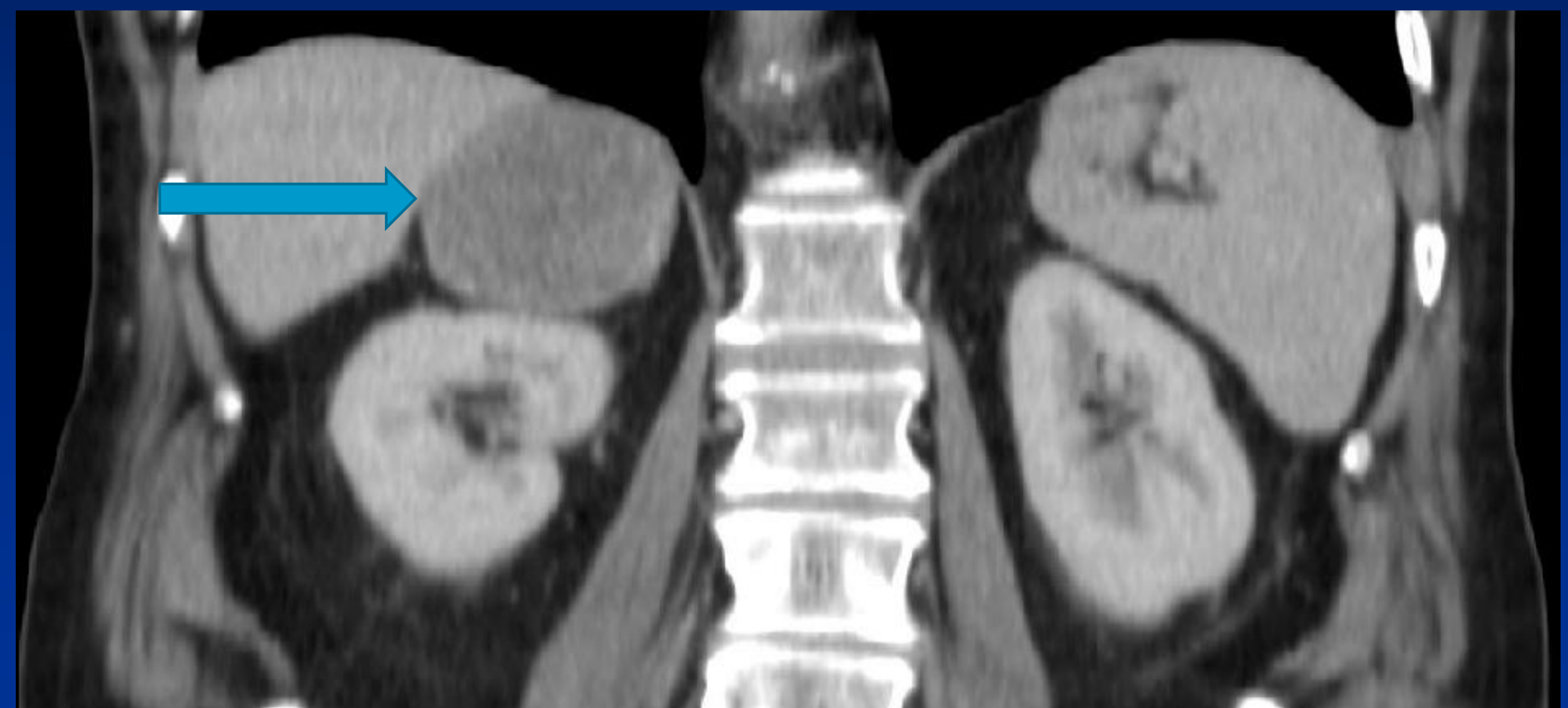Department of Endocrinology, Hinchingsbrooke Hospital, Huntingdon, UK

INTRODUCTION

Adrenal vascular cysts are rare, in most cases incidentally discovered during abdominal imaging for other reasons. We present a case of adrenal endovascular cyst with initial suspicious features of malignancy and subsequent complications and management thereof.

CASE REPORT

- A 72 year old male was admitted with weight loss over 2 months and a new onset fever with rigors and right leg pain. He was noted to have an abdominal mass. He was treated along the lines of urosepsis. An ultrasound of his legs revealed femoral and popliteal aneurysms while an ultrasound of his abdomen revealed a large adrenal mass of 25 cms.
- A past history of well controlled hypertension was evident and hormonal work up revealed normal adrenal reserve and serum aldosterone, renin and metadrenaline within the reference range. A CT scan confirmed the adrenal mass with displacement of the liver and some IVC compression and this had increased in size significantly from 6cms ,5 years ago.
- The patient was referred to a tertiary centre for further management. However he presented 2 weeks later with abdominal pain and hypotension. A repeat CT scan showed rupture of the mass with haemorrhage into itself and also evidence of bleeding into the peritoneum. He was empirically treated with steroids and transferred to the tertiary centre for emergency surgery and mass removal.
- Histology subsequently revealed haemorrhage and necrosis from rupture of a large adrenal pseudo cyst which stained negative for immunohistochemistry for necrotic tumour cell population but with presence of a focal vascular lining suggesting an adrenal endovascular cyst.



EPIDEMIOLOGY

- Adrenal cysts are rare and form a heterogeneous group of lesions that include parasitic cysts, epithelial cysts, pseudocysts and endothelial cysts.
- Their incidence in autopsy series is 0.06%¹
- Adrenal vascular cysts comprise the majority of the non neoplastic adrenal cysts (84%).
- Patients with adrenal vascular cysts tend to present in their fifth or sixth decades with women outnumbering men(3:1).
- Unilateral in majority and bilateral in 8%.
- Grossly adrenal vascular cysts are well circumscribed with a capsule.
- Sizes vary from 1.4 to 33cms in diameter.

CLINICAL PRESENTATIONS

- Abdominal pain (35%)³
- Incidental lesions (32%)³
- Hypertension resolving following removal of tumour
- Acute abdomen and shock rarely²
- Surgical excision is the treatment of choice for vascular adrenal cysts and offers an excellent prognosis⁴

CONCLUSION

Rare adrenal vascular cysts should be considered in the differentials of adrenal masses. Prompt surgical removal after imaging and appropriate hormonal assessments can avoid complications like rupture and bleeding.

REFERENCES

1. Carvounis et al :Vascular adrenal cysts: Arch Pathol Lab med.2006:130:1722-1724.
2. Pasciak RM et al,Massive retroperitoneal bleeding due to a ruptured adrenal cyst, J Urol.1988; 139: 98-100.
3. Torres C et al, Vascular adrenal cysts : a clinicopathologic and immunohistochemical correlation of 6 cases : Mod Pathol,1997: 10:530-536.

Hinchingsbrooke Health Care NHS Trust

