

Background

Pregnancy with Cushing syndrome (CS) is rare because infertility is associated with hypogonadotropic hypogonadism by cortisol and androgens excess. Here we reported the cases of CS that presented signs and symptoms of CS after delivery.

Case Report

The first case is a 30-year-old woman who presented 8 months after second baby delivery amenorrhea even though she stopped breastfeeding. For 3 months before her visit, she gained weight and had easy bruisability. She had a history of gestational diabetes. On physical examination, she had moon face, buffalo hump and abdominal striae with purple colored pigmentation. Urine hCG was negative. Plasma adrenocorticotrophic hormone (ACTH) was high and low dose dexamethasone test was not suppressed. The brain magnetic resonance image showed a 6 mm sized adenoma in the left side of pituitary gland. A transsphenoidal adenomectomy was performed. Shortly after operation, she had adrenal insufficiency. However, 5 months later, clinical symptoms improved and her pituitary-adrenal function was normalized.

	Baseline	Low dose DST	High dose DST
ACTH(pg/mL)	149.42		
Plasma cortisol(μg/dL)	48.97	8.95	1.91
Urine free cortisol(μg/day)	85.87	1.51	1.12

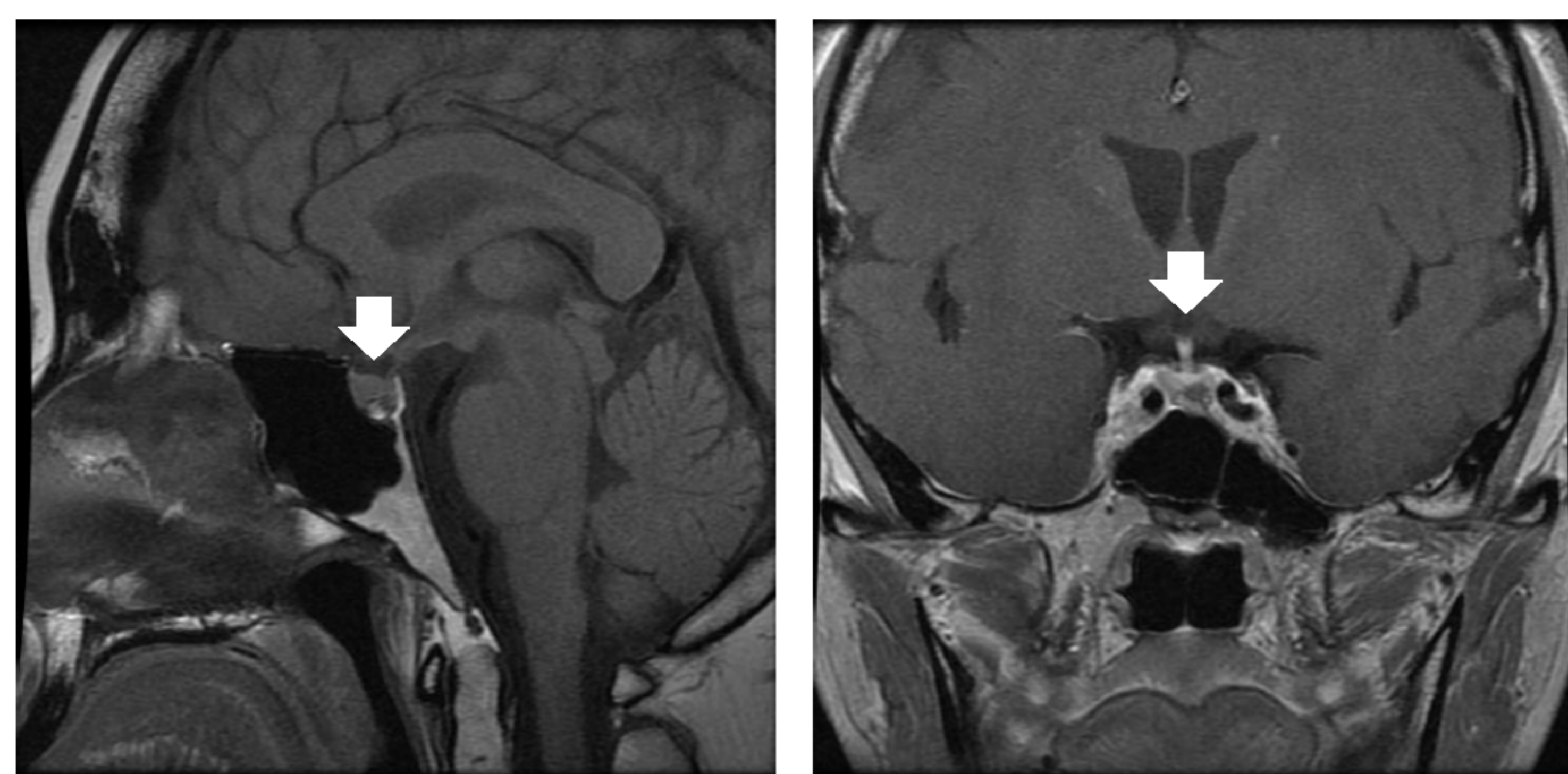


Figure 1. Brain MRI findings

	Pre operative	Post operative 1st day	Post operative 5th day	Post operative 5th month
ACTH(pg/mL)	149.42	20.43	14	28.4
Plasma cortisol(μg/dL)	48.97	76.24	1.18	8.13
Urine free cortisol(μg/day)	85.87			1.63

The second case is a 33-year-old woman who presented 5 months after delivery 14 kg weight gain. She was diagnosed with hypertension 3 years ago. On physical examination, she had moon face, acne, hirsutism, central obesity and abdominal striae. 75g oral glucose tolerance test showed diabetes. Plasma ACTH was normal and low dose dexamethasone test was not suppressed. Other hormone related adrenal gland was normal. The abdominal computed tomography showed 35mm sized enhancing mass in the right adrenal gland. Laparoscopic adrenalectomy was performed and she took hydrocortisone for adrenal insufficiency, anti-hypertensive drug for hypertension and metformin for diabetes. 1 year after operation, clinical symptoms and metabolic parameters were normalized and she stopped all medications.

ACTH	12.07		
Low dose dexamethasone	1	2	3
Cortisol	14.85	15.02	21.22
24hr urine free cortisol (1.49-8.20)	40.02	35.48	38.51
17-OHCS	30.2	27.8	30.1
17-KS	13.09	10.44	10.88
Cr(urine)	1.038	964	1.020

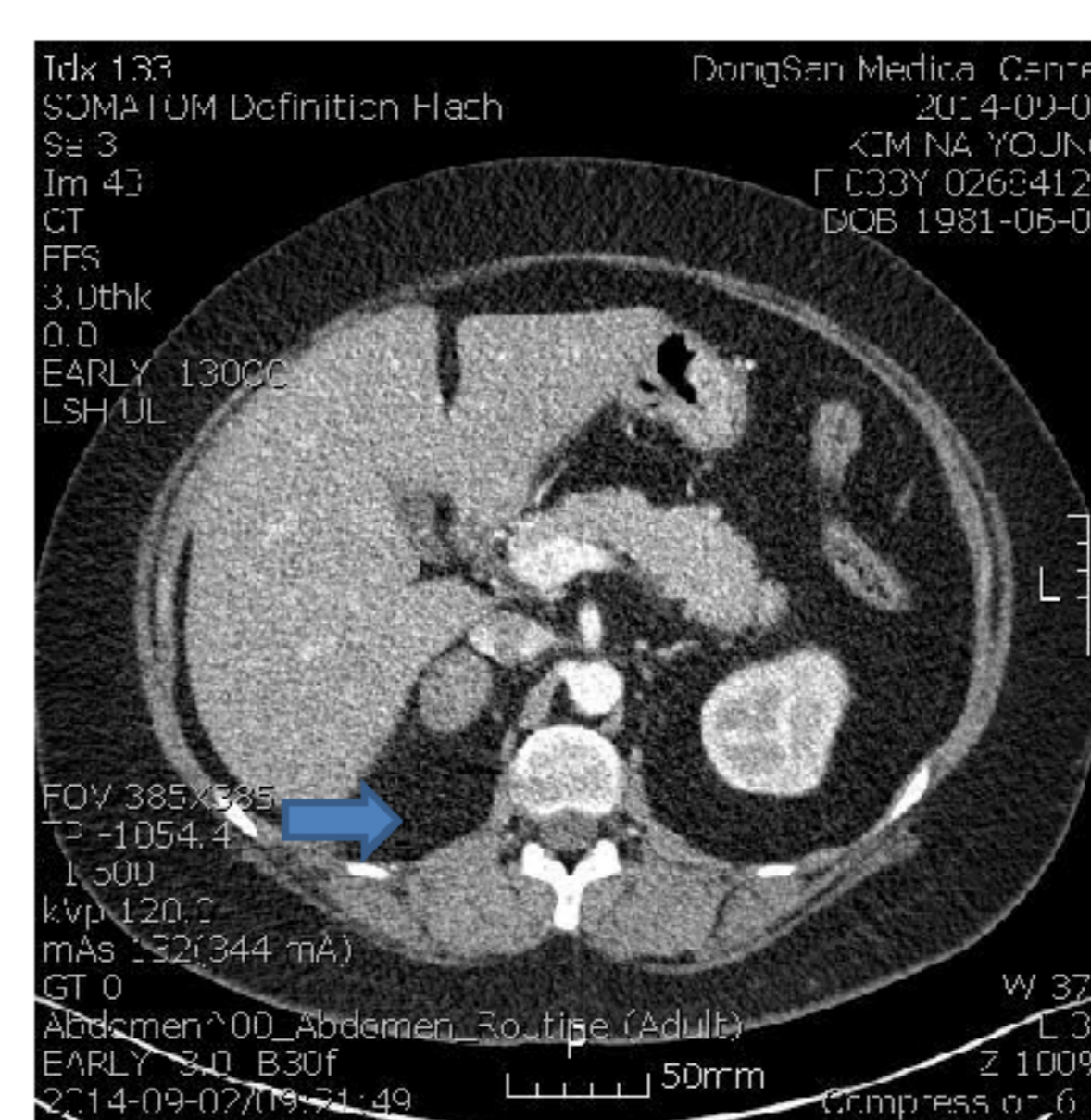


Figure 2. Abd. CT findings

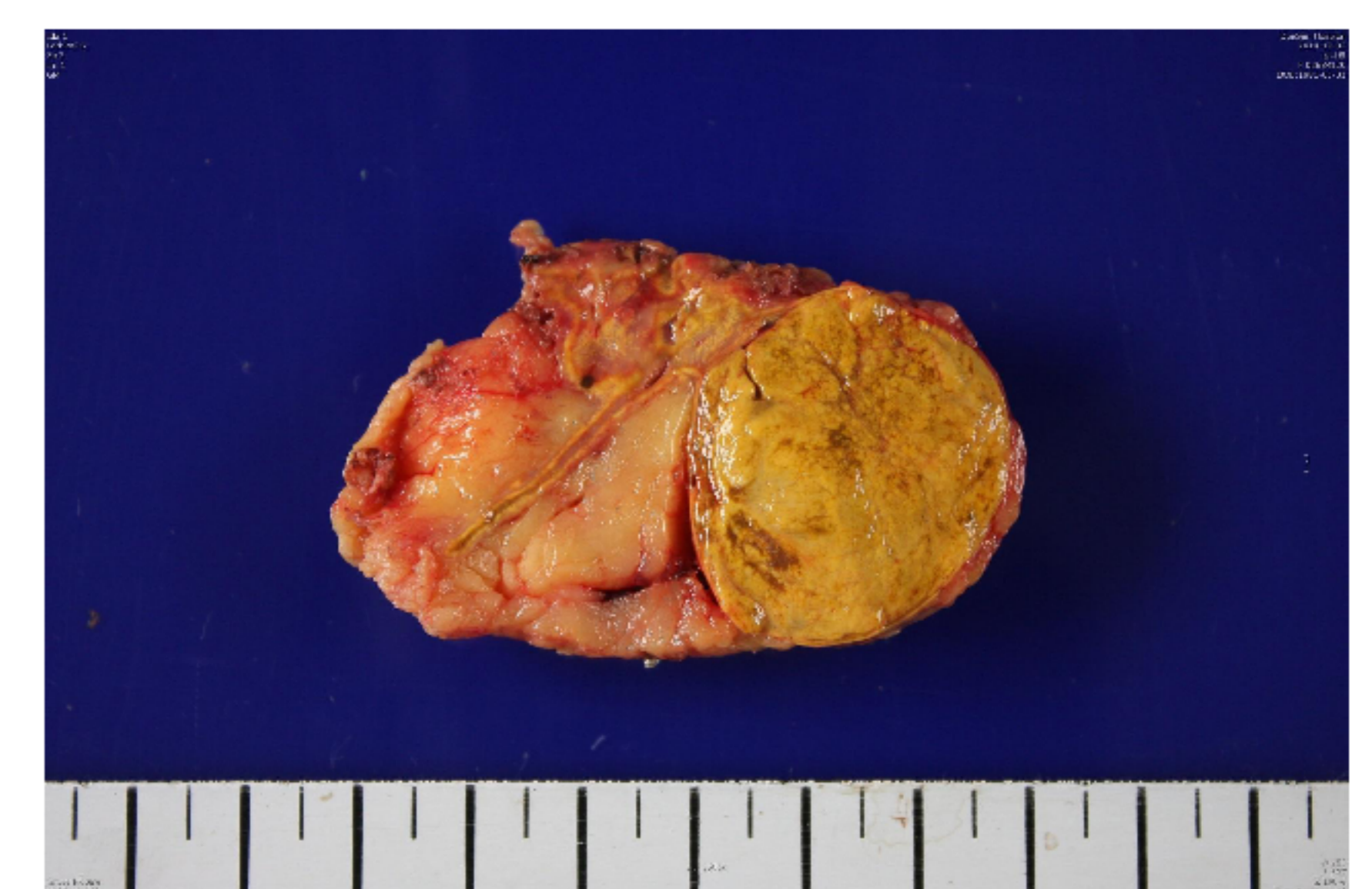


Figure 3. Gross photo

Conclusion

CS with pregnancy is rare. We reported cases that manifested CS after delivery and resolved after operation.

Reference

Best Pract Res Clin Endocrinol Metab.2011 Dec;25(6):861-73.
Endocrine disorders & female infertility. Unuane D, Tournaye H, Velkeniers B

