

Graves' Orbitopathy and Graves' Disease after bone marrow transplant in a patient with Fanconi Anemia

Cima Luminita Nicoleta¹, Stejereanu Lavinia¹, Lambrescu Ioana Maria¹, Colita Anca^{1,0}, Barbu Carmen Gabriela^{1,2}, Fica Simona^{1,2}

¹Carol Davila University of Medicine and Pharmacy, Bucharest

²Endocrine Department, Elias Hospital, Bucharest

⁰Hematology Department, Fundeni Hospital, Bucharest

Introduction

Endocrinopathies are a common late effect of haematopoietic stem cell transplantation, resulting in thyroid dysfunction, impaired growth and pubertal development during childhood and metabolic syndrome. Because of the possible endocrine complications, transplanted patients need life-long endocrine follow-up.

Case Report

F.S., M, 14 years old

Medical history

- ❖ 2009 (7 ys)-diagnosed with Fanconi anemia and ectopic right kidney;
- ❖ 2012 (10 ys)-Bone marrow transplant (BMT);
 - Immunosuppressive treatment with glucocorticoids and mycophenolate mofetil;
- ❖ May 2015- diagnosed with Graves' Disease- (TSH<0.004uIU/ml, FT4=4.44ng/ml, ATPO=324 IU/ml, TRAb=28U/l) and started treatment with metimazole(MMI); no eye signs of Graves' ophthalmopathy;
- ❖ Nov 2015- upper eyelids swelling, retraction of the lower eyelids, discrete eyelids erythema, mild exophthalmia, especially at his left eye;

Thyroid ultrasound: enlarged, hypervascular thyroid gland with heterogeneous thyroid echotexture.

Ophthalmological consultation diagnosed evolutive orbitopathy and suggested considering glucocorticoid therapy.

TRAb=14.2U/l

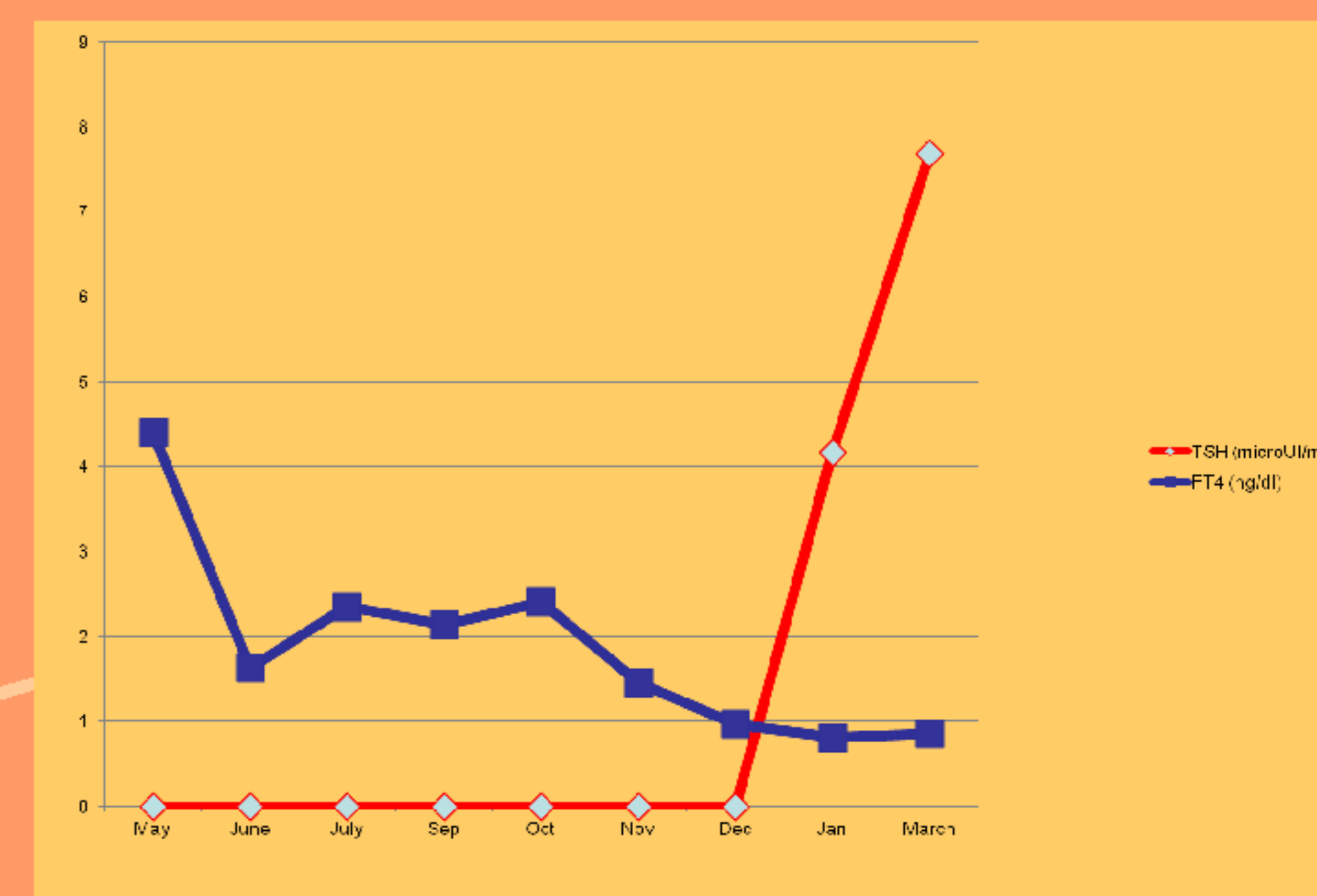
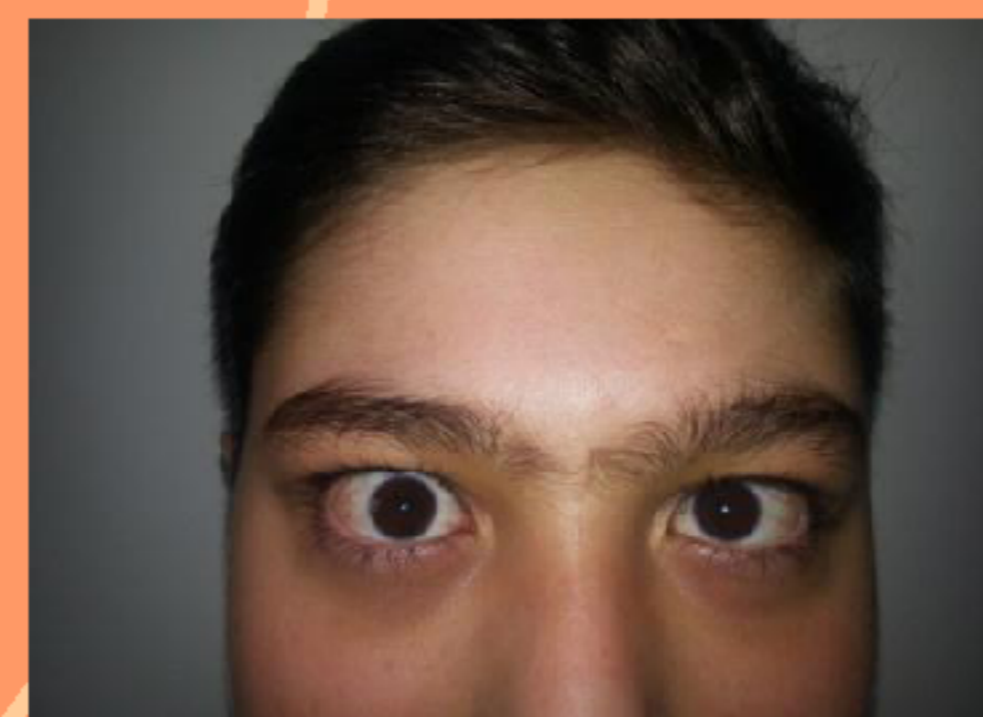


Figure 1. The evolution of FT4 and TSH on antithyroid drugs

He started a 6-months course of selenium supplementation (100ug/day) and pulsetherapy with Methyprednisolone 125 mg/week for 3 weeks and 250 mg/week for the next 3 weeks with a good clinical outcome.

Discussion

After the BMT, both occurrence and remissions of Graves' disease have been reported. According to Weetman, most cases of Graves' disease which follow BMT are probably the result of adoptive immunity, in which clones of autoreactive T cells from a donor with Graves' disease expand in the recipient, but there is also some evidence that link disordered immunoregulation due to graft-versus-host with expansion of clinically silent autoreactive donor lymphocytes to produce autoimmune disease in the recipient.

Conclusions

Graves' orbitopathy is a rare complication in transplanted patients and was not present in our patient from the start.

The keypoint resides in the fact that transplanted patients need life-long endocrine follow-up because of the possible endocrine complications that can occur as a result of pathological clones either transmitted or self-originated even a few years after BMT.

References:

1. Vardizer, Y., et al., Graves' orbitopathy in a patient with adrenoleukodystrophy after bone marrow transplantation. *Eur J Endocrinol*, 2009. 161(2): p. 369-73.
2. Berisso, G.A., et al., Adoptive autoimmune hyperthyroidism following allogeneic stem cell transplantation from an HLA-identical sibling with Graves' disease. *Bone Marrow Transplant*, 1999. 23(10): p. 1091-1092.
3. Hsiao, L.T., et al., Relapse of Graves' disease after successful allogeneic bone marrow transplantation. *Bone Marrow Transplantation*, 2001. 28(12): p. 1151-1153.
4. Weetman, AP, Graves' disease following immune reconstitution or immunomodulatory treatment: should we manage it any differently? *Clin Endocrinol (Oxf)*, 2014. 80(5): p. 629-32.
5. Sherer Y and Y. Shoenfeld, Autoimmune disease and autoimmunity post bone marrow transplantation. *Bone Marrow Transplantation*, 1998. 22(9): p. 873-881.
6. Patriarca, F., et al. The development of autoantibodies after allogeneic stem cell transplantation is related with chronic graft-vs-host disease and immune recovery. *Exp Hematol*, 2006. 34(3): p. 389-396.

