

Recurrent pancreatitis and an ectopic parathyroid- an unsavoury combination

Seshadri S, Kazmi K, Krishnan S

Department of Endocrinology, Hinchingsbrooke Hospital, Huntingdon

INTRODUCTION

Pancreatitis due to hypercalcemia from primary hyperparathyroidism is rare with an incidence of 1 to 1.5 %. We report on a case of recurrent pancreatitis secondary to an ectopic parathyroid adenoma with co-existing severe Vitamin D deficiency with its management difficulties.

Case Report

A 45 years old male was admitted to the hospital under surgical team with abdominal pain and nausea. The amylase levels were raised. CT abdomen showed pancreatic oedema consistent with acute pancreatitis. This was managed conservatively.

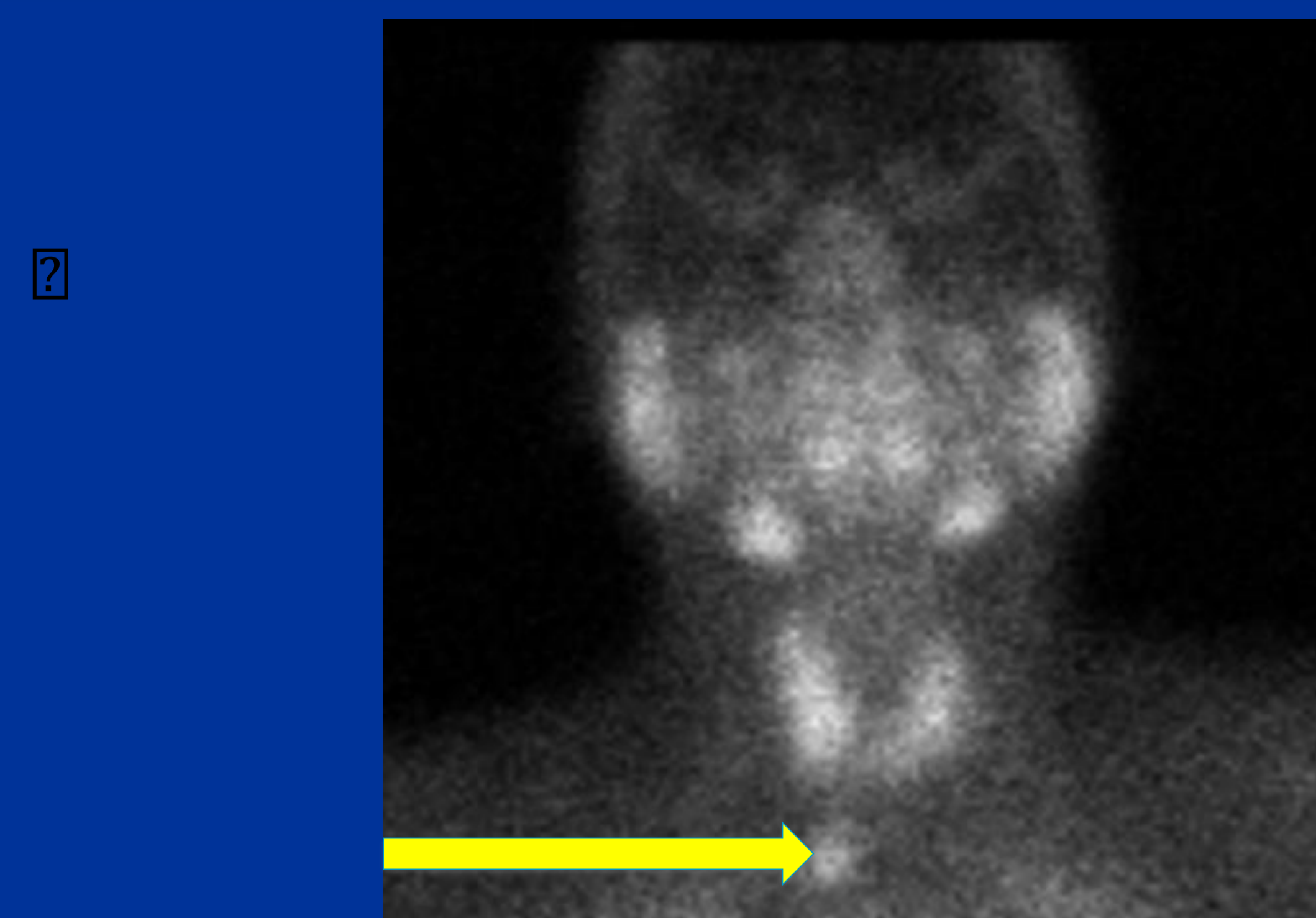
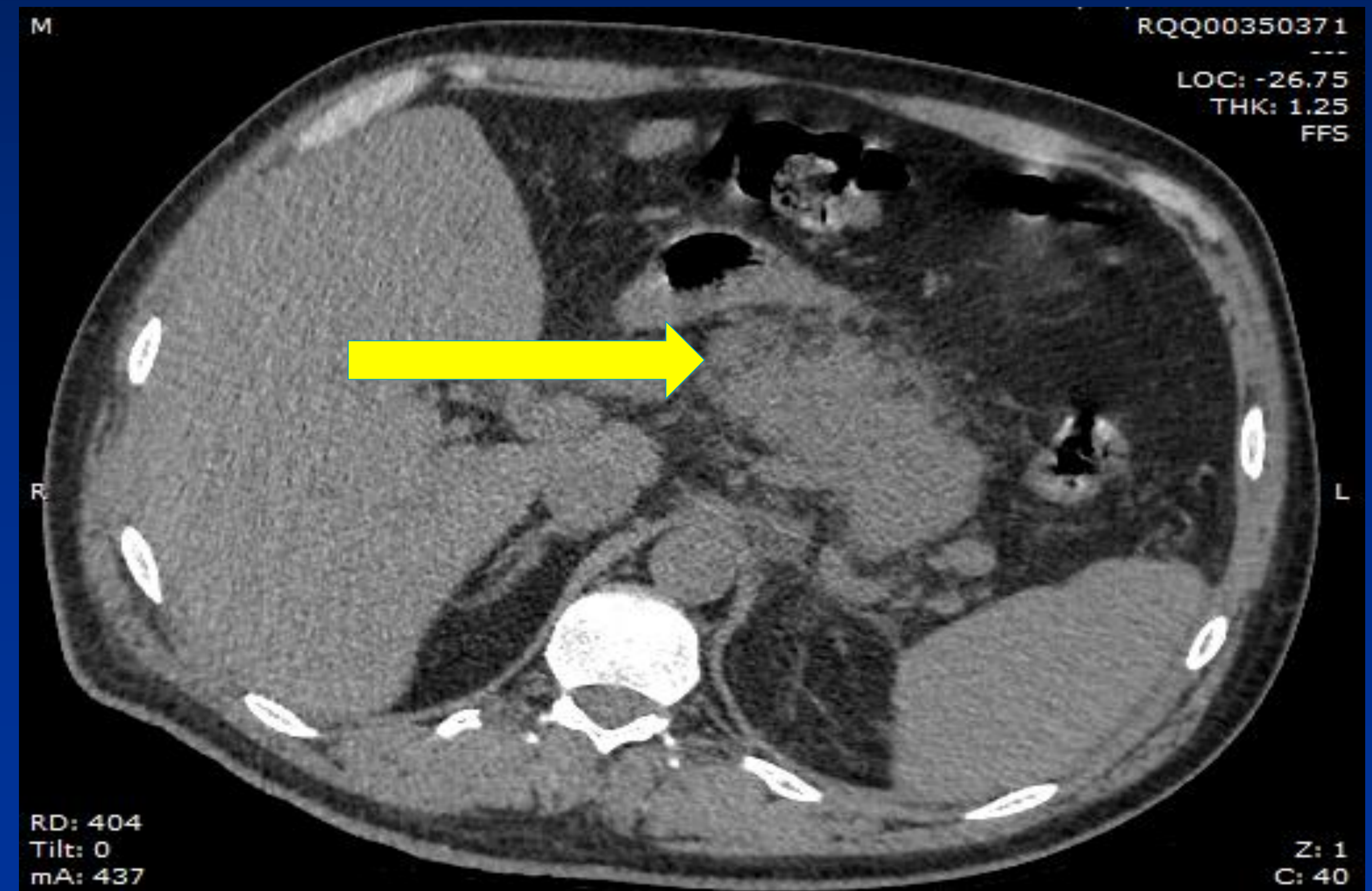
Subsequent tests showed severe hypercalcemia and elevated parathormone levels suggesting primary hyperparathyroidism . He was referred to Endocrine team..

An ultrasound of his parathyroid failed to localize any adenoma while the Spect CT scan showed activity in the right para sternocleidomastoid region consistent with an ectopic parathyroid tissue.

He had two further admissions with acute pancreatitis secondary to hypercalcemia. Co-existing severe Vitamin D deficiency was discovered which required correction to optimize his chances of a successful outcome post-surgery.

The patient was referred for urgent surgery for removal of his ectopic parathyroid. Following removal of the adenoma the calcium and paratharmone levels normalised completely.

This case was challenging because of its rarity and complexity of the management of recurrent pancreatitis and primary hyperparathyroidism due to ectopic parathyroid tissue.



EPIDEMIOLOGY

Primary Hyperparathyroidism is a relatively common disorder affecting 1 in 500 women and 1 in 2000 men over 40 years of age. Estimated incidence of ectopic parathyroid is 35%; due to aberrant migration during early stages of development.

DISCUSSION

In a study evaluating 30 patients with multiglandular disease, SPECT-CT predicted the location of all abnormal glands in 46 percent of cases compared with 37 and 13 percent for CT alone and SPECT alone, respectively. Vitamin D deficiency correction attempts frequently led to severe hypercalcemia which in itself posed additional risk of recurrent pancreatitis. The resultant hypercalcemia only partially responded to bisphosphonate and salmon calcitonin and was further compounded by poor patient compliance due to intolerance to either of these agents. Our patient had severe concomitant vitamin D deficiency with primary hyperparathyroidism, which was another therapeutic challenge as there are no clear guidelines for vitamin D replacement in symptomatic primary hyperparathyroidism patients and there is the added danger of worsening hypercalcemia and hypercalciuria.

CONCLUSION

Primary Hyperparathyroidism may rarely provoke acute pancreatitis but for recurrent pancreatitis to occur is indeed very unusual save for hereditary primary hyperparathyroidism. Our patient in question had an ectopic parathyroid which was revealed by adopting a more intensive investigation approach following initial negative ultrasound. Correcting severe Vitamin D deficiency with careful management of severe hypercalcemia presents its own treatment challenges especially with stone formation in the urinary tract but recurrent pancreatitis triggered by hypercalcemia presents a management nightmare which involves close monitoring of numbers as a prelude to ensuring an optimal outcome following surgery.

Further Reading

1. Acute Pancreatitis in Primary Hyperparathyroidism: a population based study AU Khoo et al: J.Clinical Endocrinology and Metabolism ;2009 Jun 94(6) 2115-2118: E Pub 2009 Mar 24
2. Comparison of spect CT/CT and planar imaging with single and dual phase 99m TechnetiumC sestamibi parathyroid scintigraphy : Lavelly WC et al ; SOJ Nuclear medicine .2007 ;48(7) :1084
3. Incidence and localisation of ectopic parathyroid adenomas in previously unexplored patients. Roy MI et al: World Journal of Surgery;2013 : Jan 37(1):102-6 : doi :10.1007/s00268-012-1773-z
4. Safety of Vitamin D replacement in patients with primary hyperparathyroidism and concomitant Vitamin D deficiency. Wagner DI et al:Endocrine,Practice 2003: May-June19(3):420-5.doi: 10.4158/EP12155.OR.

Hinchingsbrooke Health Care NHS Trust

