

# Cushings syndrome due to carneys complex – Case series and report of a new mutation from a South Indian tertiary care centre

Dr.Kavya.J , Dr.Praveen.V.P , Dr.Nisha Bhavani , Dr.Jayakumar.R.V  
 Dr.Vasantha Nair , Dr.Harish Kumar , Dr.Arun S Menon , Dr.Usha Menon  
**Amrita Institute of Medical Sciences , Kochi , India**

Acknowledgement **Dr.Constantine stratakis** and **Dr.Charalampos lyssikatos** of NIH for facilitating genetic testing

## Introduction

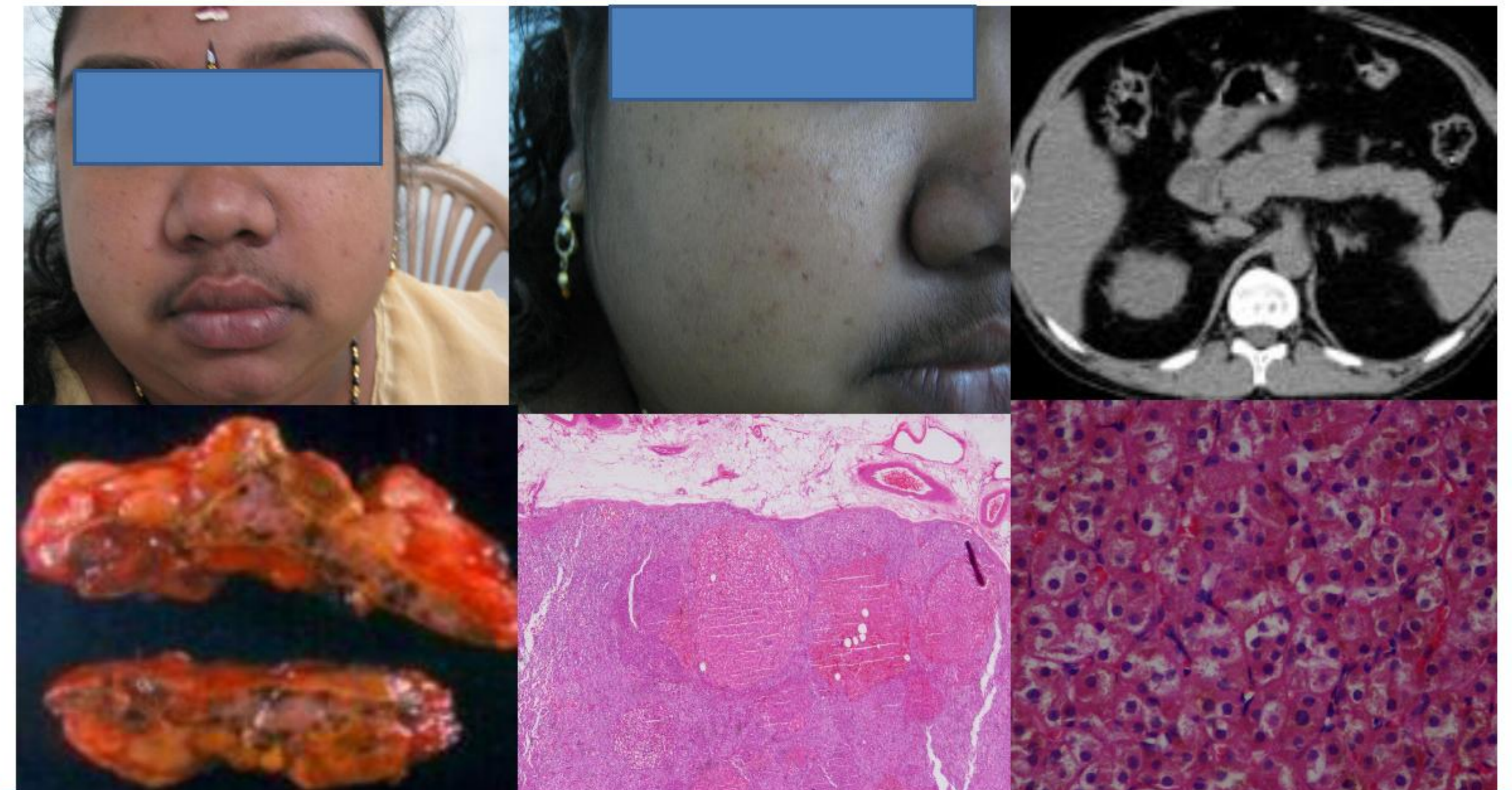
Carneys complex is an Autosomal Dominant condition characterised by spotty skin pigmentation , myxomas , endocrine and non endocrine tumors. Cushings syndrome due to PPNAD occurs in 25-45% of patients with carneys complex

## Clinical presentation

3 patients in our series were diagnosed between second and third decade. All the 3 patients had diabetes , hypertension , cushingoid features. Diagnosis was clinically suspected by the presence of lentigenes on the face.

## Method

We report case series of 3 patients diagnosed with cushings syndrome associated with carneys complex .Their clinical , biochemical , radiological and genetic details are described below.



Sl.no	Sex	Age of onset (Years)	Age at diagnosis (Years)	Sr.k (meq/l)	Basal cortisol (ug/dl)	ONDST (ug/dl)	LDDST (ug/dl)	ACTH pg/ml	Imaging CT Abdomen and MRI Brain	HPR	Genetic testing
1.	M	21	25	3.7	25.8	26	45	<1	Nodular Left Adrenal Gland	PPNAD	Positive (C769G>A;E257K) <b>New variant</b>
2.	F	13	18	4.4	10	14.4	17.5	<1	Both Adrenals Normal Pituitary micro adenoma on MRI	PPNAD	Negative
3.	M	20	23	4	16	20.6	21.4	<1	Nodular Right Adrenal gland	Bilateral adreno cortical hyperplasia	Positive intronic IVS1-2 A>G splice site mutation

**Conclusion :** Multiple lentigenes , a classical hike in serum cortisol after dexamethasone administration, suppressed ACTH and radiological evidence of nodular adrenals can help us suspect carneys complex in a patient presenting with cushings syndrome . Genetic testing could be negative in 30-40% of patients.

**Follow up :** None of them had cardiac myxomas on screening.USG Neck and Scrotum were normal on screening. All the 3 patients underwent bilateral adrenalectomy. Patients 1 and 3 were under follow up and patient 1 on follow up had High grade olfactory Neuroblastoma (Esthesioneuroblastoma)