

Retrospective Evaluation of Adrenal Incidentalomas in our Clinic

Ahmet Kaya¹, Mustafa Kulaksızoğlu¹, Melek Çağlayan², Feridun Karakurt¹

¹Necmettin Erbakan University, Meram Medical Faculty, Division of Endocrinology and Metabolism, Professor, Turkey

²Necmettin Erbakan University, Meram Medical Faculty, Department of Internal Medicine, MD, Turkey

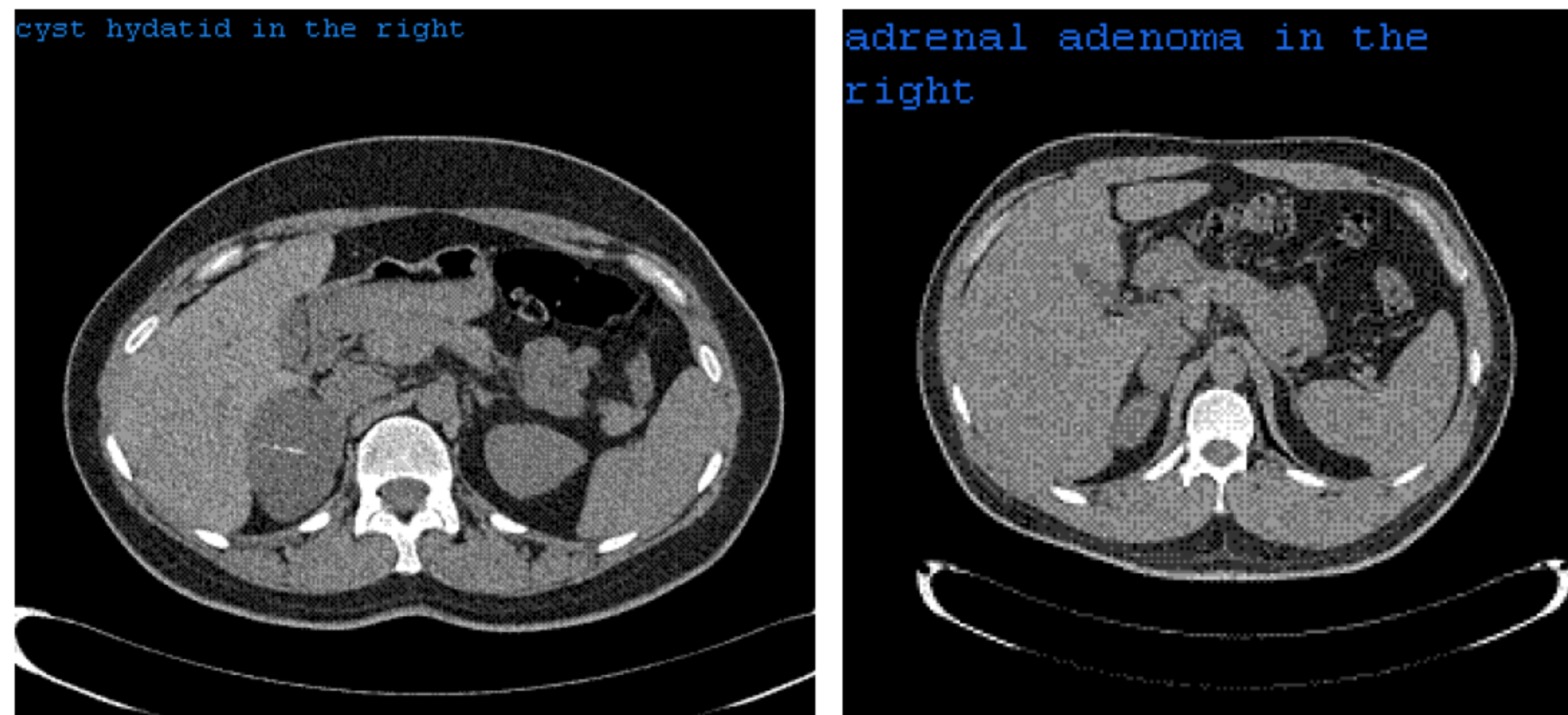
INTRODUCTION

Adrenal incidentalomas are new era of the endocrinology.

An adrenal incidentaloma is discovered serendipitously by radiologic examination. These lesions incidence increases with age and overall prevalence ranges between 3% and 10%. The widespread use of imaging techniques such as computed tomography (CT) and magnetic resonance imaging (MRI), increase the frequency of detection of these lesions.

Malignancy is an uncommon cause of adrenal incidentaloma in patients without a known diagnosis of cancer. Although estimates have varied widely, the actual frequency of primary adrenal carcinoma in patients with adrenal incidentaloma is approximately 2 to 5 percent; another 0.7 to 2.5 percent have nonadrenal metastases to the adrenal gland.(1,2,3,4)

We aimed to see the results of adrenal masses retrospectively.



METHODS

Patients admitted to the Internal Medicine outpatient clinic for different complaints were retrospectively evaluated. Patients whom abdominal imaging like ultrasonography, magnetic resonance imaging or computed tomography were done and incidentally established adrenal masses were evaluated. Patients with a history of hypertension, findings of hypokalemia, hyponatremia were excluded from the study. Patients were hospitalised and adrenal function tests were done.

RESULTS

There were totally 59 patients, 24 male (40.67%), 35 female (59.32%), and mean ages were 57.54 + 11.29 years (32-75 years) in men and 55.71 + 11.72 years (31-81) in women. Adrenal function tests revealed that 53 (89.83%) incidentalomas were nonfunctioning. Totally 6 (10.16%) patients' adenomas were functioning, 3 (5.08%) of them were pheochromocytomas, 1 was subclinical Cushing syndrome and 2 (3.38%) were primary hyperaldosteronisms. 3 (5.08%) of nonfunctioning adenomas were diagnosed as metastasis in computerized tomography, 1 was small cell carcinoma, and 1 was prostate malignancy. The other patient was operated and diagnosed as adrenal adenocarcinoma. In the nonfunctioning group, 2 patients had cyst hydatid disease and were having treatment for it and also 2 patients had accessory spleen in the tomography.

CONCLUSIONS

In this study, we reported characteristics of adrenal incidentalomas. All patients with adrenal incidentalomas should be evaluated for the possibility of malignancy and subclinical hormonal hyperfunction (primary aldosteronism, pheochromocytoma, Cushing's syndrome) for better management of adrenal incidentalomas.

Adrenal cysts are rare lesions and usually easily characterized because of their distinctive imaging characteristics. In this study, we also reported 2 patients had cyst hydatid in the right adrenal gland who diagnosed cyst hydatid in liver and they previously underwent invasive treatment as PAIR.

References

References

1. Young WF Jr. Clinical practice. The incidentally discovered adrenal mass. *N Engl J Med* 2007; 356:601.
2. Terzolo M, Stigliano A, Chiodini I, et al. AME position statement on adrenal incidentaloma. *Eur J Endocrinol* 2011; 164:851.
3. Young WF Jr. Management approaches to adrenal incidentalomas. A view from Rochester, Minnesota. *Endocrinol Metab Clin North Am* 2000; 29:159.
4. Cawood TJ, Hunt PJ, O'Shea D, et al. Recommended evaluation of adrenal incidentalomas is costly, has high false-positive rates and confers a risk of fatal cancer that is similar to the risk of the adrenal lesion becoming malignant: time for a rethink? *Eur J Endocrinol* 2009; 161:513.

