

Pneumocystis pneumonia in Cushing's syndrome due to ectopic ACTH.

Dimitris Papamargaritis¹, Syed Jafery¹, Ragini Bhake¹, Narendra Reddy¹, Miles Levy¹

¹Department of Endocrinology, University Hospitals of Leicester NHS trust, Leicester, UK



Introduction

- Opportunistic infections are a recognised complication of severe hypercortisolism.
- We report a case of Pneumocystis Jiroveci Pneumonia (PCP for formerly named Pneumocystis carinii pneumonia) in patient with ectopic Cushing's syndrome caused by a metastatic large cell neuroendocrine carcinoma of the lung.

Case report

- A 61-year old male attended the Acute Medical Unit for investigation and treatment of severe and recurrent hypokalaemia (K<2.5 mmol/l). Other cushingoid features included hypertension, easy bruising and central fat distribution.
- His random cortisol at presentation was 1404 nmol/L, 24-h urine free cortisol of 6363 nmol/24h (upper limit of normal 270) and plasma ACTH was 250 ng/L(normal <50) confirming a diagnosis of ACTH dependent Cushing's syndrome. A repeat 9 am cortisol was >2000 nmol/l
- Corticotrophin-Releasing Hormone (CRH) test (Table 1) was suggestive of ectopic ACTH secretion (ACTH increment <50%).
- CT whole body demonstrated a left upper lobe lung nodule with multiple liver metastases.
- Liver biopsy and immune-histochemistry confirmed the diagnosis of a large cell neuroendocrine carcinoma, metastatic from the lung.

Management and complications

- Patient treated initially with Spironolactone 50mg od . Metyrapone 250mg tds started after confirmation of diagnosis of ectopic ACTH Cushing's disease for management of severe hypokalaemia and hypercortisolaemia. Metyrapone dose gradually increased to 750mg tds and ketoconazole was added to the treatment. There was improvement in serum cortisol (655nmol/l) and potassium (3.5 mmol/l) levels.
- Decision from oncology MDT was for palliative chemotherapy.
- One week after initiation of treatment with metyrapone, patient developed cough, fever, shortness of breath and he was desaturating on air (SaO2:88% on Air).
- He was treated with intravenous antibiotics for hospital acquired pneumonia and oxygen. A CXR (Figure 1) and a CTPA (Figure 2) showed bilateral upper lobe dense consolidation. Patient started on empirical treatment for PCP with co- trimoxazole (oral) and a broncho-alveolar lavage (BAL) confirmed the diagnosis.
- Treatment for PCP continued for 21 days, patient's condition improved and discharged from the hospital with oxygen. Decision from oncology team after discussion with patient was not to provide chemotherapy due to overall deterioration. Patient referred to McMillan palliative team for symptom control .

Table 1. CRH test results

Time (min)	Cortisol (nmol/l)	ACTH (ng/L)
-15	>2000	197
0	>2000	166
15	>2000	194
30	>2000	189
45	>2000	221
60	>2000	228
90	>2000	194
120	>2000	216

Table 2. Gut hormone measurement

	Value	Normal Range
Pancreatic Polypeptide	>500 pmol/l	(0-300)
VIP	3 pmol/l	(0-30)
Glucagon	80 pmol/l	(0-50)
Gastrin	45 pmol/l	(0-40)
Somatostatin	821 pmol/l	(0-150)
Chromogrophin A	91 pmol/l	(0-60)
Chromogrophin B	2391 pmol/l	(0-150)

Figure 1. CXR

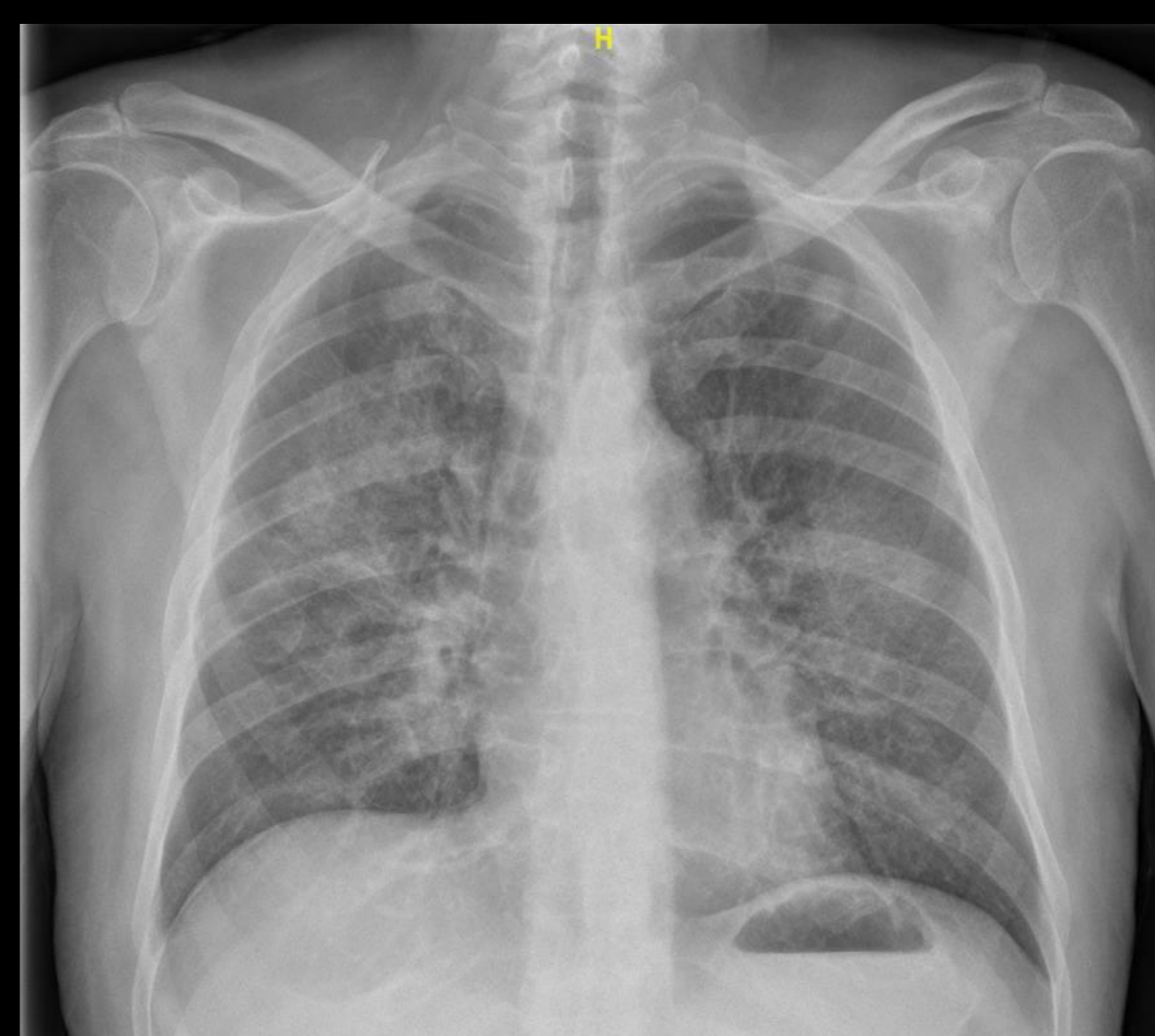
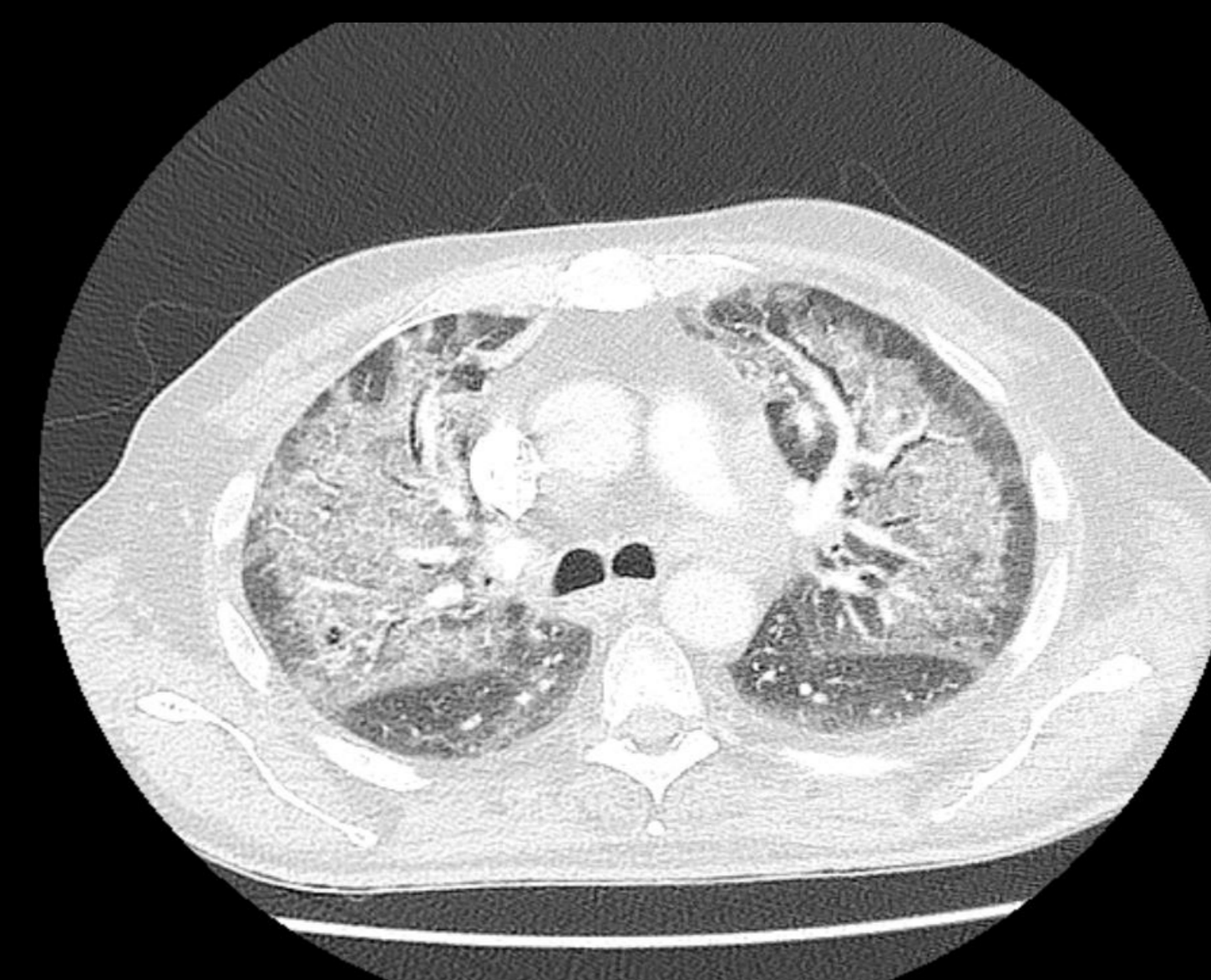


Figure 2. CTPA



Discussion

- Similar to our case, PCP has been diagnosed after initiation of cortisol-lowering therapy in the majority of the reported cases in patients with Cushing's syndrome¹.
- This suggests that immune reconstitution is an important component or even a prerequisite for development of clinically overt PCP in this population. There seems to be a relationship between the degree of hypercortisolism and the susceptibility to opportunistic infections².
- Our case highlights the fact that patients with severe hypercortisolaemia, more commonly seen in ectopic ACTH syndrome, may be at particular risk of PCP infection following treatment with cortisol-lowering agents.
- Prophylaxis against PCP should be considered before starting cortisol-lowering therapy in order to minimise the risk of PCP^{1,3}.

References

- 1) van Halem K, Vrolijk L, Pereira AM, de Boer MGJ. Characteristics and Mortality of Pneumocystis Pneumonia in Patients With Cushing's Syndrome: A Plea for Timely Initiation of Chemoprophylaxis. Open Forum Infect Dis. 2017 Jan 30;4(1).
2. Sarlis NJ, Chanock SJ, Nieman LK. Cortisolemic indices predict severe infections in Cushing syndrome due to ectopic production of adrenocorticotropin. J Clin Endocrinol Metab 2000; 85: 42-47.
3. Kim DS, Park SK, Choi WH, et al. Pneumocystis carinii pneumonia associated with a rapid reduction of cortisol level in a patient with ectopic ACTH syndrome treated by octreotide and ketoconazole. Exp Clin Endocrinol Diabetes 2000; 108: 146-50.