

Seok Ho Seo, M.D., Tae Hyun Kim, M.D.*, Soon Ho Kim, M.D.,
Seung Hyun Lee, M.D., Jong Taek Kim, M.D., Dae Won Park,
M.D., Dong Chul Lee, M.D.

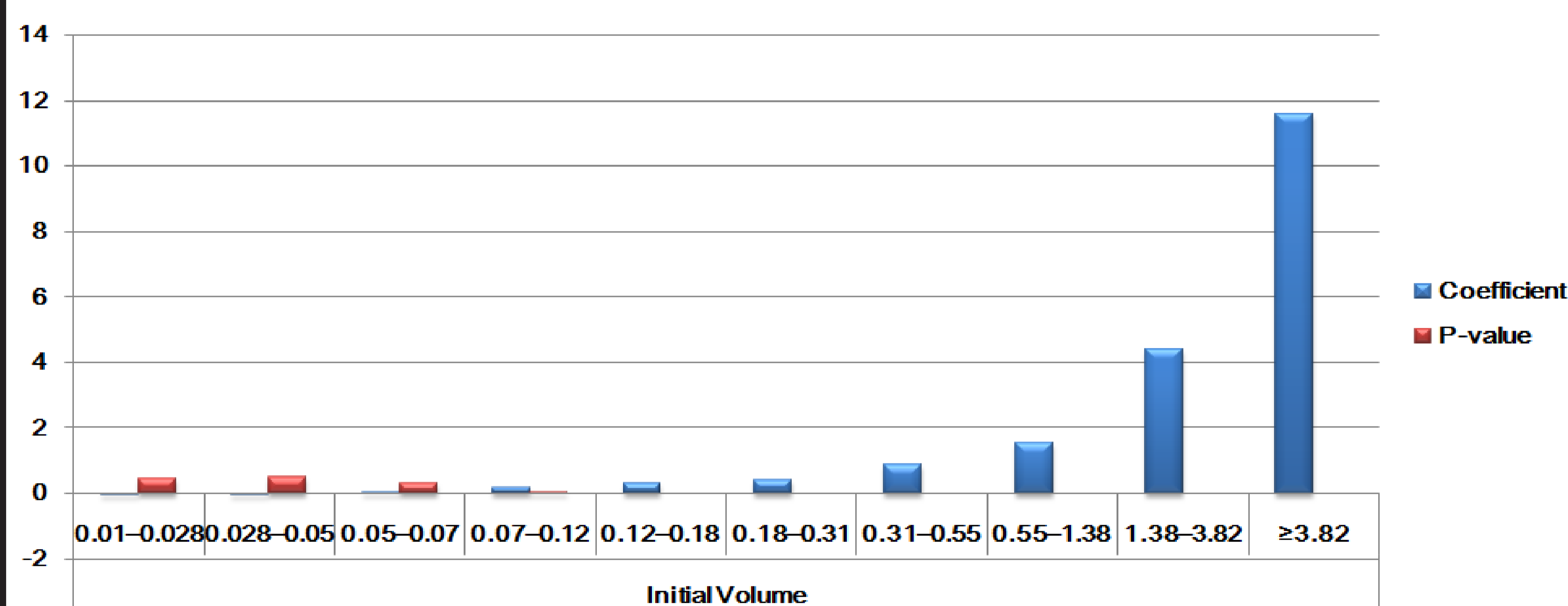
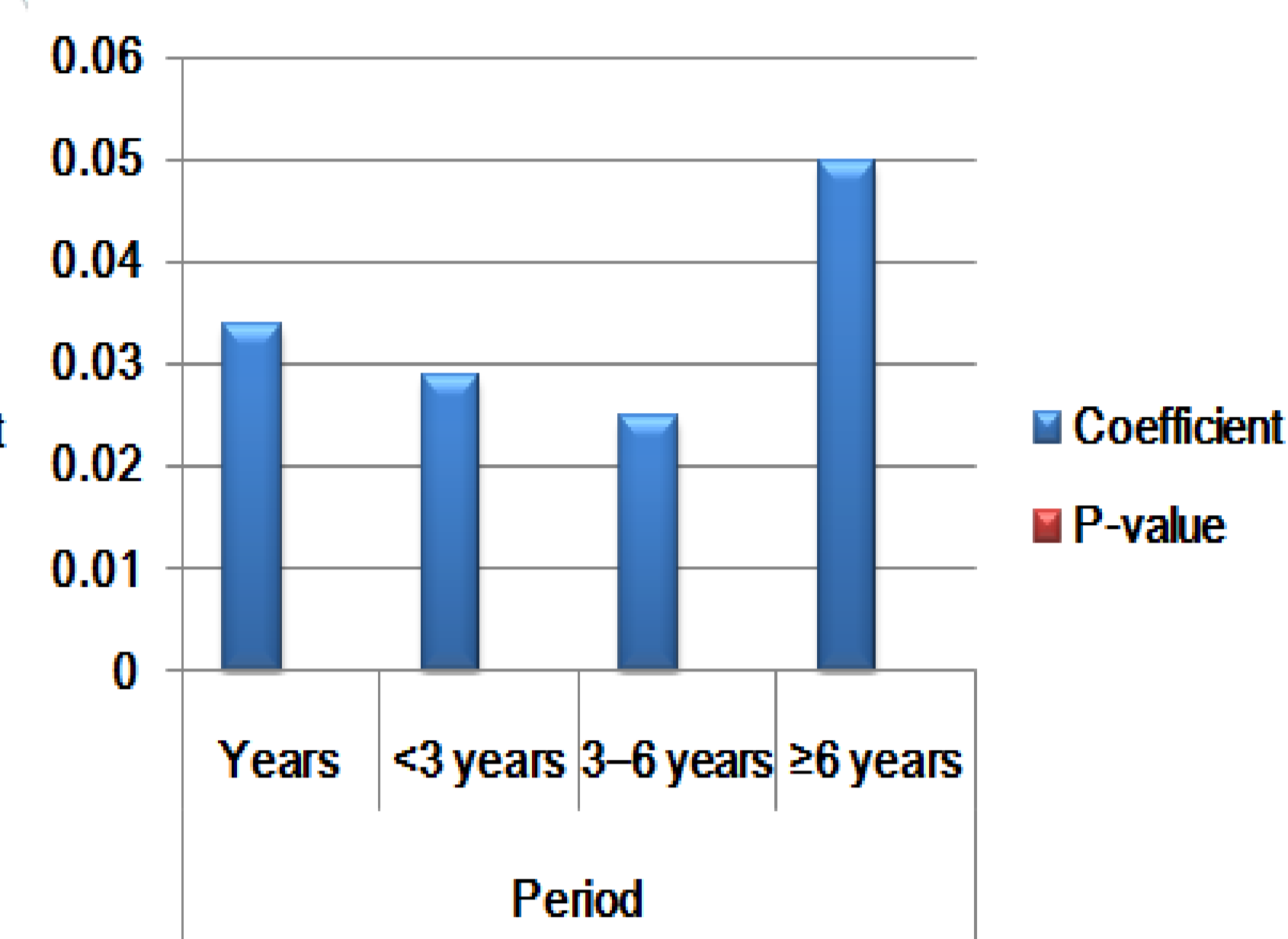
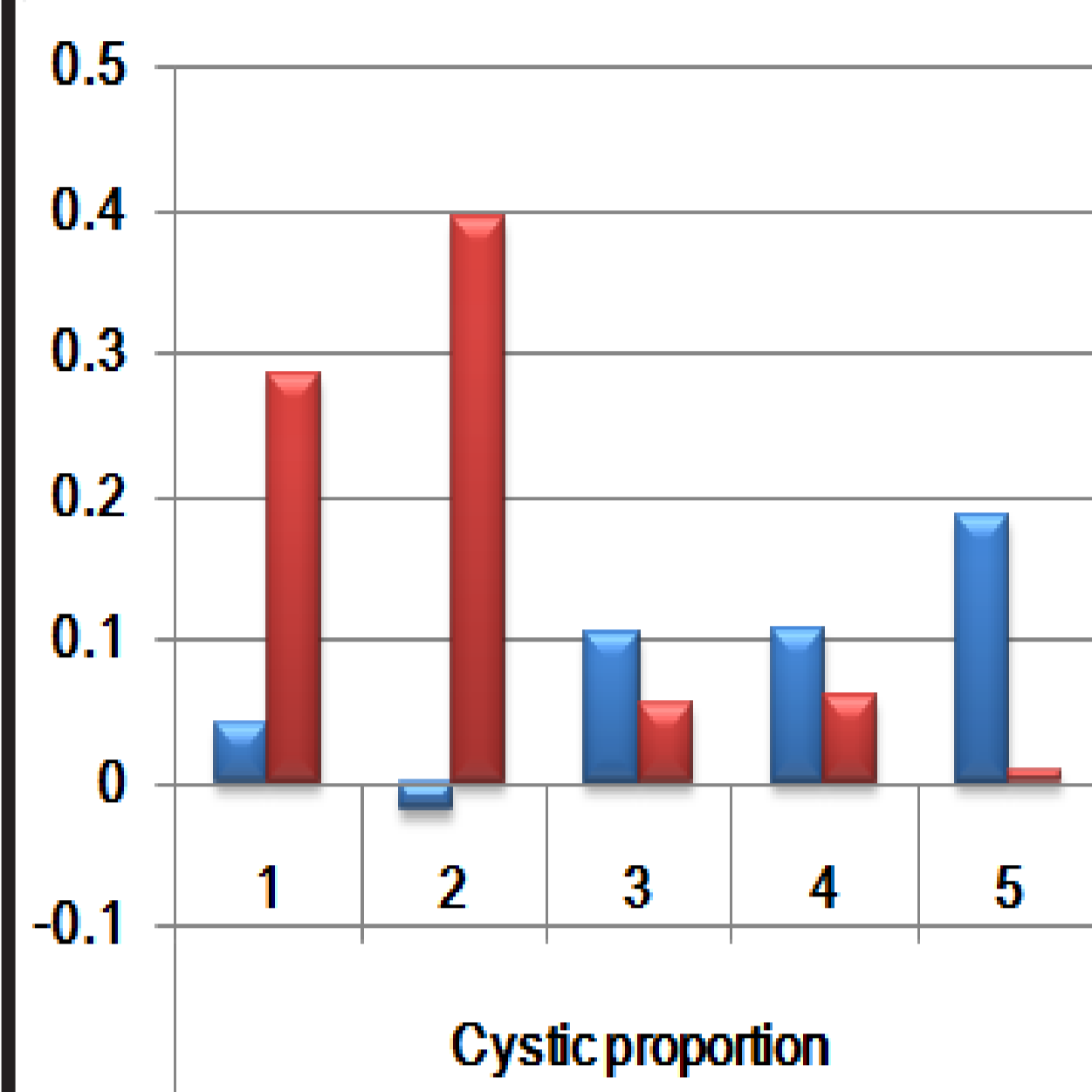
Department of Internal Medicine, Kwangju Christian Hospital,
Kwangju, Korea

Objective

- Most thyroid nodules are benign therefore, they are commonly only monitored.
- Only a few studies are available on the natural progression/regression of benign thyroid nodules, and large-scale studies on the subject are non-existent.
- So we identify factors that affect the size of benign thyroid nodules and to predict the potential nodule size through a model.

Methods

- Between January 2001 and December 2011, 2,469 benign thyroid nodules (1,564 patients) were diagnosed through fine needle aspiration.
- After excluding 505 nodules for which either the volume was unknown or percutaneous ethanol injection or radiofrequency ablation had been performed,
- 1,964 benign thyroid nodules (1,261 patients) were selected for the retrospective analysis in our study.



Results

- The nodules with increased size overtime involved a longer follow-up period than the nodules with decreased size.
- The proportions of females and cystic portion were relatively high.
- For the thyroid nodules with increased size, we analyzed the potential influencing factors.
- Our analysis results indicate that larger nodule volume, extended follow-up period, and high cystic proportion were all positively associated with increased nodule size.

Conclusions

- Controlling for all other potential variables, the thyroid nodules tended to grow at a rate of approximately 0.034 cm³per year in the group with continually growing nodules.
- The model used in our study may offer helpful insight in determining an optimal treatment schedule for benign thyroid nodules

References

- 1) Tan, G.H. & Gharib, H. (1997) Thyroid incidentalomas: management approaches to nonpalpable nodules discovered incidentally on thyroid imaging. *Annals of Internal Medicine*, **126**, 226-231.
- 2) Alexander, E.K., Hurwitz, S., Heering, J.P., et al. (2003) Natural history of benign solid and cystic thyroid nodules. *Annals of Internal Medicine*, **138**, 315-318.
- 3) Hegedüs, L. (2004) The thyroid nodule. *New England Journal of Medicine*, **351**, 1764-1771.
- 4) Baek, J.H., Lee, J.H., Valcavi, R., et al. (2011) Thermal ablation for benign thyroid nodule: radiofrequency and laser. *Korean Journal of Radiology*, **12**, 525-540.
- 5) Kihara, M., Hirokawa, M., Masuoka, H., et al. (2013) Evaluation of cytologically benign solitary thyroid nodules by ultrasonography: a retrospective analysis of 1877 cases. *Auris Nasus Larynx*, **40**, 308-311.
- 6) Ha, E.J. & Baek, J.H. (2014) Advances in nonsurgical treatment of benign thyroid nodules. *Future Oncology*, **10**, 1399-1405.
- 7) Papini, E., Rago, T., Gambelunghe, G., et al. (2014) Long-term efficacy of ultrasound-guided laser ablation for benign solid thyroid nodules. Results of a three-year multicenter prospective randomized trial. *Journal of Clinical Endocrinology and Metabolism*, **99**, 3653-3659.
- 8) Lim, D.J., Kim, J.Y., Baek, K.H., et al. (2013) Natural course of cytologically benign thyroid nodules: observation of ultrasonographic changes. *Endocrinology and Metabolism*, **28**, 110-118.
- 9) Quadbeck, B., Pruellage, J., Roggenbuck, U., et al. (2002) Long-term follow-up of thyroid nodule growth. *Experimental and Clinical Endocrinology & Diabetes*, **110**, 348-354.
- 10) Kim, S.Y., Han, K.H., Moon, H.J., et al. (2014) Thyroid nodules with benign findings at cytologic examination: results of long-term follow-up with US. *Radiology*, **271**, 272-281.
- 11) Erdogan, M.F., Gursoy, A., Erdogan, G. (2006) Natural course of benign thyroid nodules in a moderately iodine-deficient area. *Clinical Endocrinology (Oxf)*, **65**, 767-771.
- 12) Na, D.G., Lee, J.H., Jung, S.L., et al. (2012) Radiofrequency ablation of benign thyroid nodules and recurrent thyroid cancers: consensus statement and recommendations. *Korean Journal of Radiology*, **13**, 117-125.

