

Didem Ozdemir¹ Şefika Burçak Polat¹, Betül Asan², Aydan Kilicarslan³, Sabire Y. Aksoy⁴, Seyda Turkolmez⁴, Reyhan Ersoy¹, Bekir Cakir¹

¹Ankara Yildirim Beyazıt University, School of Medicine, Ataturk Education and Research Hospital, Department of Endocrinology and Metabolism, Ankara, Türkiye

²Ankara Yildirim Beyazıt University, School of Medicine, Ataturk Education and Research Hospital, Department of Internal Medicine, Ankara, Türkiye

³Ankara Yildirim Beyazıt University, School of Medicine, Ataturk Education and Research Hospital, Department of Pathology, Ankara, Türkiye

⁴Ankara Yildirim Beyazıt University, School of Medicine, Ataturk Education and Research Hospital, Department of Nuclear Medicine, Ankara, Türkiye

Introduction:

We report a patient presenting with adrenal failure and an intraabdominal mass indicative for paraganglioma with imaging techniques. Final diagnosis was stage IV B cell lymphoma.

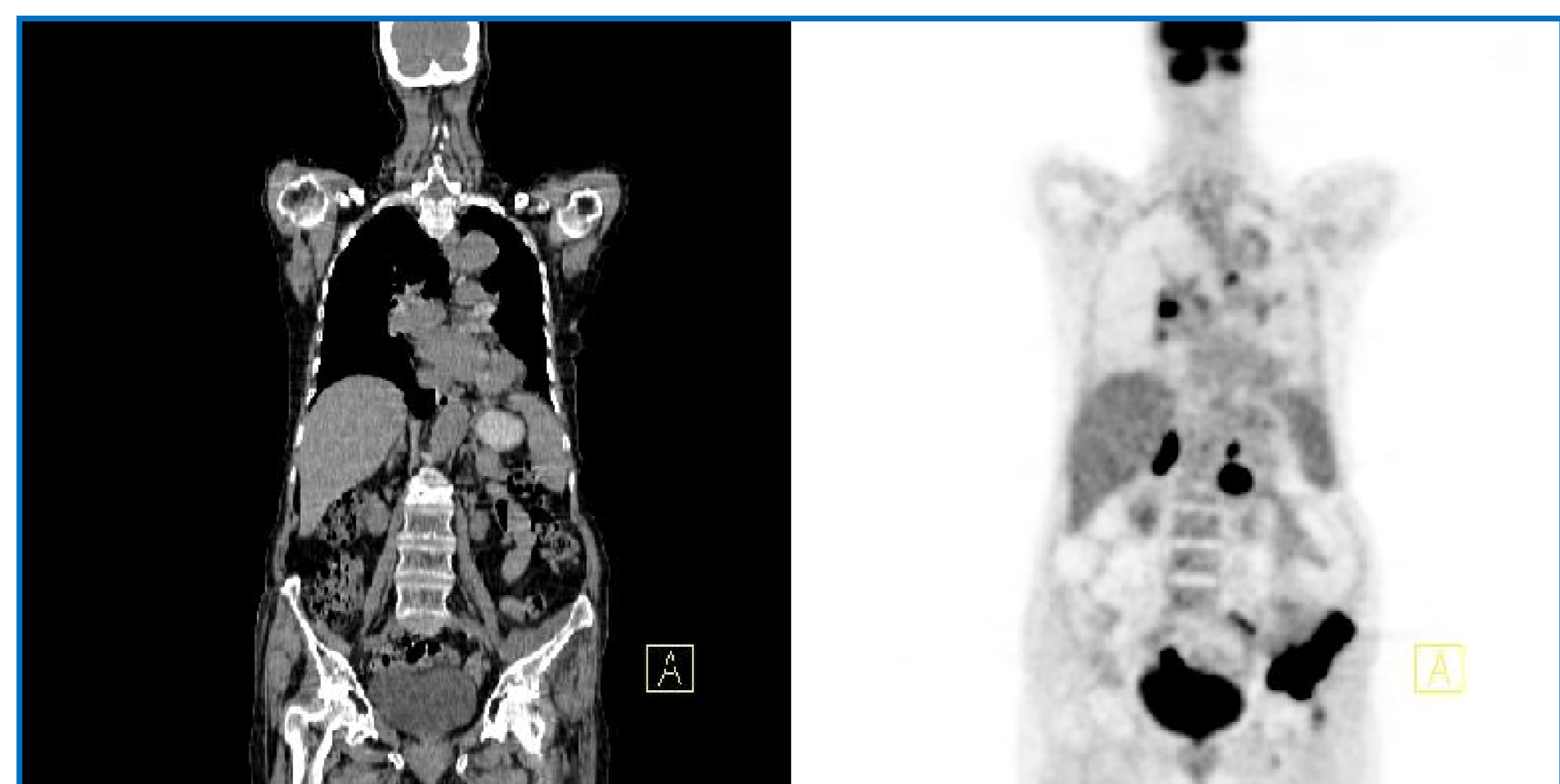
Case report:

A 71 years old woman admitted to our emergency clinic with severe fatigue and stupor. She was diagnosed to have primary adrenal failure because her serum ACTH was 229 pg/mL and maximum cortisol response to 250 mcg co-syntropin was 6.17 mcg/dL. Methylprednisolone and fludrocortisone treatment was started. In abdominal magnetic resonance imaging (MRI), bilateral adrenal enlargement and a 35x31 mm paraaortic lesion medial to the left adrenal gland consistent with a paraganglioma (heterogenous, markedly increased contrast uptake, milimetric cystic foci) was detected. ¹²³I-Metaiodobenzylguanidine (MIBG) scintigraphy showed diffuse uptake in this solid nodular lesion (Figure 1). 24 hour urine catecholamine examination revealed a moderately increased metanephrin, normetanephrin and VMA levels. She had stopped her antihypertensive medications for about 2 months and she did not experience persistent or intermittent hypertension from then on. During investigation for the cause of adrenal failure, multiple mediastinal and hilar lymph nodes with a diameter of 24x7 mm and a lesion of 94 mm destructing cortex of left iliac crest in the lateral part, extending to soft tissue were detected in thoracal and pelvic MRI, respectively. 18FDG-PET was performed and confirmed high uptakes with high SUVmax indexes in the lesion inferior to left adrenal gland, bilateral adrenal glands, paravertebral and mesenteric lymph nodes, intestinal serosal surfaces and left iliac crest. (Figure 2). A computer tomography-guided biopsy was taken from the lesion surrounding iliac crest and the histopathological result was high grade B cell lymphoma infiltration.

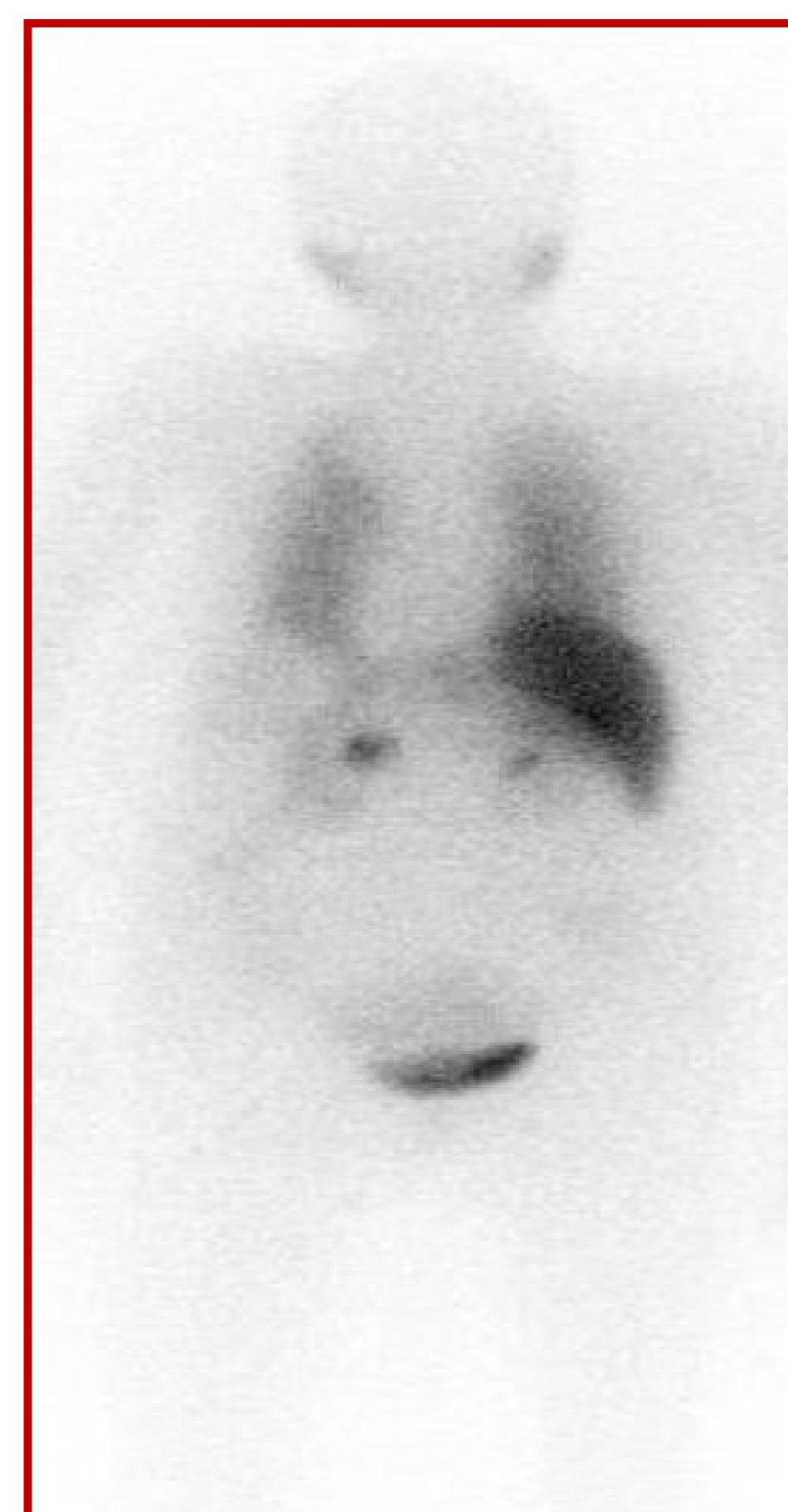

Figure 1: MIBG scan showing diffuse uptake in the lesion near to the left adrenal gland (posterior view)

Figure 2: 18F-FDG-PET showing multiple uptakes prominent in the lesion near to the left adrenal gland, bilateral adrenal glands and left iliac region



Conclusion:

To our knowledge, coexistent paraganglioma and lymphoma was not reported in the literature previously. However, false positive MIBG uptake secondary to lymphoma could not be excluded. Although ¹²³I-MIBG is known to have a sensitivity of 77-90% and specificity of 88-99% for localizing paragangliomas, there are rare reports of false positivity in focal nodular hyperplasia of liver, adrenocortical adenoma and carcinoma, urinoma and angiomyolipoma. High grade lymphoma with high vascularity might be another rare cause of false positive MIBG.

