




# Pseudothrombocytopenia Improved With Antithyroid Treatment in Graves Disease: A Case Report

MEHMET MUHITTIN YALCIN<sup>1</sup>, FUSUN BALOS TORUNER<sup>1</sup>, EMRE ARSLAN<sup>1</sup>, ALEV EROGLU ALTINOVA<sup>1</sup>, ZUBEYDE SAYGILI<sup>2</sup>, SENA AKSOY<sup>2</sup>, MUJDE AKTURK<sup>1</sup>, ZEYNEP ARZU YEGIN<sup>3</sup>, NURI CAKIR<sup>1</sup>

<sup>1</sup>GAZI UNIVERSITY FACULTY OF MEDICINE DEPARTMENT OF ENDOCRINOLOGY AND METABOLISM, ANKARA, TURKEY

<sup>2</sup>GAZI UNIVERSITY FACULTY OF MEDICINE DEPARTMENT OF INTERNAL MEDICINE, ANKARA, TURKEY

<sup>3</sup>GAZI UNIVERSITY FACULTY OF MEDICINE DEPARTMENT OF HEMATOLOGY, ANKARA, TURKEY

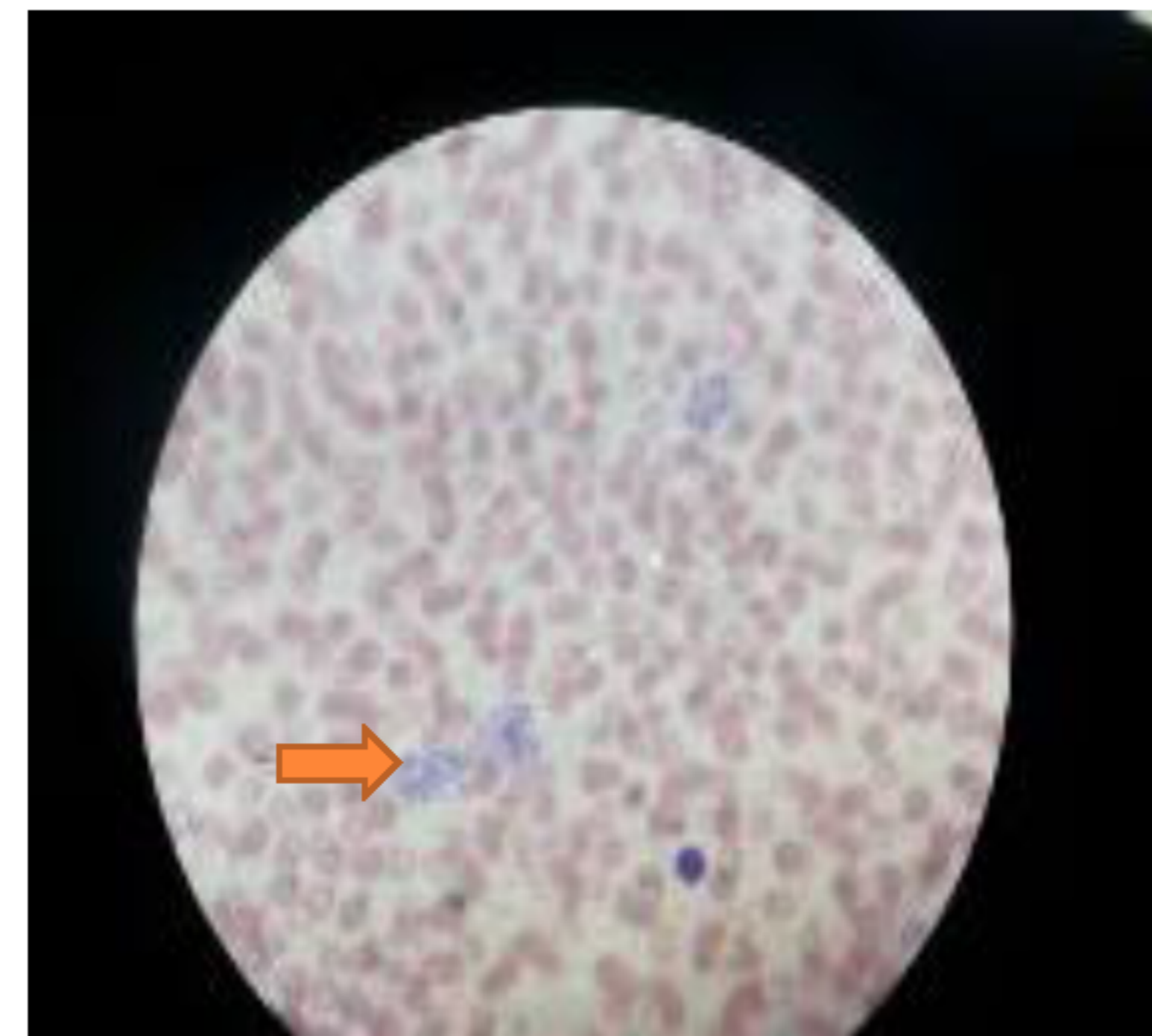


## Introduction

Graves Disease (GD) is an autoimmune disease of thyroid gland. Hematological abnormalities can occur in the course of the disease. Although some reports describe low platelet counts in almost half of patients with GD, clinically important thrombocytopenia can be seen rarely in GD.

In this report we present a case of pseudothrombocytopenia in GD.

Figure 1: Aggregated Platelets



## Case Presentation

A 21 year old female was admitted to our clinic with hair loss, anxiety, nervousness and tremor in hands. Her TSH level was low, while free T3 and free T4 levels were elevated ( TSH:<0.05 IU/mL (0.27-4.2), fT4:2.46 ng/dL (0.93-1.7) , fT3:7.33 pg/mL (1.71-3.71) ). There were no nodules in her thyroid ultrasonography. An increased radioiodine uptake was found in thyroid gland. Her thyroid receptor antibody (TRAB) was positive (14.4 U/L). GD was diagnosed. Complete blood count and liver function tests were performed before antithyroid treatment. All the tests were normal except low platelet count (8700/ $\mu$ L). She had no history of bleeding. Platelet test was reordered using a citrate-containing tube and platelets were found low again (24100/ $\mu$ L). Aggregated platelets were seen in peripheral smear showing that decreased platelet level was due to pseudothrombocytopenia (Figure 1). There was no history of herbal drugs, medicine or any other cause of pseudothrombocytopenia. Methimazole treatment was given. One month after therapy, thyroid function tests were found to be normal, and TRAB turned to be negative. Interestingly, platelet count were turned to be normal in blood tests using both EDTA-containing and citrate-containing tubes. Repeated peripheral smear did not contain any aggregation of platelets.

## Discussion

Pseudothrombocytopenia was described in only a few case reports in the active phase of some autoimmune diseases like systemic lupus erythematosus. Platelet count may increase after therapy for the disease. It has been reported that anti-platelet antibodies may be responsible for this issue.

Isolated thrombocytopenias may be seen in GD, but immune thrombocytopenia is mostly responsible for thrombocytopenia in GD. To the best of our knowledge, this is the first report of pseudothrombocytopenia in GD.

## References

- Kurata Y, Nishioeda Y, Tsubakio T. Thrombocytopenia in Graves' disease: effect of T3 on platelet kinetics. *Acta Haematol* 1980; 63: 185-190
- Cordnio I, Betterle C, Spadaccino CA, et al. Autoimmune thrombocytopenia(AITP)and thyroid autoimmune disease (TAD) : overlapping syndromes? *Clin Exp Immunol* 1998; 113:373-378
- Panzer s, Haubenstock A, Minar E. Platelets in hyperthyroidism: studies on platelet count, mean platelet volume, indium-labeled platelet kinetics andplatelet associated immunoglobulins G and M. *J Clin Endocrinol Metab* 1990; 70:491-496

