



Elizabeth Bayman, Kathleen Duffin, Harriet Miles, Julie Freeman, Muhammad Walayat
Royal Hospital for Sick Children, Edinburgh

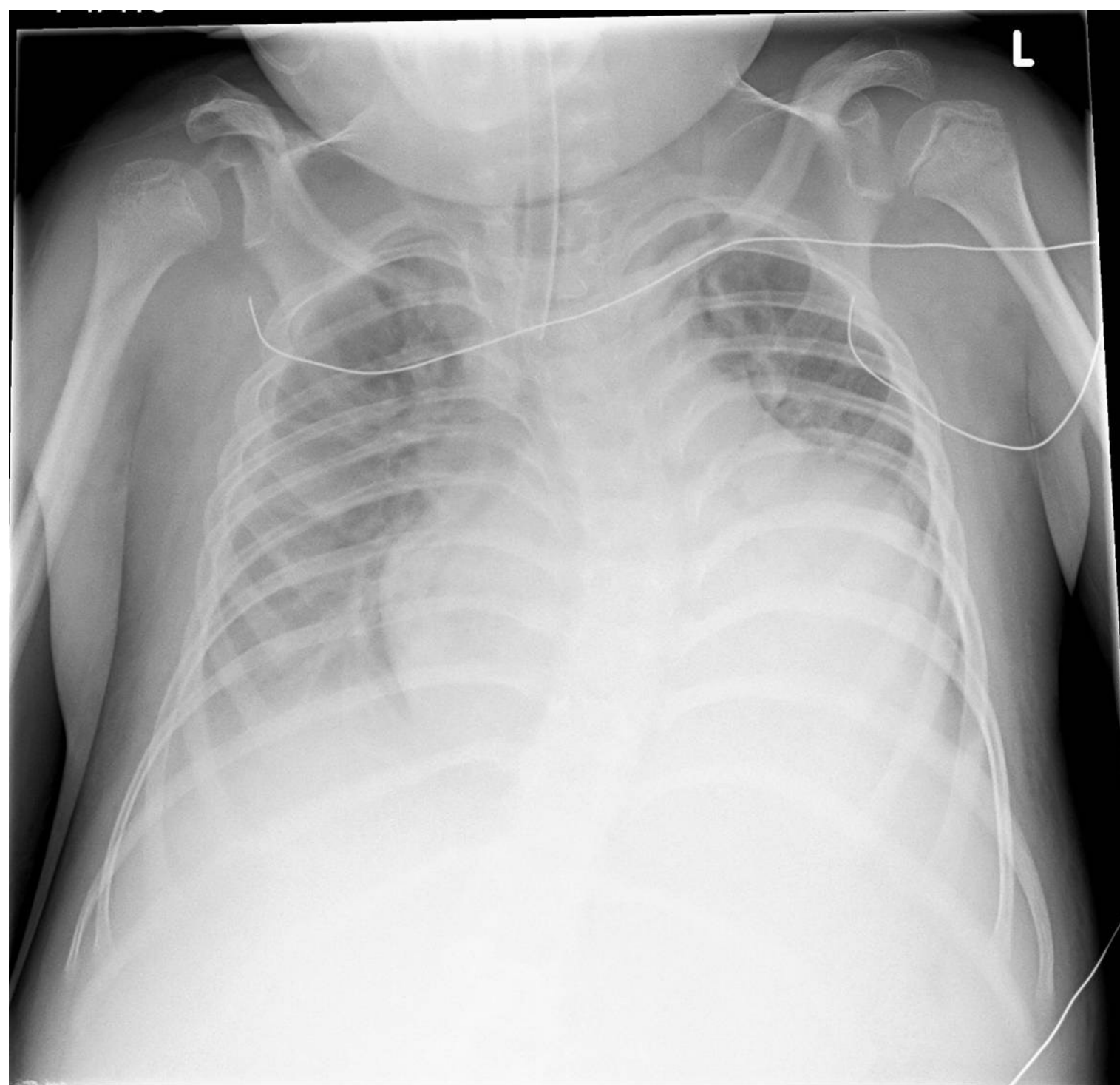
Presenting features

A 9 year old boy presented to A&E following a respiratory arrest which occurred after a prolonged period of coughing. He was hypoxic with sats of 60% despite bagging in 100% oxygen, bradycardic at 60 bpm, deeply unconscious and had a severe mixed acidosis. Initial resuscitation included: intubation and ventilation, IV access and fluid boluses, inotropes and broad spectrum antibiotics. Examination was unremarkable besides poor air entry bibasally and prominent finger clubbing.

Background

The child had an unbalanced chromosome 9 and 10 translocation with consequent severe neurodevelopmental delay. He had GORD and 1 year previously had suffered an iatrogenic oesophageal perforation leading to mediastinitis, following a dilatation procedure. Other than this previous prolonged admission, he tended to stay relatively well without recurrent admissions. Prior to this attendance, he had a 2 month history of cough with a recent deterioration, being managed with antibiotics and bronchodilators.

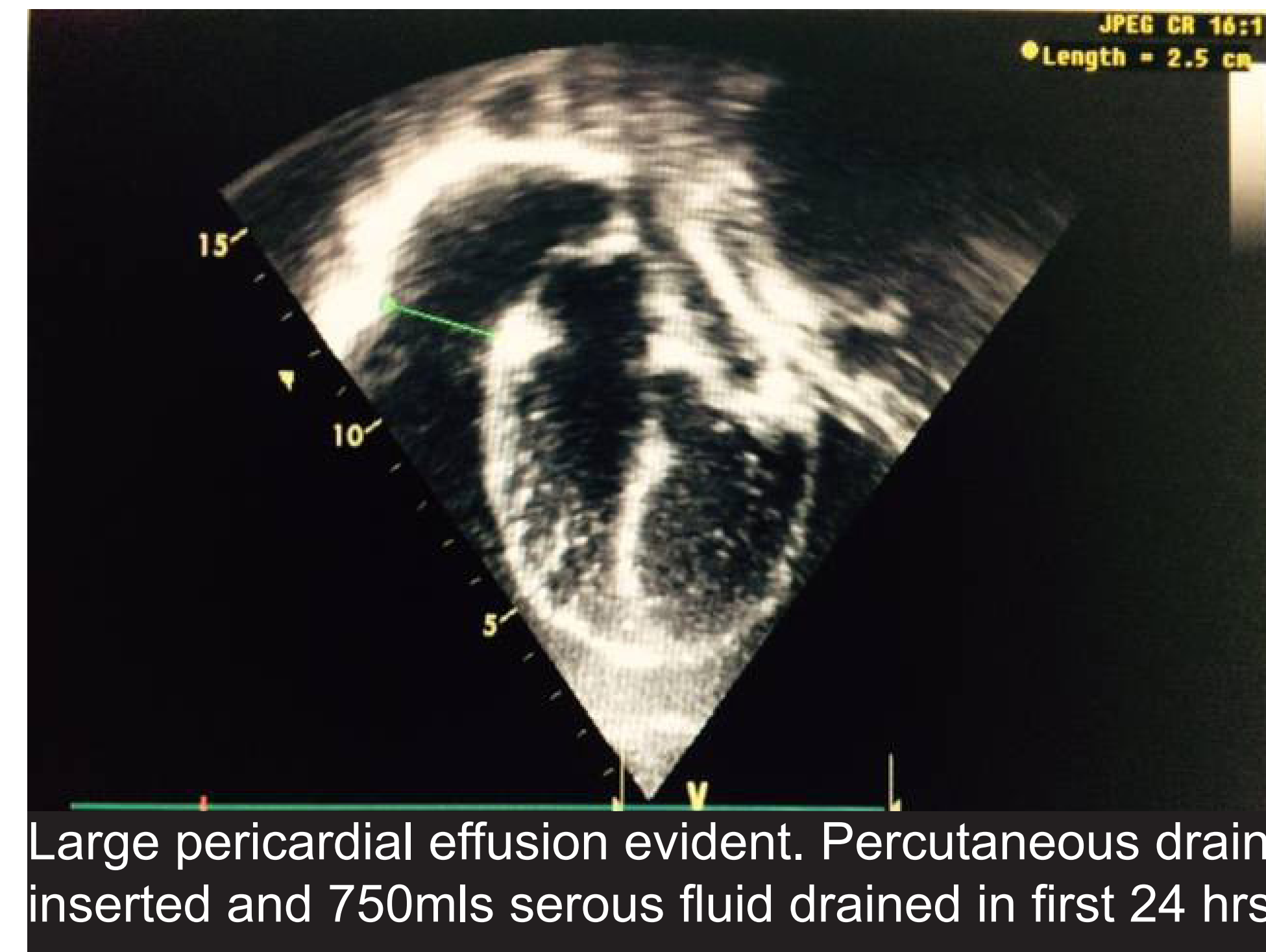
Admission CXR



Initial Progress

- Presumed diagnosis: lower respiratory tract infection
- Admission inflammatory markers only modestly elevated and other bloods normal. Rhinovirus and pseudomonas grown from ET secretions.
- Gradual weaning of ventilation possible with frequent chest physio and antibiotics
- Cardiovascularly stable, inotropes weaned and stopped
- **Deterioration day 4, increased ventilation requirements and progression of CXR changes leading to chest USS / echocardiogram**

Echo



Differential diagnosis of pericardial effusion

- Post intervention eg cardiac surgery or line insertion
- Malignant
- Bacterial
- Viral
- Rheumatological / Inflammatory
- Renal disease eg nephrotic syndrome
- 'Idiopathic'
- **Hypothyroidism**

Patient features / results

- No history of surgery or neck lines. Thought unlikely to be a recurrence of mediastinitis as clinically too well, low inflammatory markers and no fibrinous strands seen on echo.
- Pericardial fluid acellular
- Pericardial fluid negative on culture.
- Rhinovirus detected but not associated with pericardial effusions. Extensive viral PCR from several body sites and serology all negative
- Joint and soft tissue examination normal. Autoantibody screen negative. Ferritin elevated in context of acute illness.
- No history to suggest this, normal renal function, normal urine output without proteinuria and not overtly oedematous clinically.
- Diagnosis of exclusion
- **TSH > 100 mU/L, FT4 < 5 pmol/L, anti-thyroid peroxidase antibodies > 1000 U/ml. CK elevated.**

In retrospect, there were several clues in the history and presenting features which may have led to an earlier diagnosis. These included parental reporting of worsening dry skin, the need for higher doses of laxatives than previously, cool hands and feet and a possible increase in somnolence. In addition, during this acute admission, the child was always relatively bradycardic and cool, even when presenting extremely unwell with apparent infection. There was a fullness of his neck veins and an under recognition of his cardiomegaly on CXR. There was no other explanation for his finger clubbing which may be associated with severe autoimmune thyroid disease.

The child was commenced on low dose levothyroxine, titrated gradually to response. His pericardial drain was removed after 8 days and he was discharged from PICU after 14 days. He is currently doing well and remains under outpatient endocrine and cardiology follow-up.

Conclusions

Pericardial effusion is a long recognised and common complication of hypothyroidism, with an incidence of 30-70% in patients newly diagnosed and referred to the endocrine clinic. They are generally small and well tolerated. The fluid accumulates slowly, and has a high protein content secondary to capillary dysfunction and poor lymphatic tone leading to increased albumin leak into the interstitium. Conversely, in children presenting unwell with clinically significant pericardial effusions, hypothyroidism as the underlying diagnosis is exceedingly rare.

We presume, due to the large size of this child's effusion, that he had been suffering from hypothyroidism for some time. It is very likely that his underlying neurodisability masked many of his symptoms and we suggest that clinicians should have a low threshold to check TFTs in children with complex co-morbidity in response to subtle concerns.

References:

Kuhn B, Peters J, Marx GR et al. Etiology, management, and outcome of pediatric pericardial effusions. *Pediatric Cardiology*. 2008; 29: 90-94
 Levy PY, Corey R, Berger P et al. Etiologic diagnosis of 204 pericardial effusions. *Medicine*. 2003;82:385-391
 Kabadi UM, Kumar SP. Pericardial effusion in primary hypothyroidism. *American Heart Journal*. 1990; 120(6): 1393-1395
 Farooki ZQ, Hoffman WH, Perry BL et al. Myocardial dysfunction in hypothyroid children. *American Journal of Diseases of Children*. 1983; 137(1): 65-68
 Hayford JT, Schieken RM, Thompson RG. Cardiac function in primary hypothyroidism. *American Journal of Diseases of Children*. 1980; 134(6): 556-559
 Werder EA, Torresani T, Navratil F et al. Pericardial effusion as a sign of acquired hypothyroidism in children with Down syndrome. *European Journal of Paediatrics*. 1993; 152(5): 397-398
 Srinath S, Newfield RS. A child with pericardial effusion and cardiac tamponade due to previously unrecognized hypothyroidism. *Journal of the National Medical Association*. 2007; 99(12): 1411-1413
 Dinleyici EC, Ucar B, Kilic Z et al. Pericardial effusion due to hypothyroidism in Down syndrome: report of four cases. *NeuroEndocrinology Letters*. 2007; 28(2):141-144