

# CLINICAL CASE OF GIANT PHEOCHROMOCYTOMA WITH LOW HORMONAL ACTIVITY

Volkova N.I., Porksheyan M.I., Kanaeva S.A., Davidenko I.U

Rostov State Medical University, Rostov-on-Don

Rostov-on-Don, Russian Federation, dim3.rostgmu@gmail.com

## Background

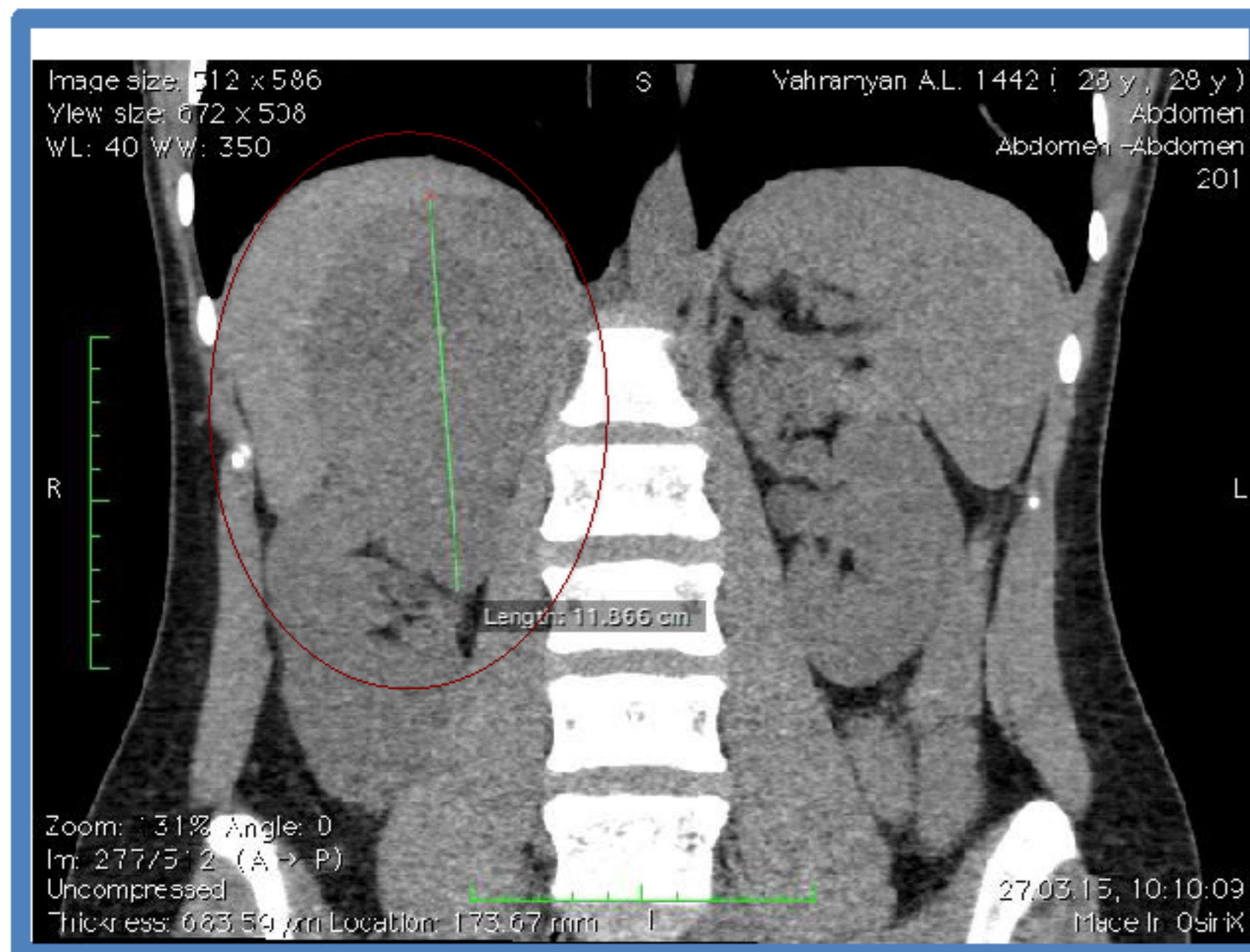
Pheochromocytoma (Ph) is the tumor that is fatal if do not suspect and treat it on time. It is supposed that size of tumor is correlated with its synthetic activity.

## Clinical case

Young woman, 28 y.o., presented with the adrenal incidentaloma. She had no complaints, her history was not notable for any disease.

### Examination. Step 1 - Visual examination - (in order to determine nature of incidentaloma)

#### Adrenal CT




«.. right adrenal heterogeneous mass **9x8x7,6cm** with native density – 30-69HU, which eclipsed liver and was inseparable from the inferior vena cava.»

Facts saying in favor of adrenocortical cancer:

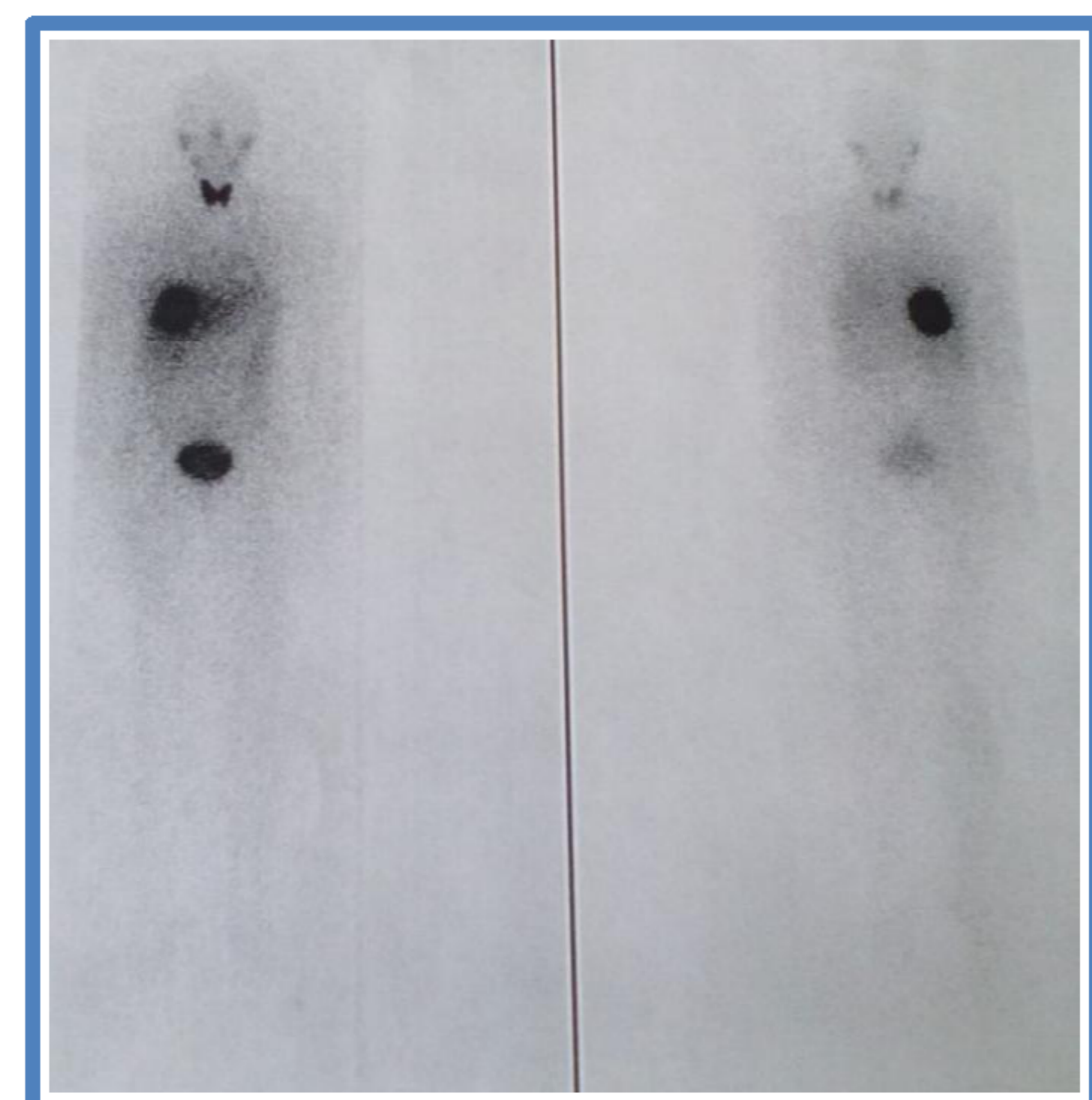
- young age
- lesion size
- parameters of native density

### Examination. Step 2 – Hormonal test according to current protocols

Parameter	Value	Reference range
plasma cortisol after 1-mg DST	45 nmol/l	< 50 nmol/l
urinary fractionated metanephrines (M)	248 mcg/24-hour	< 320 mcg/24-hour
urinary fractionated normetanephrines (NM)	2453,0 mcg/24-hour	< 390 mcg/24-hour



### Examination. Step 3 - MIBG-scintigraphy (to exclude concurrent Ph and cortical carcinoma)



signs of hormonal activity of right adrenal tumor.

## Definitive diagnosis: Pheochromocytoma of right adrenal gland

She was preoperatively given alpha-blocker for 14 days. Right laparoscopic adrenalectomy was performed without any complications. Histologic picture proved that there was **pheochromocytoma**.

## Conclusions

The size of Ph doesn't always correlate with its hormonal activity. At the same time, strict adherence to protocols is necessary in all cases despite the fact that sometimes we can see "obvious" signs of the other disease such as adrenocortical cancer in the above case.

Postoperatively	
urinary fractionated M	203 mcg/24-hour
urinary fractionated NM	154 mcg/24-hour

