

Pneumomediastinum in diabetic ketoacidosis: an ominous sign?

Aditi Sharma¹, Maria Chicco¹, Nicholas Oliver¹

¹Department of Endocrinology, St. Mary's Hospital, Imperial College Healthcare NHS Trust.

INTRODUCTION

- Spontaneous or primary pneumomediastinum (SP) occurs as a consequence of an acute increase in intra-alveolar pressure leading to alveolar rupture.
- SP is a benign condition, which promptly resolves with conservative management.
- Limited awareness about this condition may lead to an initial misdiagnosis of secondary pneumomediastinum due to spontaneous oesophageal perforation, resulting in unnecessary investigations and treatment.
- Spontaneous oesophageal perforation (SOP) is associated with high mortality and often requires invasive management.
- Here we describe the case of a young patient admitted with diabetic ketoacidosis and an incidental finding of pneumomediastinum on chest radiograph.

CASE DESCRIPTION

- A 22-year-old man presented to ED with a 3-day history of nausea, vomiting and malaise. He had no past medical history of note.
- He reported feeling thirsty, having to pass large amounts of urine and also complained of reduced appetite on a background of a 4-week history of weight loss.
- He appeared pale and clammy.
- Observations: Blood pressure 132/64 mmHg, heart rate 105 beats per minute, respiratory rate 26 breaths per minute, oxygen saturations 98% on room air.
- Chest was clear on auscultation and abdomen soft with mild generalised tenderness.
- **A venous blood gas revealed pH 6.94, base excess -29mmol/L, bicarbonate 3.2mmol/L, glucose 27mmol/L and potassium 4.7mmol/L.**
- Urine was strongly positive for ketones, and **the capillary blood ketone concentration was 4.9mmol/L.**
- **Diabetic ketoacidosis was diagnosed, most likely secondary to undiagnosed type 1 diabetes consistent with the short duration of osmotic symptoms.**
- Intravenous fluid resuscitation and fixed-rate insulin infusion were administered in line with local guidance.

Case Progress and Outcome

- On-call radiologist alerted the medical team to the presence, on the admission chest X-ray (CXR), of subcutaneous emphysema and small-volume bilateral pneumomediastinum (**Figure 1**).
- Vomiting with subcutaneous emphysema and pneumomediastinum immediately raised the suspicion of SOP.
- An urgent computed tomography (CT) scan of neck and thorax confirmed the CXR findings.
- An obvious defect in the oesophagus could not be identified, but the patient was started on intravenous antibiotics and high-dose pantoprazole and was transferred to a tertiary centre for gastro-oesophageal surgical review.
- He was scheduled to undergo urgent nasojejunal feeding tube insertion.
- However, a repeat CT scan of neck and thorax with water-soluble oral contrast did not demonstrate the presence of contrast extravasation or pleural effusion.
- **The surgical and diabetes teams jointly managed the patient conservatively:** he remained nil by mouth and a water-soluble contrast swallow was obtained on day 5 after admission.
- The swallow was unremarkable and oral intake was progressively increased.
- He was discharged 6 days after initial presentation, with outpatient follow-up in diabetes clinic.

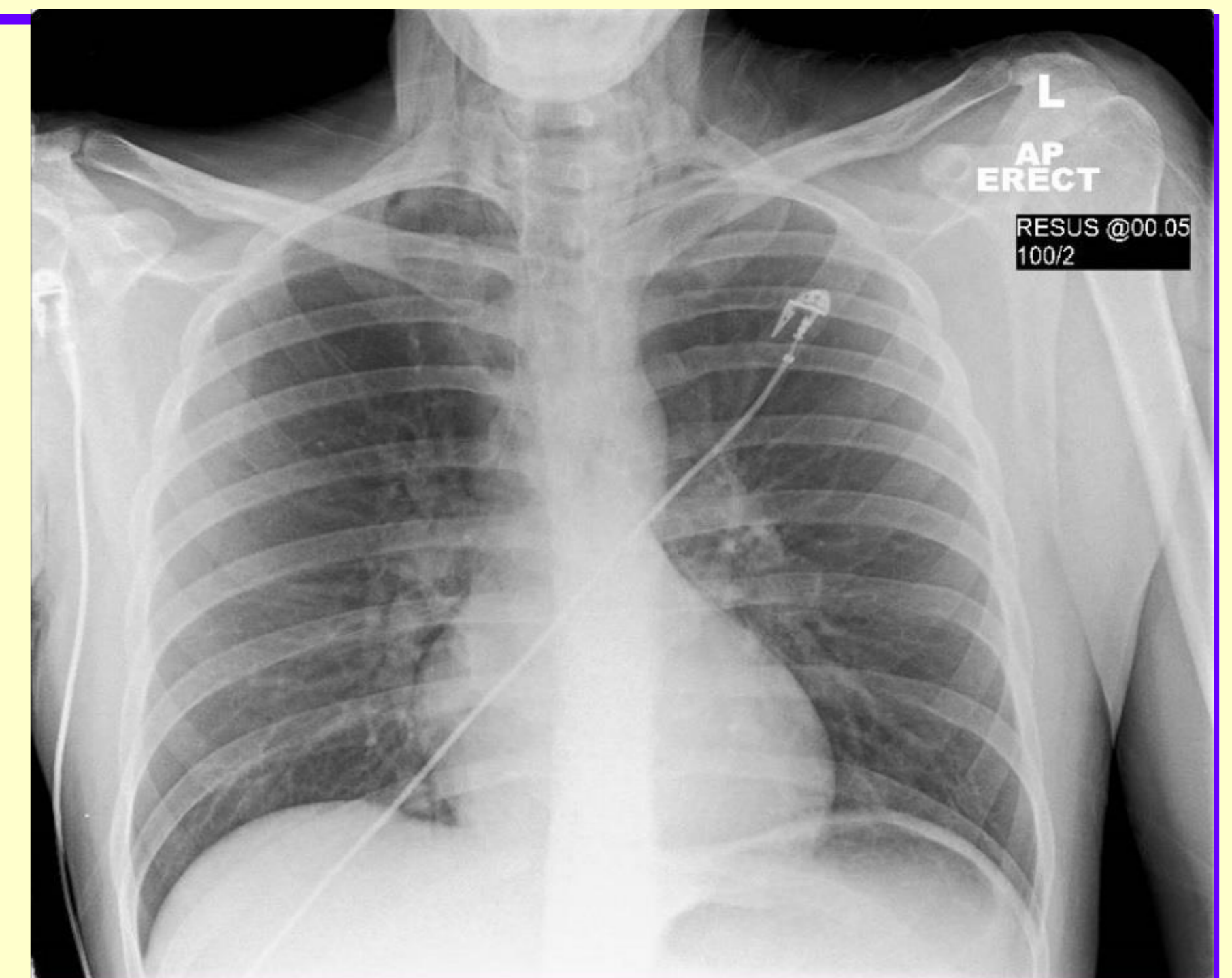


Figure 1: CXR on admission

DISCUSSION

- Cases of SP have been described in diabetic ketoacidosis; alveolar rupture occurs secondary to a combination of vomiting, compensatory tachypnoea and increased depth of breathing.
- Pneumomediastinum is a rare radiological finding and vomiting-induced pneumomediastinum often evokes an initial diagnosis of SOP.
- SOP is a severe condition, which can cause secondary pneumomediastinum and precipitate life-threatening mediastinitis, requiring emergency treatment, often in the form of surgery.
- CT of the thorax with water-soluble oral contrast is a non-invasive investigation, which can assist in differentiating between SP and SOP.

SUMMARY

- SP is a benign condition, which may mimic secondary pneumomediastinum caused by SOP.
- These two conditions can be distinguished on the basis of clinical and radiological findings.
- However, in the presence of diabetic ketoacidosis, clinical findings can be misleading suggesting that awareness about SP is even more important in this context.
- SP does not appear as a complication in the Joint British Diabetes Societies (JBDS) diabetic ketoacidosis guidelines; inclusion may improve awareness about this condition and enable early diagnosis and conservative management.

References

1. Murayama S & Gibo S. Spontaneous pneumomediastinum and Macklin effect: overview and appearance on computed tomography. *World J Radiol* 2014; 6: 850-4.
2. Hamman L. Spontaneous mediastinal emphysema. *Bull Johns Hopkins Hosp* 1939; 64: 1-21.
3. Pooyan P, Puruckharr M, Summers JA, Byrd RP Jr & Roy TM. Pneumomediastinum, pneumopericardium, and epidural pneumatosis in DKA. *J Diabetes Complications* 2004; 18: 242-7.
4. Foreshaw MJ, Khan AZ, Strauss DC, Botha AJ & Mason RC. Vomiting-induced pneumomediastinum and subcutaneous emphysema does not always indicate Boerhaave's syndrome: report of six cases. *Surg Today* 2007; 37: 888-892.
5. Pauw RG, van der Werf TS, van Dulleman HM & Dullaart RPF. Mediastinal emphysema complicating diabetic ketoacidosis: plea for conservative diagnostic approach. *Neth J Med* 2007; 65: 368-371.