

### INTRODUCTION

Although neuroendocrine tumours (NET) constitute a very heterogeneous group, most of them express somatostatin receptors that enable treatment with somatostatin analogues, which proved to be effective both as bio- or radiopeptide therapy. However, little is now about combining this two treatment modalities.

The aim of our prospective study was to evaluate results of radiolabeled somatostatin analogues treatment (PRRT) with or without long lasting "cold" somatostatin analogues (SA) as consolidation treatment.

### METHODS

The study was opened to patients with histopathologically confirmed well differentiated neuroendocrine tumours. All patients were treated with PRRT (4 to 5 cycles repeated every 6 to 12 weeks). After the last cycle of PRRT treatment response was evaluated with scintigraphic, radiological and biochemical examination. Thereafter patients were randomly assigned either to treatment with somatostatin analogues or observation group (2:1 randomisation). Initiation of next line of therapy was left to discretion of treating physician.

Patients were followed-up at 4-12 months intervals with radiological examinations (CT or MRI) and receptors scintigraphy. Median time to progression was measured from the start of PRRT treatment till the day of disease progression confirmed in radiological or scintigraphic examination.

### RESULTS

One hundred twenty five with well differentiated neuroendocrine tumours were included. At the time of randomisation none of the patient suffered from carcinoid syndrome.

| Characteristic                                 |                   |
|--|-------------------|
| Gender (female/male)                           | 110/125           |
| Age at diagnosis (median)                      | 53 years (18-77)  |
| Time from diagnosis to PRRT treatment (median) | 14 months (2-176) |
| Previous systematic therapy*                   |                   |
| Chemotherapy                                   | 18                |
| Somatostatin analogues                         | 16                |
| <sup>131</sup> I-MIBG                          | 4                 |

\*some patients were treated with more than one treatment modality

Fig 1. Localisation of primary tumour

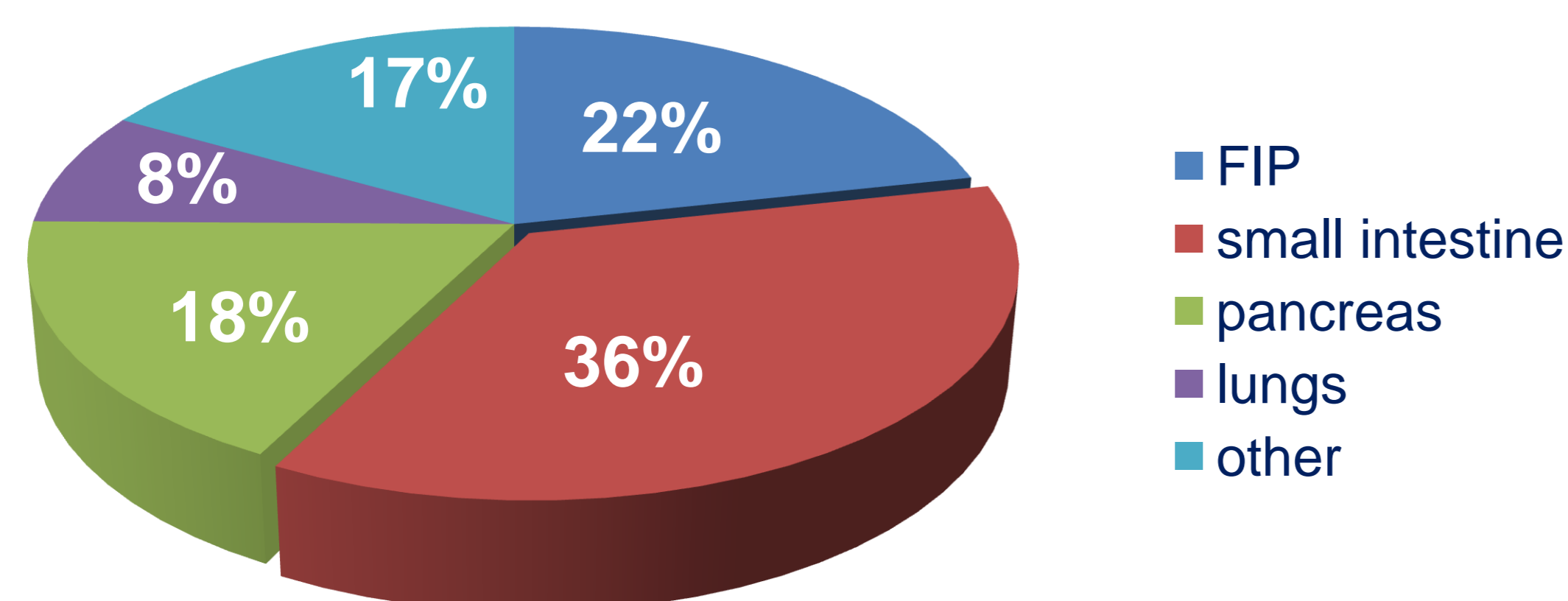
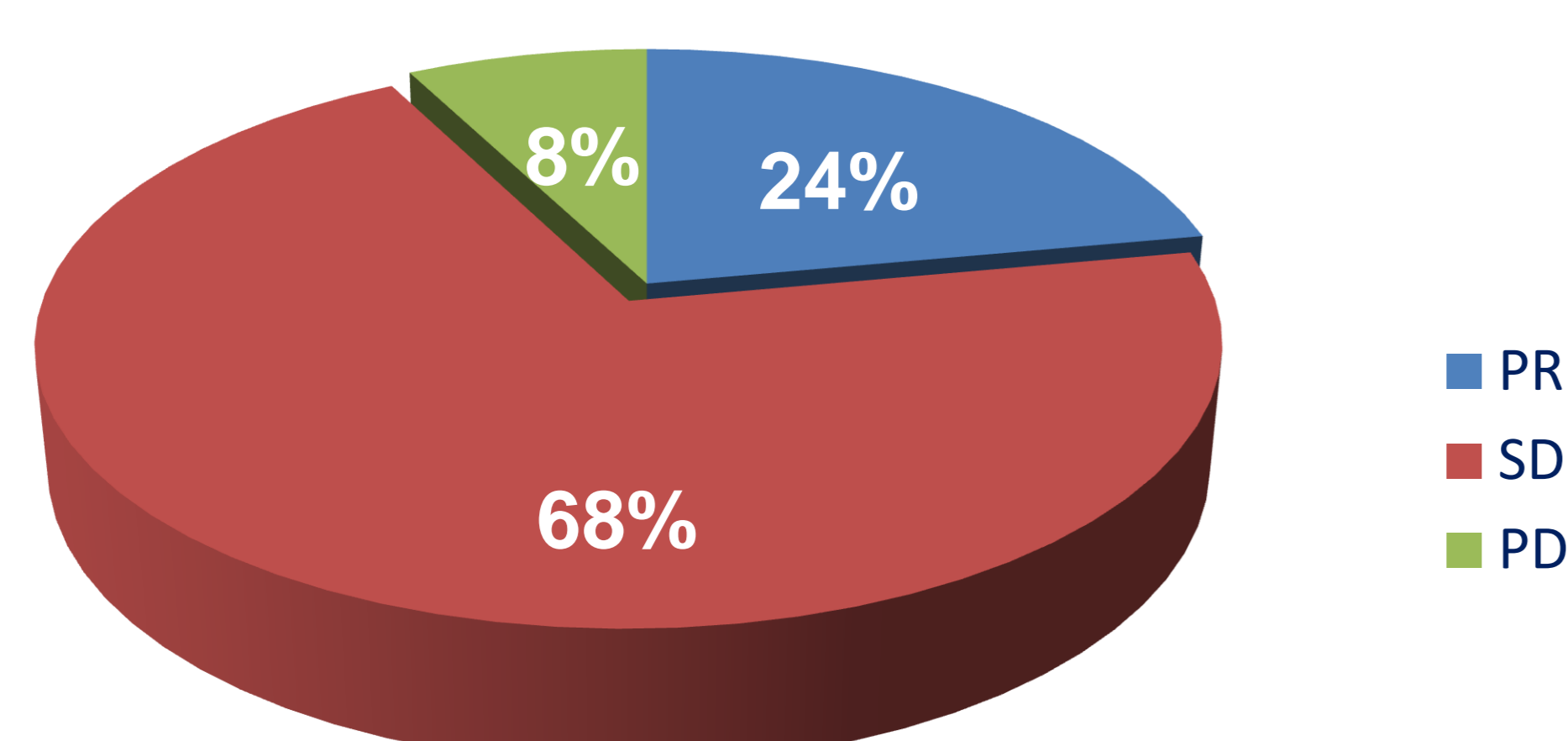


Fig 2. Results of PRRT according to RECIST criteria



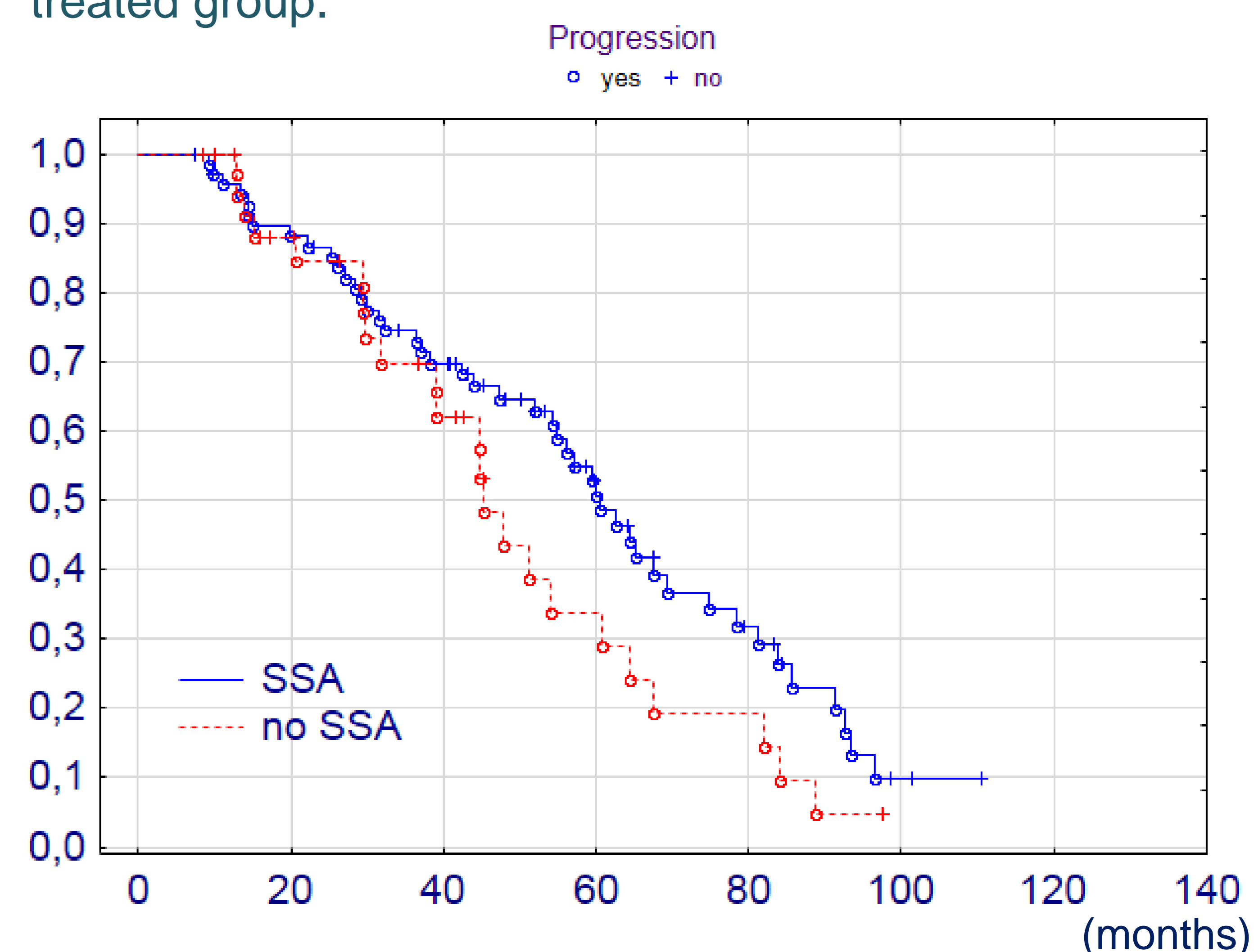
After completion of radiolabelled somatostatin analogues therapy 81 patients were randomly assigned to somatostatin analogues and 44 to observation group.

### Time to disease progression

The median follow-up calculated from the start of PRRT was 44 months for the whole group of patients. During that time 81 (65%) progressed.

There was a trend to longer progression free survival in SSA group, however, the difference was statistically insignificant (fig.3).

Fig 2. Progression free survival in SSA treated and non-treated group.



### CONCLUSIONS

Preliminary results suggest that consolidation treatment with SA did not improve results of PRRT. However, larger number of patients and longer follow-up is necessary.