

Clinically Non-Functioning Pituitary Macroadenomas: Presenting Features and Outcomes – Recent Experience at a Tertiary Centre

Mahender Yadagiri¹, Arun Vijay¹, Mark Pritchard¹, Ananth Nayak¹, Simon Shaw², Natarajan Saravanappa³, John Ayuk¹, Biju Jose¹

Depts. of Diabetes & Endocrinology¹, Neurosurgery², ENT³
Royal Stoke University Hospital, Stoke-on-Trent, UK

Introduction

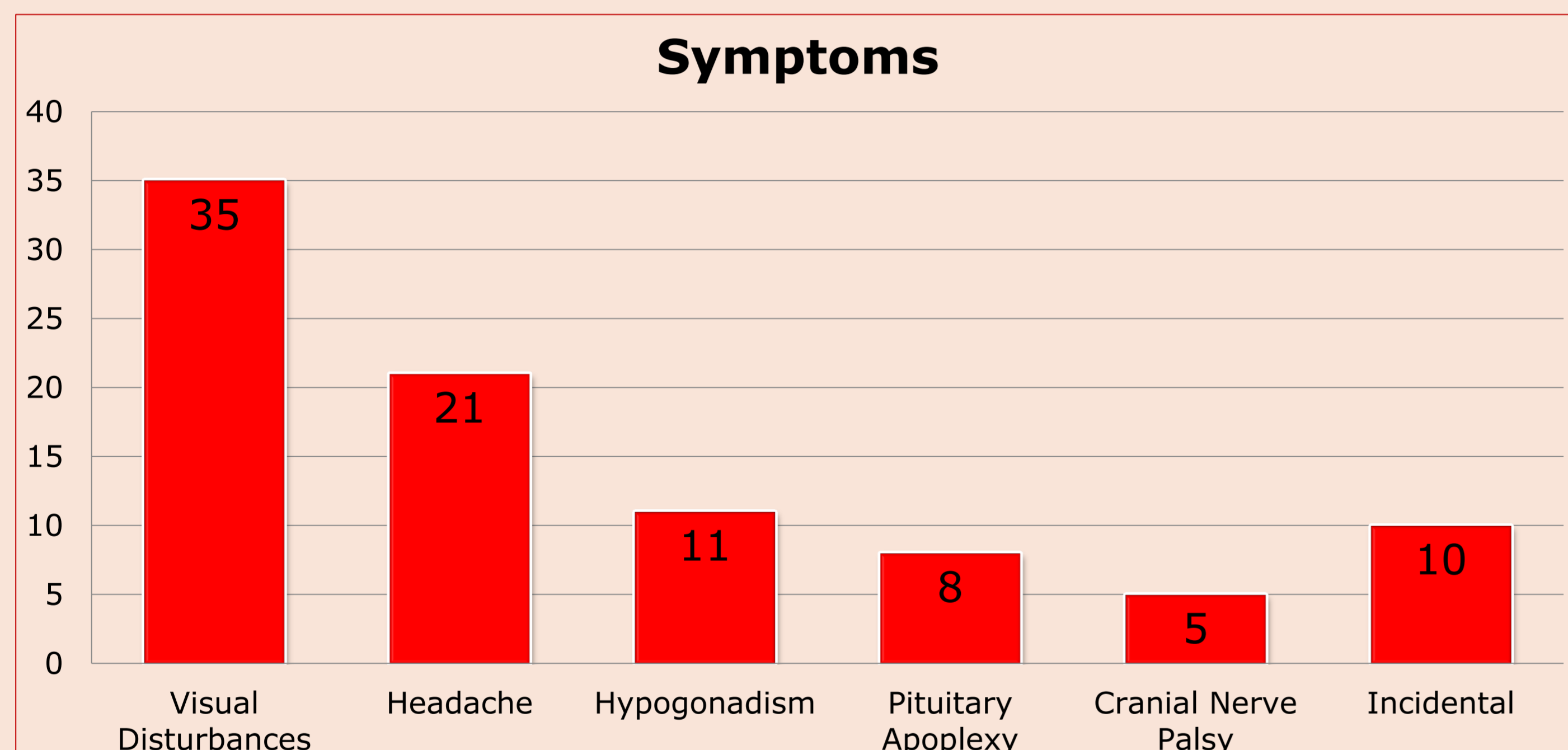
Non-functioning pituitary macroadenoma (NFMA) can cause considerable morbidity due to pituitary dysfunction and pressure effects. Prevalence of pituitary adenoma is 80–100 cases per 100,000 of the population; of these NFMA accounts for 15–30%. Annual incidence is one per 100,000 of population^{1 2}

We present recent experience in managing NFMA at a single tertiary centre between January 2009 and Oct 2013.

Results

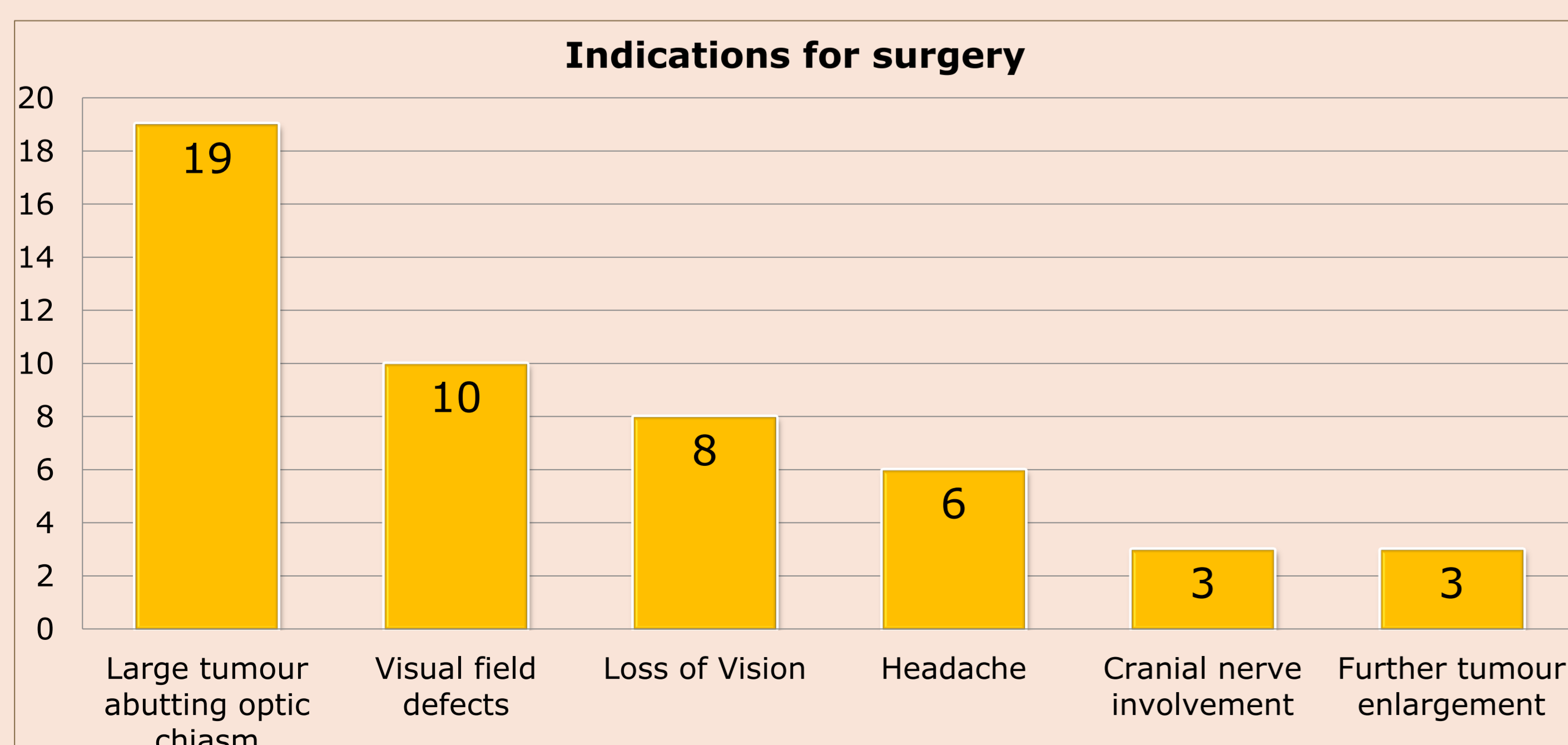
Of the 63 patients with NFMA, 28 (44%) were females. Age ranged from 22 to 91 (mean-63).

The commonest presentations are shown below .



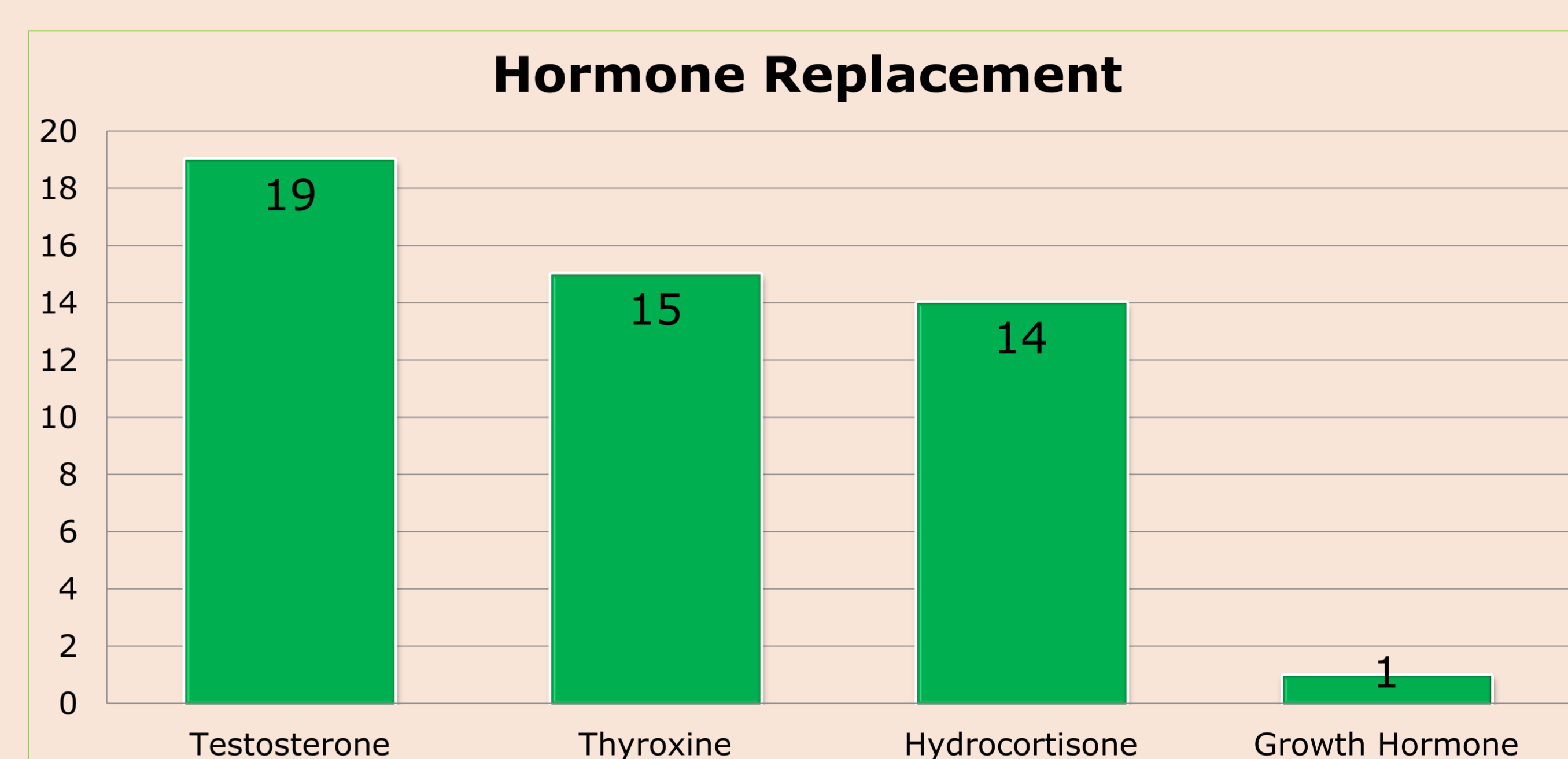
Prolactin levels ranged from 25 to 2536 mU/l (mean-394). Six patients (10%) were found hypothyroid at presentation. Pituitary MRI scan showed elevation or compression of optic chiasm in 55 patients (87%).

49 (78%) underwent endoscopic trans-sphenoidal hypophysectomy. Three patients (5%) required surgery for further tumour enlargement during follow-up.



Post-operative complications included transient diabetes insipidus (5/49; 10%), CSF leak (2/29; 4%) and haemorrhage (1/49; 2%).

Post-operatively, hormone replacement was required as shown below.



Patients with apoplexy had emergency surgery (n=2), elective surgery (n=4) and conservative management (n=2). Five patients had improved vision following surgery, while one patient undergoing surgery after a year had no visual recovery.

Conclusions

NFMAs represent the bulk of patients presenting with a pituitary tumour. The clinical presentation can vary widely from asymptomatic incidental finding to catastrophic pituitary apoplexy as seen in this series.

Majority of NFMAs require surgery. A select subset can be managed conservatively. However these patients require long-term follow-up to monitor for tumour growth.

Appropriate and timely surgery can be crucial in patients presenting with apoplexy and should be considered in those with neuro-ophthalmic signs.

Post-operative hormone replacement is required in significant proportion of patients.

References

1. Raappana A et al- Incidence of pituitary adenomas in Northern Finland in 1992–2007. J Clin Endocrinol Metab 2010;95(9):4268–75
2. Fernandez A, Karavitaki N, Wass JA. Prevalence of pituitary adenomas: a community-based, cross-sectional study in Banbury (Oxfordshire, UK). Clin Endocrinol (Oxf) 2010;72(3):377–82.